

**INGUINAL SURGERY  
AND MALE INFERTILITY**



**DAVINDER PAL SINGH SANDHU**

**Submitted as a thesis for the degree of Doctor of Medicine  
(MD) to the University of Leicester**

**August 1993**

UMI Number: U555199

All rights reserved

INFORMATION TO ALL USERS

The quality of this reproduction is dependent upon the quality of the copy submitted.

In the unlikely event that the author did not send a complete manuscript and there are missing pages, these will be noted. Also, if material had to be removed, a note will indicate the deletion.



UMI U555199

Published by ProQuest LLC 2015. Copyright in the Dissertation held by the Author.  
Microform Edition © ProQuest LLC.

All rights reserved. This work is protected against  
unauthorized copying under Title 17, United States Code.

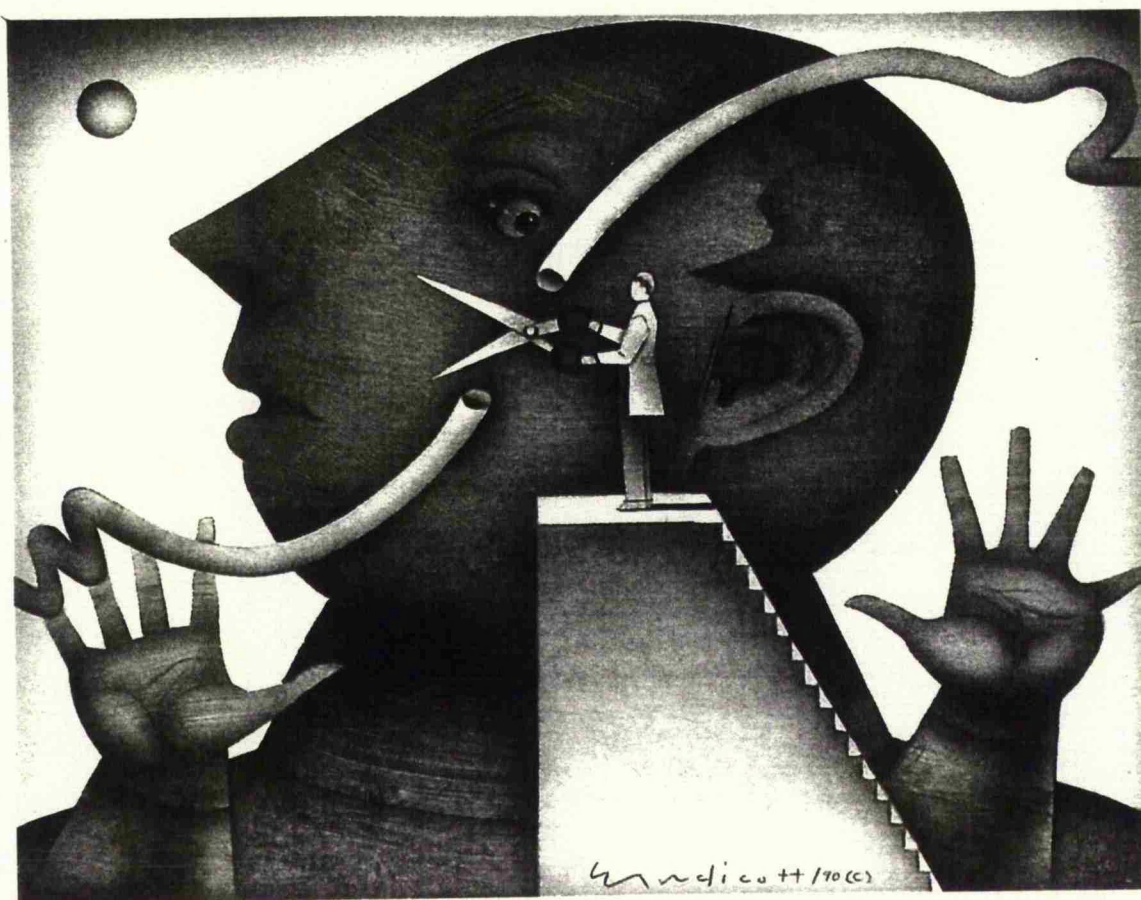


ProQuest LLC  
789 East Eisenhower Parkway  
P.O. Box 1346  
Ann Arbor, MI 48106-1346





7502093068



**Any urologist can tell you that between having kids  
and not having kids there is a vas deferens**

## Acknowledgements

This thesis developed as a consequence of observations and clinical interest of Mr D E Osborn (Consultant Urologist, Leicester General Hospital) into the tragic problem of vas damage and inguinal surgery, in patients with obstructive azoospermia. I am deeply indebted to Mr D E Osborn and Professor P R F Bell (Professor of Surgery, Leicester Royal Infirmary) for their help, encouragement and supervision of this project. The experimental work of this thesis, was performed during my clinical posts of Urology Registrar at Leicester General Hospital and University Hospital of South Manchester.

I am particularly grateful to Professor D B Morton (Director) and the animal technicians at the Biomedical Unit, Leicester University, for the development of the Wistar rat model and post-operative care of the animals. Dr. E H Mackay (Consultant Pathologist), Leicester General Hospital, was kind enough to supervise me during the histological studies of the vas deferens and testes.

I am thankful to the Department of Physiology, Leicester University especially Professor A G H Blakeley (Professor of Physiology, Leicester University) for allowing me to undertake the vas deferens contractility experiments, Dr S A Petersen (Lecturer in Physiology, Leicester University) for introducing me to this technique, supervision and help in interpreting the results, and Dr J E Brockbank for his initial help with the experiments.

I wish to extend my gratitude to Dr J S Dixon (Senior Lecturer, Manchester University) and his Staff at the Department of Cell Structure and Function, Manchester University, for undertaking the autonomic and peptidergic innervation immuno-histological staining of the vas deferens.

In addition, I would like to acknowledge the help given to me by the following people, Professor N J Blacklock, Mr N J R George and Mr E W Lupton (Consultant Urologists, University Hospital of South Manchester) for their encouragement while I was their Registrar. I am also grateful to my former Consultants, Mr C P Bates and Mr M C Bishop (Consultant Urologists, City Hospital, Nottingham) for their guidance in the preparation and presentation of this thesis. My special thanks are due to Mr D Thomas (Consultant General Surgeon) for allowing access to his computer and printing facilities at the Derbyshire Royal Infirmary. Finally I wish to thank my wife Punam for her patience and support, and our sons Jai and Hira who were oblivious to it all.

### Statement of Originality

The work of this thesis examines an aspect of vas damage from inguinal surgery which has not, to my knowledge, been previously studied experimentally. Although the examination of vas deferens contractility, its autonomic and peptidergic innervation in other animals is well established in physio-pharmacological studies, the application of such techniques to examine the effect of vas damage and correlation with fertility status, autonomic and peptidergic innervation and contractility, has to my knowledge not been reported before. All the experiments were performed by myself. I personally carried out all the fertility studies, post mortem dissections, vasograms, histological analysis and contractility experiments. The special immuno-histological stains for the peptidergic and autonomic innervation and electron microscopy were kindly undertaken by the staff at the Department of Cell Structure and Function, Manchester University under the supervision of Dr. J S Dixon.

## **CONTENTS**

	<b>Page No</b>
<b>Title page</b>	<b>1</b>
<b>Acknowledgements</b>	<b>3</b>
<b>Statement of Originality</b>	<b>5</b>
<b>List of Contents</b>	<b>6</b>
<b>List of Tables</b>	<b>9</b>
<b>List of Figures</b>	<b>11</b>
<b>Introduction</b>	<b>16</b>
<b>Section 1    Review of the literature</b>	<b>17</b>
<b>1.    Historical perspective of the problem</b>	<b>18</b>
<b>2.    The clinical problem</b>	<b>21</b>
<b>3.    The embryological development of the vas deferens       and associated male reproductive tract</b>	<b>24</b>
<b>4.    The anatomy of the male reproductive tract</b>	<b>28</b>
<b>5.    Composition of fluid transported by the vas deferens</b>	<b>35</b>

6. The autonomic innervation of the vas deferens	39
7. The peptidergic innervation of the vas deferens	44
8. Neurotransmission and neuroreceptors	47
9. Physiology of vas deferens contraction	57
10. Vas deferens contractility and sperm transport	74
11. The immunological consequences of vas damage	84
12. Obstructive lesions of the male genital tract	92
<b>Section 2 Experimental Study</b>	<b>105</b>
13. The development of the Wistar rat model	107
14. The effect of surgical technique on the immature vas deferens	126
15. The effect of surgical technique on the mature vas deferens	141
16. The effect of surgical technique on the autonomic and peptidergic innervation of the vas deferens	149

17. The effect of surgical technique on the contractile properties of the vas deferens	166
Section 3	187
18. Clinical cases	188
19. General discussion	
20. Conclusion	192
Section 4	199
21. Appendix	203
Section 5	224
22. References	225
Section 6	275
23. List of publications and presentations based on this study	276



## List of Tables

Table No	Title	Page No
12.1	Classification of azoospermia	93
12.2	General conditions associated with azoospermia	94
12.3	Clinical classification of azoospermia with normal serum FSH	95
14.1	Details of operative procedure with the immature vas deferens	131
14.2	Summary of fertility data and testis weight	132
15.1	Details of operative procedures with the mature vas deferens	146
15.2	Results of adult fertility trial	147
15.3	Reason for sterility in adult trial	148
16.1	Operative procedures on vasa used for autonomic and peptidergic innervation	155
17.1	Fertility status of vasa used for autonomic and peptidergic innervation	172

Table No	Title	Page No
17.2	Composition of Krebs solution	173
17.3	Results of vasography and testis histology	174
17.4	Results of vas deferens isometric contraction in grams tension	175

## List of Figures

Figure No	Title	Page No
1.1	Derbyshire well dressing ceremony	19
4.1	Anatomy of the male reproductive tract	28
4.2	Section of the testis and epididymis demonstrating seminiferous tubules and formation of the vas deferens	30
4.3	Illustration of the anatomical pathway of the vas deferens	32
13.1	Anatomy of the male wistar rat	110
13.2	Description of the anaesthesia used	112
13.3	Illustration of surgical technique used	113
13.4	Vas deferens and testis delivered from the inguinal canal	114
13.5	Anatomy of the inguinal ring	115
13.6	Vasectomy being performed	116

Figure No	Title	Page No
13.7	Vas deferens stripped by sharp and blunt dissection	117
13.8	Tight inguinal repair	118
13.9	Loose inguinal repair	119
13.10	Healed scrotal wound	120
13.11	Burst wound with epididymorchitis	121
13.12	Wound disruption requiring resuturing	122
13.13	Late wound infection requiring resuturing	123
13.14	Ulceration of scrotum	124
13.15	Postoperative odema and superficial ulceration	125
14.1	Histology criteria for vas assessment	133
14.2	Histology criteria for testis assessment	133
14.3	Technique used for vasography	134
14.4	Xray of patent vasogram	135

Figure No	Title	Page No
14.5	Xray of patent vasogram	136
14.6A	Normal rat testis with active spermatogenesis	137
14.6B	Severe infarction of testis following tight inguinal repair	138
14.7A	Normal rat vas deferens	139
14.7B	Abnormal rat vas deferens that has been stripped	140
16.1	Density and distribution of the autonomic and peptidergic innervation of the vas deferens	156
16.2	Noradrenergic innervation of the rat vas deferens	157
16.3	Dense neuropeptide Y innervation of the rat vas deferens muscle	158
16.4	Neuropeptide Y innervation of the rat vas deferens	159

Figure No	Title	Page No
16.5	Acetyl cholinesterase positive nerve distribution in the vas deferens muscle	160
16.6	Vasoactive intestinal polypeptide innervation of the vas deferens	161
16.7	Comparison of the density and distribution of the autonomic and peptidergic innervation of the fertile and sterile vas deferens	162
16.8	Electron microscopy of a control rat vas deferens pseudocilia	163
16.9	Electron microscopy of neuropeptide granules in subepithelial plexus	164
16.10	Electron microscopy of neuropeptide granules in vas deferens muscle	165
17.1	Vas attached to a strain guage and suspended between platinum electrodes in Kreb's solution	176
17.2	Biphasic response of a control vas deferens to supramaximal field stimulation	177

Figure No	Title	Page No
17.3	Run of powerful biphasic contractions from control vas	178
17.4	Biphasic response of a vasectomy specimen	179
17.5	Biphasic response of a stripped vas	180
17.6	Biphasic response of a stripped vas plus loose inguinal repair	181
17.7	Biphasic response of a fertile vas with loose inguinal repair	182
17.8	Biphasic response of a vas with crush injury	183
17.9	Biphasic response of a fertile stripped vas	184
17.10	Results of peak contraction in the control and operative groups	185
17.11	Results of tonic contraction in the control and operative groups	186

## Introduction

The purpose of this thesis is to study the effect of inguinal surgery on vas deferens damage and subsequent fertility. 30% of paediatric surgical practice relates to surgical procedures in the inguinal region. Since this form of surgery is undertaken in the very young and with population movements the long term serious complication of infertility is sparsely documented. Increasing awareness of this together with the development of andrology and infertility clinics has highlighted the difficulties of the infertile male. This is particularly striking in infertility clinics where the male is the significant factor for 25% of couples. The prognosis for men with severe oligozoospermia and azoospermia is very poor, and often the only treatment possible is artificial insemination by donor. In the majority of patients there is no specific aetiology and the belief that infection is the main cause of obstructive azoospermia and male subfertility is difficult to sustain. A possible preventable cause for obstructive azoospermia and male subfertility is due to iatrogenic vas deferens damage. This can occur during operative handling of the spermatic cord during such procedures as childhood herniotomy, orchidopexy, hydrocele repair and in the younger man inguinal herniorrhaphy. This is particularly so in patients undergoing bilateral procedures. The majority of inguinal surgery is unilateral. Any vas damage therefore may be masked by a normal contralateral testis and vas deferens; however the contralateral side may be abnormal as in the case of small volume testis, absent vas, intratesticular block, previous infection, sympathetic orchioepithia etc. Previous animal studies have examined histological changes in the vas deferens but fertility trials have not been done before. This study by developing a Wistar rat model has tried to address the problem of inguinal surgery and male infertility, in particular, to determine what effect spermatic cord and especially vas deferens handling has on fertility.



## **Section 1**

### **Review of the literature**

## Chapter 1

### Historical Perspective Of The Problem

In the United Kingdom, infertility may affect one in six marriages (Jequier, 1986). Infertility is a problem of a couple and not a problem of a man or of a woman. Despite the present emphasis on low parity and on contraception, a child is still an important objective of most marriages and therefore involuntary infertility is a major cause of distress to an otherwise happily married couple.

Give me children or else I die.

Genesis, Chap. 30, Verse 1.

Rachel's eloquent plea ringing through the centuries conveys clearly today the desperate hope of the infertile couple (Hargreave 1983). It is interesting that some of the first biblical references to bodily disorders are to human infertility rather than ill health. In many societies the barren woman is condemned and childlessness may still be a conscious or unconscious reason for divorce.

The importance of fertility can be seen in the widespread existence of fertility rites. Often these rites are connected with the fertility of the land and thus symbolic, or actual intercourse may be portrayed to ensure a good harvest. The May Day celebration of bringing home the may is of this type; a Maypole is erected and festooned and young girls dance around this phallic symbol. In a similar fashion, the corn dolly made at the harvest time would be kept to promote human fertility (Hargreave 1983). Another association with fertility in the fields is Mother Goddess

symbolism (Neumann 1955). This ranges from crudely carved figures from the Palaeolithic period to images of the Mother and Child in ancient Egypt and the Virgin and Child in the Christian religion. Water has also been equated with fertility because of its power to regenerate barren land and thus wells and springs were commonly visited by infertile women. An example of this is the Derbyshire well-dressing ceremony, which is almost certainly a vestige of an ancient fertility rite (Fig 1.1).




Fig 1.1      Example of a Derbyshire well dressing ceremony.  
Jesus turning water into wine at the wedding at  
Cana.

Many ancient gods have been depicted with an erect or large phallus e.g. Hermes in Greece, Osiris in Egypt, Frey in Sweden and the Cerne Abbas Giant cut into a Dorset hillside (Jensen 1963). In India sterile women used to visit the Temples of Siva where they would press their naked bodies against the huge phallus of the god's statue. In an old Hungarian custom the childless wife was struck with a stick which had been used to part mating dogs.

Interestingly in the past it has always been the woman who has been blamed for infertility. It is always the woman who sort advice and treatment. Male fertility has been associated with sexual assertiveness, male ego and never questioned. The development of infertility clinics started in the domain of Gynaecology, and it is only in the last 25 years that full andrology and joint male and female infertility clinics have developed.

## Chapter 2

### The Clinical Problem

The vas deferens is physiologically a dynamic structure. In man, sperm are not normally stored in the seminal vesicles and hence at the time of sexual arousal a physiologically functioning, contractile, and patent vas is essential, as ejaculation is dependent on the well coordinated interaction of a patent vas, the ampulla, and the seminal vesicles (Hanley 1955). The vas can transform itself from a winding tortuous canal into a linear tube and therefore make it easier to eject its contents into the ampulla and seminal vesicles (Mitsuya et al 1960). To achieve this effectively the vas deferens has a powerful muscular tube with pseudocilia and a rich innervation of its smooth muscle and epithelium. It is the only human tubular structure that has a lumen with a diameter that is smaller than the thickness of its wall.

Previous surgery, infections, trauma, amyloidosis and other diseases have been shown to disrupt this propulsive action leading to defective ejaculation, retrograde flow, oligozoospermia and infertility (Janik and Shandling 1982).

In paediatric surgical practice 30%-35% of operations are on the inguinal region (Janik and Shandling 1982). This is usually unilateral. Any vas damage therefore may be masked by a normal contralateral testis and vas deferens. The contralateral side however may be abnormal as in the case of small testis, cryptorchidism, intratesticular block, infection, absent vasa etc. It is important therefore to know what effect inguinal surgery has on the structures of the spermatic cord and especially the vas deferens. Inadvertent transection of the vas deferens has obvious life long sequelae, however other operative manipulations of the vas have an unpredictable

and generally undocumented effects on fertility. This is invariably because of the prolonged interval before presentation, and the multifactorial aspect of fertility.

Cases of obstructive azoospermia secondary to surgery especially childhood herniotomy have been intermittently reported.

Young (1951) and Hanley (1955) described 5 and 3 cases respectively of obstructive azoospermia following bilateral hernia repair in infancy. Sparkman (1962 ) recorded an incidence of 1.6% for the inadvertant removal of a segment of the vas deferens with the hernia sac. Friberg (1979 ) on investigating 76 men with sperm-agglutinating antibodies found 12 (16%) had herniorrhaphy performed and were sterile. Ten of these patients were explored and 5 of these had vas deferens obstruction consistently in the area of previous surgery. Jequier ( 1985 ) in a series of 102 patients with obstructive azoospermia described an incidence of 9.8% (10\102 ) who gave a history of trauma and previous surgery. Five of these patients had a unilateral herniotomy, however only 2 patients with previous surgery, and 1 with trauma had definite vasal obstruction on exploration. The other 3 cases had a patent vas, with a normal testis and yet had azoospermia. There may be therefore more subtle changes to vas deferens function after surgical exploration than direct injury. More recently Petrovsky (1985) on investigating 38 adults with obstructive azoospermia, found 5 had bilateral herniotomy performed in childhood. The incidence of vas damage in unilateral herniotomy and inguinal surgery is unknown. It can only be speculated as to how many unilateral injuries occur and escape unnoticed.

In animal studies attention has been focused on the histological changes in the vas deferens (Shandling and Janik 1981; Janik and Shandling 1982). The clinical cases combined with the animal experiments hi-light the care needed during inguinal surgery. This is particularly so in patients

undergoing bilateral procedures. Clearly for unilateral operations any vas deferens damage may be masked by the contralateral side, assuming that there is a normally functioning testis and vas unit. In addition, although the vas deferens may be intact following surgery, difficulties with sperm transport may lead to male subfertility and even the tragedy of iatrogenic azoospermia.

## Chapter 3

### The Embryological Development Of The Vas Deferens And Associated Male Reproductive Tract

Bilateral vasa aplasia has been found in 2% - 20% of infertile patients (Dubin & Amelar, 1971; Pryor et al, 1978c). Unilateral absence of the vas occurs in 0.5% - 1% of the male population and so the embryology of the vas deferens must be considered. Hendry (1988) reported in some patients with unilateral absence of the vas there were associated problems on the contralateral side, such as testicular atrophy, post-infective blocks, or other congenital anomalies. Congenital lesions of the ejaculatory duct and ampulla are also potentially important.

The urogenital system can be divided functionally into the urinary system (excretory system) and the genital system (reproductive system). Embryologically and anatomically, the systems are closely associated, as demonstrated in the adult male, by the urethra which conveys both urine and semen.

The development of the male urogenital system is caused by action of androgenic foetal hormones produced by the foetal testes. They take effect at the end of the second month as seen by regression of the paramesonephric (Mullerian) structures and differentiation of the mesonephric (Wolffian) structures.

### The Development Of The Testes

In embryos with a Y-chromosome, the primary sex cords condense and extend into the medulla of the gonad, where they branch and anastomose to form the rete testis. The connection of the prominent sex cords, called



seminiferous cords (testicular cords) with the surface epithelium, is disrupted when a thick fibrous capsule, the tunica albuginea, develops. The development of the thick, dense tunica albuginea is the characteristic and diagnostic feature of testicular development. Gradually the enlarging testis separates from the regressing mesonephros and becomes suspended by its own mesentery, the mesorchium. The seminiferous cords develop into the seminiferous tubules, tubuli recti, and rete testis, and the seminiferous tubules become separated by mesenchyme that gives rise to the interstitial cells (of Leydig). These cells produce the male sex hormone, testosterone, which induces masculine differentiation of the external genitalia. In addition to testosterone, genital duct inducer and suppressor substances are produced by the interstitial cells which induce development of the mesonephric ducts and suppress development of the paramesonephric ducts. The walls of the seminiferous tubules are composed of two kinds of cells: supporting or sustentacular cells (of Sertoli), derived from the surface epithelium, and spermatogonia, derived from the primordial germ cells. Sertoli cells constitute most of the seminiferous epithelium in the foetal testis. During later development of the testis, the surface epithelium flattens to form the mesothelium on the external surface of the adult testis. The rete testis becomes continuous with 15-20 mesonephric tubules that become efferent ductules. These ductules are connected with the mesonephric duct, which becomes the ductus epididymis. Both paramesonephric ducts regress completely in the male by week 11. The appendix testis persists at the superior pole of each testis and the utriculus prostaticus (prostate utricle) persists from the early joining of the paramesonephric ducts at the back of the urogenital sinus between the mesonephric ducts. The two mesonephric (Wolffian) ducts persist and develop as follows. Their most cranial portion forms the appendix of the epididymis. The segment of the mesonephric duct

opposite the testes forms the epididymis, or ductus epididymidis, with its cranial end connected to the vasa efferentia. The cranial end of the epididymidis is highly convoluted and descends along the testis, still receiving mesonephric tubules (ducts of Haller) which do not connect to the rete testis, however isolated mesonephric tubules form the paradidymis. Distal to the testis the mesonephric ducts acquire a thick investment of smooth muscle and form the ductus deferens. Hence principally the ductus deferens arises from the mesonephric duct. However as each ductus deferens joins the posterior side of the urogenital sinus two lateral outgrowths form the seminal gland or vesicle. The ductus deferens finally becomes the ejaculatory duct, that duct portion between the seminal vesicle duct and the urethra. The ejaculatory ducts open on the posterior wall of the urogenital sinus on an elevation called the verumontanum, or seminal colliculus. The seminal colliculus, a small elevation in the prostatic urethra, is a remnant of the Mullerian tubercle, and is homologous to the hymen. The prostatic utricle, seen between the ejaculatory duct openings, opens on the colliculus in the prostatic urethra and is probably homologous to the vagina.

#### **Development Of The Lower Portion Of The Male Genital Tract**

A number of outgrowths from the pelvic portion of the definitive urogenital sinus, both above and below the opening of the ductus deferens, forms the prostate gland. The prostate develops to enclose the ejaculatory ducts and the prostatic utricle, and completely surrounds the prostatic urethral area of the urogenital sinus. The prostatic urethra thus is composed of the cephalic half, between the bladder and verumontanum, which belongs to the urinary region of the urogenital

sinus, and a caudal half, between the verumontanum and the cranial part of the pelvic segment of the urogenital sinus. The remaining pelvic segment of the mesonephric duct forms the membranous urethra.

## Chapter 4

### The Anatomy Of The Male Reproductive Tract

This chapter has been included to complement the embryological development and congenital lesions of the male reproductive tract especially the vas deferens.

#### Gross Anatomy

The male reproductive tract consists of the testes and their excurrent ducts, the epididymal ducts, the vasa deferentia and the ejaculatory ducts. The seminal vesicles and the prostate gland also form part of the genital tract and make important contributions to semen (Fig 4.1; 4.2).

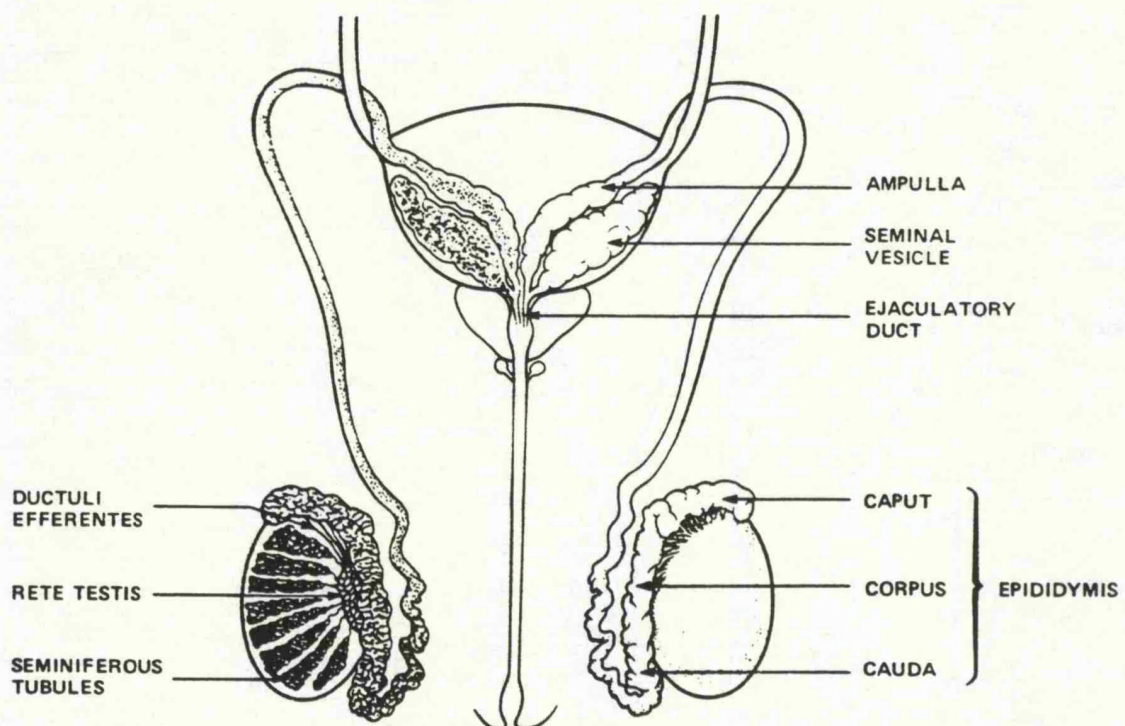


Fig 4.1 Gross anatomy of the male reproductive tract

The testis is the site of sperm maturation and production and is also the main (but not sole) site of male endocrine activity.

The testes are two ovoid organs about 5 cms in length, which are situated in the scrotum on either side of the midline septum. They each lie within the tunica vaginalis which is a potential space containing only a small amount of fluid. Each testis is covered by a thick fibrous capsule known as the tunica albuginea. The rigidity of this covering of the testis is of importance clinically for it will not expand should the testis, for any reason, swell or become oedematous. For this reason, testicular oedema may result in irreversible ischaemic damage to the spermatogenic epithelium. Along the postero-medial border of the testis the tunica albuginea thickens and indents the testis to form a fibrous column of tissue known as the mediastinum testis. Within this mediastinum is a complex network of channels called the rete testis. Immediately below the tunica albuginea lies a loosely-knit layer of connective tissue which contains many blood vessels and which is called the tunica vasculosa. Within the testis, the tunica albuginea sends fibrous septa deep into the substance of the testes which divide each testis into many separate lobules. Lying in each lobule are one or more blind-ended or looped seminiferous tubules. Each testis contains 250-400 seminiferous tubules. The seminiferous tubules are held in connective tissue within a lobule and surrounded by testosterone-secreting Leydig (interstitial) cells, and make up most of the volume of the testis. The seminiferous tubules are initially highly convoluted but straighten out to form ducts known as the tubuli recti. These tubuli recti empty into the multi-channelled complex of the rete testis.

Emerging from the upper pole of each rete testis are some 15-20 very fine ducts known as the efferent ductules. These ductules drain the secretion of the testes which is at this point usually known as the rete testis fluid (Fig 4.2).

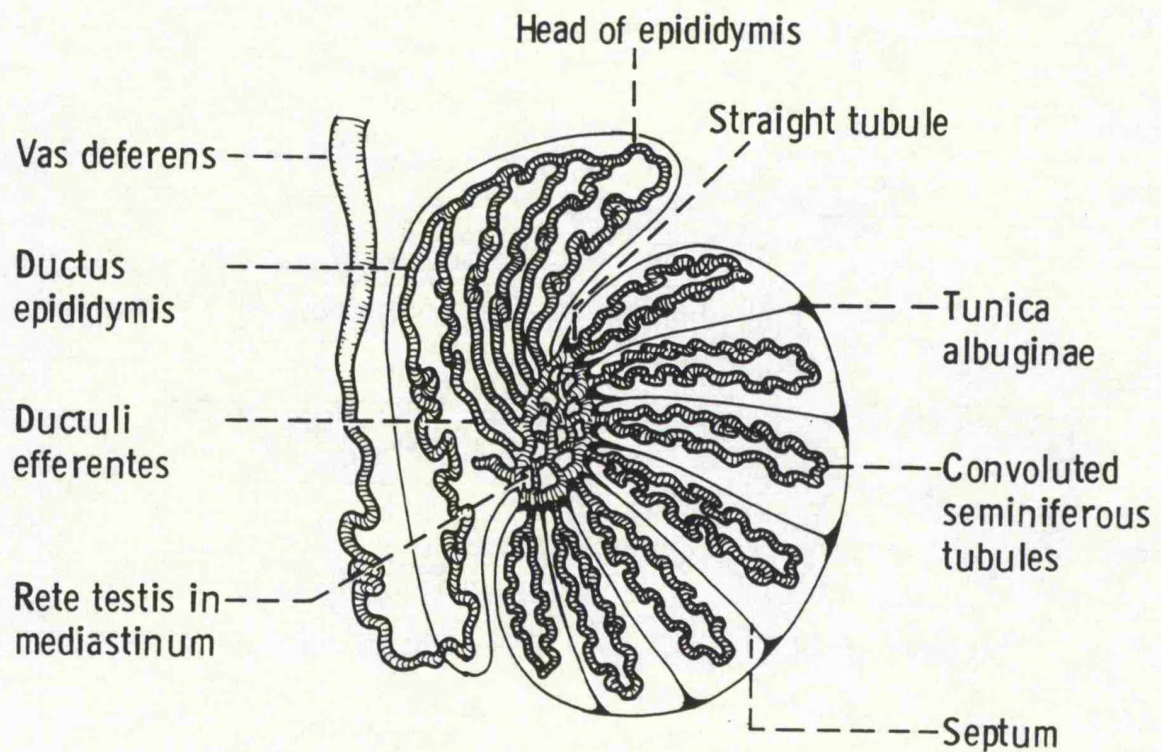


Fig 4.2 Section of testis showing lobules containing seminiferous tubules and development of the duct system.

After their emergence from the testis, the efferent ductules join together to form the first major duct system of the reproductive tract, namely the epididymal duct. The epididymal duct in man is some 6 metres in length and lies as a tightly coiled structure on the postero-medial aspect of each testis.

At its termination each epididymal duct thickens considerably to form the vas deferens. The initial convolution of the vasa is lost and the duct becomes straight as it passes upwards out of the scrotum. The thick-walled vasa deferentia each pass upwards out of the scrotum into the spermatic cord and enter the abdominal cavity through the inguinal canals.

On entering the abdominal cavity each vas deferens turns downwards and forwards to the bladder where each duct passes over the corresponding ureter (Fig 4.3). In this way each vas deferens lies above its corresponding seminal vesicle. At this point each vas deferens dilates to form a chamber known as the ampulla of the vas. Beyond the ampulla, the vas again narrows considerably.

Each seminal vesicle lies below the ampulla of the vas deferens at the back of the bladder. The seminal vesicles each consist of a tightly convoluted muscular blind-ended tube. These tubular structures that form each seminal vesicle narrow to form ducts of the seminal vesicles. Each of these ducts join with its corresponding vas deferens to form an ejaculatory duct. These ejaculatory ducts then pass downwards and forwards to penetrate the prostate gland between the middle and each lateral lobe. Each ejaculatory duct opens into the urethra posteriorly as slit-like orifices on the verumontanum of the prostate (Fig 4.3).



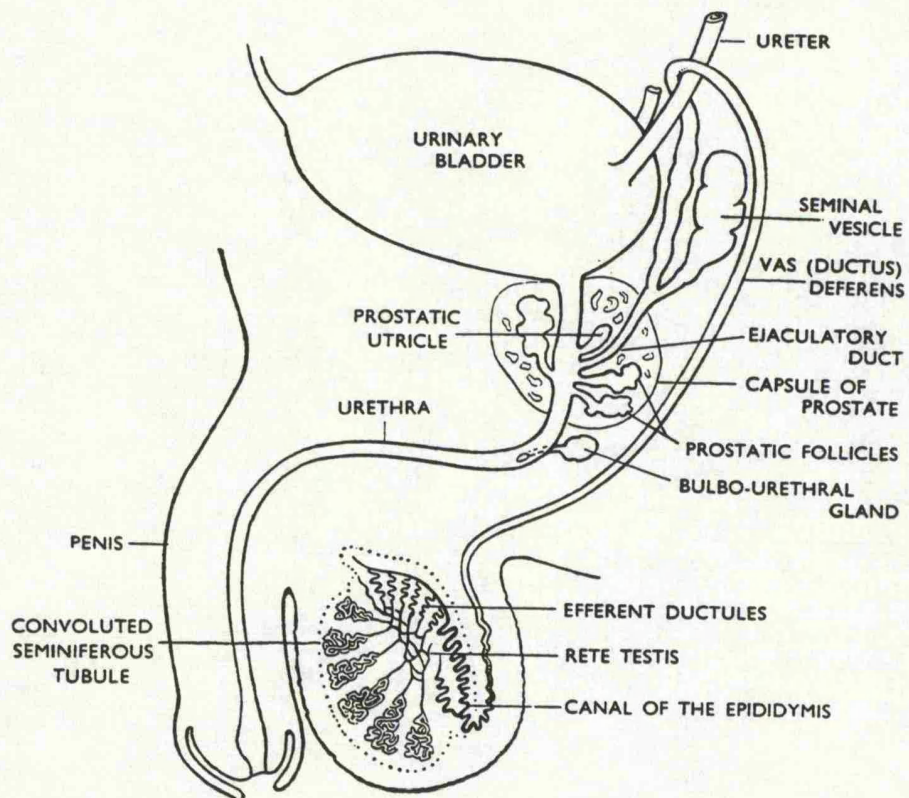


Fig 4.3 Diagram illustrating the path of the vas over the ureter and formation of an ejaculatory duct.



The prostate is a glandular structure which is enclosed within a muscular coat. It has typically three lobes, a middle and two lateral lobes which surrounds the posterior urethra. An anatomical and histological dissection (McNeal) has revealed this organ to be essentially consisting of a central and a peripheral zone with a small transition zone. The secretions of the prostate which are expelled during emission leave the gland by a series of small ducts, all of which enter the prostatic urethra around the verumontanum.

The bulbourethral glands are two small lobular glands which secrete small amounts of mucous and which open into the membranous urethra. The urethral glands also secrete small amounts of mucous and these small glands open into the distal end of the penile urethra.

### **Histology**

Each seminiferous tubule is highly convoluted with a basement membrane supporting Sertoli cells. It is between each of these Sertoli cells that the development of the sperm from the basal spermatogonia takes place.

The walls of the efferent ductules are made up of myoid cells which contract spontaneously. However, this contractile tissue differentiates into smooth muscle in the epididymal duct and its activity becomes increasingly under the control of the autonomic nervous system as the duct descends. The epididymal duct is lined by a very important and biochemically active epithelium which is highly ciliated. The density of this ciliation becomes reduced in the more distal parts of the duct. The efferent ductules, the epididymal duct and the most proximal portion of the vas deferens are held together in connective tissue to form the organ known as the epididymis. The epididymis is therefore not made up solely of the epididymal duct. The seminal vesicles as in the case of the vas

deferens is also lined by columnar epithelium which is capable of secreting mucous.

## Chapter 5

### Composition Of Fluid Transported By The Vas Deferens

The main purpose of the vas deferens is to transport sperm. This chapter discusses composition of seminal secretions and the contribution made by the vas deferens.

### Composition Of Seminal Secretions

Semen is made up of contributions from the testes and its excurrent ducts, epididymal ducts, vasa deferentia, seminal vesicles, prostate, and the bulbourethral and urethral glands. These secretions are propelled into the posterior urethra during intercourse in a process known as emission but only become mixed after their arrival in the vagina at ejaculation.

Although semen contains spermatozoa the whole of the ejaculate is not solely testicular in origin. Indeed, the majority of the semen specimen (more than 95%) arises from sources other than the testis (Lundquist, 1949). Semen is made up from the secretions of all the accessory glands of the male reproductive tract. Changes that are either quantitative or qualitative in one or more of these secretions may produce changes on the composition of the semen that may have profound effects on the fertility potential of the sperm. Infertility can be produced by a disorder of an accessory gland as well as by disturbances in testicular or ductal function.

### Testicular secretions

In terms of volume, the testicular contribution only amounts to around 5% of the ejaculatory volume.

On the passage out of the testis and into the rete testis, the spermatozoa are accompanied by a large number of chemical substances. Rete testis fluid, that is, the fluid arriving at the excurrent ducts of the testes, is rich in androgens, in particular testosterone bound to androgen-binding protein. The substance or substances collectively known as Inhibin which are secreted by the Sertoli cells are present in rete testes fluid (Steinberger & Steinberger, 1976).

#### **The Efferent Ductules And The Epididymal Ducts**

These duct systems add little to semen in terms of volume as indeed the efferent ductules remove water from the rete testis fluid as it emerges from the testis and thus concentrates the spermatozoa. However, the epididymal ducts contribute to the chemical composition of semen in ways that are valuable for fertility.

Several important substances are secreted by the epididymal duct (Turner, 1979). The best known of these is carnitine, which act as an energy source for sperm. Carnitine is not manufactured by the epididymis, but is concentrated by it from blood. It is the enzymatic conversion of carnitine to acetyl-carnitine that supplies energy and contributes to the development of sperm motility (Jequier 1986). Inositol is a sugar and is also secreted into the epididymal duct, but its function in semen is not clear. Lipids and phospholipids are also present in high concentrations in epididymal fluid where they are converted into glycerophosphorylcholine. There is also some evidence, at least in the rat, that the epididymal duct may be able to convert pregnenolone to testosterone and thus be itself an endocrine gland (Jequier 1986).

As they pass down the epididymal duct, the spermatozoa acquire maturity and this may occur at least in part by their coating with a protein produced by the epididymal duct and known as epididymal maturity protein (Brandt et al, 1978).

#### **The Seminal Vesicles And Their Secretions**

The seminal vesicles contribute more than half of the total volume of an ejaculate and thus in terms of their secretions are the most important source of seminal fluid. The seminal vesicles however also produce a variety of chemical substances which are important both functionally and diagnostically. The best known of these substances produced by the seminal vesicles is the sugar fructose. This provides a vital energy source for sperm which is essential for their motility. For this reason, exclusion of the seminal vesicular component from the ejaculate will result in almost completely immotile sperm. Likewise, disease of the seminal vesicles may result in poor maturity sperm (Eliasson, 1971). The seminal vesicles are also the main source of the seminal prostaglandins (Eliasson, 1959) which may also play a role in maintaining sperm motility. Seminal vesicles also appear to be the source of fibrinogen-like substances that cause the semen to clot after ejaculation (Tauber & Zaneveld, 1976).

#### **The Prostatic Contribution**

The prostatic contribution makes up, volumetrically, the second largest single contribution to the semen. However, like that of the seminal vesicles, the prostatic contribution is also very important biochemically. In the experimental animal, the prostate secretes not only the enzyme

vesiculase (Walker, 1910) which acts on the fibrinogen-like protein produced by the seminal vesicles to cause semen to clot, but it is also the site of production of many protease enzymes, whose action induces liquefaction of the clot (Gotterer et al, 1955). The prostatic contribution to semen also contains a number of bacteriostatic amines, such as spermine, whose crystals as spermine phosphate may be seen in semen on microscopy. Acid phosphatase is also present in high concentration in semen. It is this stable enzyme that is used in forensic medicine for the identification of seminal fluid. Prostatic secretions also act as a source of both calcium and zinc (Eliasson and Lindholmer, 1971). The salts of citric acid are also present in abundance in prostatic secretions.

#### **Secretions Of The Bulbourethral & Urethral Glands**

The volume of the combined secretions of these glands is small, but their biochemical content may be of great relevance in infertility. These secretions consist mainly of mucoproteins whose action is likely to be solely one of lubricating the distal urethra. However, the secretions can occasionally contain specific anti-sperm antibodies and these glands may therefore be a cause of infertility.

It is clear that pathology in any one or more of these accessory glands may result in semen of altered volume and of changed biochemistry, either of which may result in infertility. A knowledge of the contribution of each part of the male reproductive tract in the production of semen is therefore of great importance for the proper undertaking of male infertility.

## Chapter 6

### The Autonomic Innervation of the Vas Deferens

The vas deferens is not merely a passive conduit for sperm, but acts as an important structure in propelling the sperm from the epididymis in the emission stage of ejaculation. It may also play a role in destroying excess old sperm, as spermiophagic cells can be seen in the epithelia of the ampulla (Hamilton & Cooper, 1978). To enable it to perform its prime function of sperm transport the specialized muscles require a sophisticated integral nerve supply. The narrow circular lumen of the vas is surrounded by three layers of smooth muscle, an inner and outer longitudinal layer, separated by a thick circular layer. Along the vas there is little change in the structure of the inner two layers. The inner layer is very thin with many oblique muscle cells scattered amongst the longitudinal cells (Merrillees, 1968). The circular layer is very thick comprising the majority of smooth muscle in the tissue. The outer layer in the rat shows a variable arrangement dependent on position. The epididymal end shows a distinct flattening, with the longitudinal fibres arranged asymmetrically along the plane of the supporting mesentery; this pattern is lost as it approaches the prostatic end and the musculature becomes evenly distributed.

The vas deferens together with the epididymis, seminal vesicle and prostate has only an autonomic nerve supply (Potts, 1957). Neuromodulation of this autonomic supply by peptidergic innervation will be discussed in the next chapter. The sympathetic supply of the autonomic system comes from the pre-sacral nerve (superior hypogastric plexus), which divides at the first level of the sacrum into two hypogastric nerves. The nerves terminate, one on each side of the rectum, in the

inferior hypogastric (pelvic) plexus. The inferior hypogastric plexus is widely spread and covers the prostate, seminal vesicles, etc. The filaments of the vesicle also give rise to periurethral nerve loops that assist in the innervation of the ejaculatory ducts, and an occasional filament passes down the vas deferens to the epididymis. In addition, the middle gonadic nerves, which arise from the pre-sacral nerves, supply the epididymis and the vas deferens. Finally, the inferior gonadic nerves, which arise from the nerve loops around the lower end of the ureter and from adjacent inferior hypogastric plexus, supply the remainder of the vas deferens.

All three layers of both vas deferens musculature are equally innervated (Baumgarten et al, 1971; Pabst, 1969). Large nerve fibres run only between the outer longitudinal and the middle circular layers. The nerve network consists of a few pre-ganglionic fibres and many post-ganglionic fibres that extend to individual muscle cells.

The vas deferens as previously mentioned, is innervated by sympathetic fibres of the hypogastric nerve, these fibres originate from the upper lumbar nerves (L1-L3) (Langley & Anderson, 1895; Anton et al, 1977). The innervation of the vas is different from most other adrenergic innervation in that the ganglia are not situated in the sympathetic chain or in other ganglia (such as the inferior mesenteric), situated far from the site of the neuroeffector junction. They in fact lie within the terminal part of the hypogastric nerve (Sjostrand, 1965; Ferry 1967), where it divides to supply the internal genitalia and bladder. This arrangement was first suggested by Langley & Anderson in 1895, who observed nerve cell bodies near the prostate and 'internal generative organs'. Sjostrand provided further evidence for this in 1965. Sectioning the fibres below the inferior mesenteric ganglion failed to produce a notable decrease in noradrenaline



content. He subsequently termed the postganglionic fibres to the vas as being 'short' adrenergic neurons, as opposed to 'long' in the standard sympathetic arrangement (Sjostrand, 1965). This discovery explained the apparent antagonistic behaviour of hemicholinium to stimulation of the hypogastric nerve as shown in the vas-hypogastric nerve preparation (Hukovic, 1961). In the Macaque the ganglia are found in the actual walls of the vas deferens (Sjostrand, 1965). In the guinea pig and rat they are found in the angle between the seminal vesicle and the vas deferens. The ganglion is rather diffuse, being spread out over 2 cms in the guinea pig (Ferry, 1967; Merrillees et al, 1963).

The 'short' unmyelinated adrenergic fibres divide up into nerve trunks running along the surface of the vas, branching off into the tissue as they progress towards the epididymis. They form a dense 'ground plexus' of branching and anastomosing small nerve trunks (2-8 neurons), with branches terminating in single axons (Hillarp, 1959; Merrillees, 1968; Burnstock, 1970). In terminating they lose their surrounding Schwann cells, and become bare. There are very few myelinated neurons, and these too become bare at termination. The ground plexus in the vas is very dense (Merrillees, 1968; Burnstock, 1970), indeed it is the most densely innervated organ by the sympathetic system. The density of innervation varies between species. There may be up to 6 close junctions per muscle cell in the mouse (Burnstock, 1970; Yamauchi & Burnstock, 1969). In many other tissues, the sympathetic innervation is very sparse, and the response relies upon low resistance pathways between cells, for conduction of nerve impulse. In the mouse, innervation of the tissue is not complete until 6 months after birth, though after 18 days the tissue is functioning, and EJPs can be observed (Furness et al, 1970; Yamauchi & Burnstock, 1969). Fluorescent staining of the nerve fibres has shown a

variation in the distribution of the ground plexus. The level of innervation increases towards the lumen, with the inner longitudinal layer having a very high innervation with many axon terminations. The innervation does not extend to the lamina propria or epithelial cells (Dixon & Gosling, 1972; Furness & Iwayama, 1972). There is no sensory innervation to the tissue (Merrillees, 1968). In studies staining for acetylcholinesterases, the stains showed a possible cholinergic innervation. The distribution of the cholinergic fibres was uneven and sparsely populated; mainly in the inner longitudinal and circular muscle layers and more evident at the epididymal end. However 90% of all nerve bundles did not contain any cholinergic fibres and the cholinergic neurons failed to form any neuro-muscular junctions on termination (Furness & Iwayama, 1972; Dixon & Gosling, 1972). The cholinergic fibres would appear to play no part in the process of contraction, but may be responsible for some presynaptic modulation (Ambache & Zar, 1970; McGrath, 1978).

There is no discrete endplate as found in the skeletal neuromuscular junction. The transmitter is released from varicosities found along the axons. The varicosities contain granular vesicles up to 100nm., which contain noradrenaline and are released 'en passage' as the action potential progresses along the nerve. The varicosities are 0.5-0.75  $\mu\text{m}$  in diameter, as opposed to 0.1-0.2  $\mu\text{m}$  in the axon between the varicosities (Merrillees, 1968), and occur with a frequency of 10-30/100  $\mu\text{m}$  (Burnstock, 1970). The varicosities in the non-terminal axon rarely form a junction, being 50-100  $\mu\text{m}$  from the smooth muscle. The Schwann cells leave the varicosities bare, so allowing some neurotransmission, though of a rather diffuse nature. The terminal axons in the vas may form 'close' neuromuscular junctions of 8-20nm in the mouse (Yamauchi & Burnstock, 1969;

Burnstock & Costa, 1975), where the basement membrane of the nerve and muscle fuse. In the mouse it appears that virtually every muscle cell has its own close junction, the muscle cell always comes into contact with the nerve trunks at some point on its surface (Merrillees, 1968; Furness et al, 1970; Burnstock, 1970; Burnstock, 1986a). This is in contrast with the guinea pig, where only 1 in 5 cells may form a close junction (Merrillees, 1968). The inner longitudinal layer is totally innervated by terminal close junctions, the axon being embedded in the muscle cell itself (Furness & Iwayama, 1970). In other cells the tight junctions are often to be found in gutters, usually making contact near to the nucleus (Merrillees, 1963; Burnstock, 1979). There is little post-junctional specialisation as seen in the skeletal neuromuscular junction, though at close junctions cisternae are often seen and will follow the cleft. These membrane bound cisternae are probably parts of the sarcoplasmic reticulum (Richardson, 1962; Burnstock & Costa, 1975; Burnstock, 1979; Merrillees et al, 1963, Burnstock, 1986).

## Chapter 7

### The Peptidergic Innervation of the Vas Deferens

A non-adrenergic, non-cholinergic component of the autonomic nervous system is believed to play an essential role in the mechanism of many physiological functions, including those of the male reproductive system. There is substantial evidence that this component may contain neuropeptides.

Vasoactive Intestinal Polypeptide (VIP) is a 28 - amino acid peptide, which was first isolated from extracts of porcine duodenum (Said and Mutt, 1970a,b; 1972). It was found to have a variety of biological actions, most notably a powerful vasodilatory effect (Alm et al. 1980). Its amino- acid sequence was established in 1974 (Mutt and Said, 1974), and found to belong to the secretin-glucagon family of peptides. The chemical similarities between VIP and secretin-glucagon stimulated speculations that VIP was a hormone. These speculations were greatly encouraged when Polak et al. (1974a, b) described VIP immunoreactivity in endocrine cells of the digestive tract of several species. In 1976, several groups reported independently that immunoreactive VIP resides in an extensive system of nerves in the periphery as well as in the brain (Bryant et al 1976a,b; Larsson et al 1976a,b; Said and Rosenberg 1976; Sundler et al 1977). As a result VIP was regarded as being a neuropeptide in addition to being a hormone. In subsequent years VIP was firmly established as a neuropeptide (Larsson et al., 1976a; Sundler et al., 1977, 1978, 1979; Uddman et al., 1978 ). There is now much evidence that VIP is a neuropeptide only and not a hormone. This conclusion is based on investigations employing highly specific VIP antisera that fail to recognize the immunoreactive material in endocrine cells. Hence, the immunoreactive material in these

cells is probably distinct from VIP, although chemically similar. Generally VIP seems to be associated with three different types of structures : exocrine glands and surface epithelia, blood vessels, and non-vascular smooth muscle.

Neuropeptide Y (NPY) is a recently discovered peptide of the pancreatic polypeptide family and its occurrence in neuronal elements in the gastrointestinal tract and brain (Lundberg et al. 1983; Sundler et al. 1983), heart (Gu et al. 1983) and uterus (Stjernquist et al. 1983) has been described. To date, only very little is known about the functional role of NPY. NPY appears to be able to both facilitate and inhibit adrenergically mediated smooth muscle activity and possibly also to interact with cholinergic nerves (Lundberg et al. 1983; Ekbald et al. 1984; Stjernquist et al. 1983). This is of interest as NPY has been shown to be present in a population of adrenergic nerves (Ekbald et al. 1984; Lundberg et al. 1983).

Vasoactive Intestinal Polypeptide and Neuropeptide Y in neuro active nerves have been further described in the male genitalia of several species including man. However, studies on the vas deferens have been very sparse. The female reproductive has been extensively studied in the rat (Papka et al. 1985) but little attention has been given to the vas deferens of the rat species. The functional significance of these peptides in the urinary tract is not clear or it is often assumed that they serve neurotransmitter or neuromodulator functions. The adrenergic and cholinergic mechanisms operating normally in the tubular reproductive organs are not well understood since many effects of adrenergic and cholinergic agents vary with the species and the hormonal or reproductive state of the animal. Evidence of at least three classes of peptide containing nerves in the rat reproductive tract further indicate that complex neural interactions are

likely to occur at the peripheral sites and influence control of the reproductive tract. These peptides innervate vascular, non-vascular, smooth muscle and sub-epithelial plexus. Such a complex neuroendocrine interactions could occur at peripheral effector sites. It is conceivable that these could influence for example co-ordination of muscle activity important in transport of sperm or ova.

The majority of spermatozoa are stored in the cauda epididymis and transported into the ductus deferens during sexual stimulation. It is during its passage through the epididymal duct and the vas deferens that important changes take place that endow the sperm with the potential for fertility and for movement. The secretory and contractile capabilities of the vas deferens are two important factors that depend on an integral autonomic innervation of the vas deferens. With increasing request for vasovasostomy it is important to study the autonomic innervation of the vas deferens especially in the light of the role of neuropeptides and in association with acetylcholinesterase positive and noradrenergic nerves.

## Chapter 8

### Neurotransmission and Neuroreceptors

Chapters 6 and 7 have described the autonomic and peptidergic innervation of the vas deferens. Noradrenaline is the major neurotransmitter of the sympathetic nervous system and the vas deferens dense noradrenergic innervation makes it an excellent model to be studied for sympathetic innervation. This latter property of dense sympathetic innervation is critical for vas contractility. Prior to consideration of the contractile properties of the vas deferens it would be useful to summarise the development and background of chemical neurotransmission, and discuss other neurotransmitters or neuromodulators such as ATP which are involved in contraction.

#### Noradrenaline, a neurotransmitter

The first suggestion of chemical neurotransmission, was proposed by Elliott in 1904, when he proposed that adrenaline might be released from peripheral sympathetic nerve terminals, and thus produce the effects of nerve stimulation. Elliott was not completely correct, as adrenaline does not mimic all the effects of the nerve evoked response, but was correct in the general principle of chemical neurotransmission (adrenaline is the major sympathetic neurotransmitter in amphibians). In the early 1930's Cannon and Bacq demonstrated the release of an adrenaline like substance 'sympathin' in the cat heart which behaved similarly to adrenaline. Barger and Dale had noted that noradrenaline was more potent than adrenaline back in 1910, but it was not until 1934 that Bacq suggested that noradrenaline ( NA ) might be the neurotransmitter of the sympathetic

system (Gershon, 1970; Bacq, 1975). In 1946 von Euler demonstrated by parallel bioassay that noradrenaline was indeed the major sympathetic neurotransmitter, and localised in the nerve terminals. The sympathetic neuro-effector junction was the first in which chemical neurotransmission was demonstrated.

Noradrenaline is synthesised from tyrosine, a common dietary amino acid. The tyrosine is hydroxylated to Dopa by tyrosine hydroxylase, and then decarboxylated by dopa decarboxylase to dopamine in the axoplasm distributed throughout the neuron (Weiner, 1970; Burnstock & Costa, 1975). The dopamine enters the membrane bound vesicles by an active uptake mechanism. It is this mechanism that reserpine blocks so causing depletion of noradrenaline, the free dopamine and noradrenaline diffusing out of the vesicle is degraded by mono-amine oxidases (Rutledge & Weiner, 1967). It is within the vesicle that noradrenaline is finally formed by dopamine  $\beta$ -hydroxylase. The vas has one of the highest levels of noradrenaline (18.5  $\mu\text{g/g}$  in the guinea-pig) due to the density of its innervation, and a relatively low turnover (Blakeley et al., 1970). Most of the noradrenaline is stored in vesicles.

There are two forms of vesicles, large granular vesicles (50 nm), and small granular vesicles (60-120 nm). In the vas 96% are small and granular, and 4% large and granular (Klein and Langercrantz, 1981). The majority of vesicles are found in the terminal varicosities of the axon. They are formed in the cell body, travel down the axon and have a half life of one to two days (Burnstock & Costa, 1975). As they progress, the NA content of large vesicles may increase by 60% whilst the other contents remain



comparatively constant. A large proportion of the noradrenaline (>90%) is bound within the vesicle, the rest being free in extravesicular pools (Klein & Lagercrantz, 1981).

#### **Sympathetic vesicles and other neurotransmitters**

The sympathetic vesicle is accepted to be the unit of neurotransmission. Besides noradrenaline the vesicles contain other substances, with which it may form complexes, and go to make up the granules. These include ATP, Ca<sup>2+</sup>, Chromagrannin A, met-enkephalin, neuropeptide Y, phospholipids and dopamine- $\beta$ -hydroxylase (Fried, 1980; Klein & Lagercrantz, 1981; Stjarne & Lundberg, 1986). A major component of the vesicle is ATP which is found in the ratio of 1:20 to 1:60 molecules of NA in both small and large vesicles (Fried, 1980; Stjarne & Lundberg, 1986). ATP may be important as a counter ion for NA to reduce the osmolarity (Klein & Lagercrantz, 1981). A large amount of ATP is free in solution in the vesicle, and this store may be of use as a neurotransmitter in its own right, or play a role in neuromodulation (Fedan et al, 1981; Meldrum & Burnstock, 1983; Sneddon & Westfall, 1984). Neuropeptide Y, dopamine- $\beta$ -hydroxylase and met-enkephalin are only found in the large vesicles. Neuropeptide Y (Ch.7) may play a role in neuromodulation, or as an amplifying mechanism for the post-junctional response (Stjarne & Lundberg, 1986). Dopamine- $\beta$ -hydroxylase is the enzyme for the final conversion to noradrenaline. Its localisation in the large vesicles implies that only these can produce NA which is then taken up by the small vesicles.

The contents of the vesicles are released into the junctional cleft by exocytosis, which has been shown to occur in many cells (Axelrod, 1972; Burnstock & Costa, 1975; Trubatch & Van Harrevald 1981). Direct release

into the cleft can also occur due to the resultant extracellular concentrations of the soluble vesicular contents matching those within the vesicle (Burnstock & Costa, 1975). The precise mechanism of stimulating release is still unknown, but requires influx of calcium to the nerve terminal. The calcium may be required for contraction of a microtubular system causing release, or else stimulate some other process. Tyramine can stimulate release without the presence of calcium. The entry of calcium provides an ideal mechanism for control of release (Axelrod, 1972; Burnstock & Costa, 1975; Alberts et al, 1981).

#### Vesicle release

Once the vesicle is released its contents may interact with the pre- or post-synaptic membrane receptors, providing a mechanism for the transduction of the nervous impulse to the effector tissue, or the contents can be washed away, broken down or taken back up for re-use. Noradrenaline, ATP and neuropeptide Y may bind to post-junction  $\alpha_1$  receptors (Fedan et al, 1981; Sneddon & Westfall, 1984; Stjarne & Lundberg, 1986). They may be washed away in the interstitial fluid. Noradrenaline may be actively taken up into the neuron by an uptake mechanism. Such a mechanism is very important in the noradrenergic response, and is a major fate of noradrenaline (Iversen, 1967; McGrath, 1985). Overflow experiments rely on this mechanism, and the re-use of noradrenaline after release. Once taken back up it may still be broken down by monoamine oxidases. Cocaine blocks uptake, and so enhances noradrenergic transmission. Noradrenaline may also be broken down by catechol-O-methyltransferase to methoxynorepinephrine (Iversen, 1967; Burnstock & Costa, 1975). ATP is also attacked by Ectonucleotidases to form Adenosine. The Adenosine may be important as a regulator of release (Moody et al, 1984). Adenosine is rapidly accumulated and broken down to Inosine

(Hedqvist & Fredholm, 1976). Another possibility for noradrenaline, ATP and Neuropeptide Y is to feedback on the nerve terminal and regular release (Kirpekar & Puig, 1971; Clanachan et al, 1977; Stjarne & Lundberg, 1986). Up to 10 vesicles or quantal packets of transmitter are released by a varicosity as the action potential progresses down the axon. The probability of releasing a vesicle is low, only 200 out of 20,000 varicosities in an axon will release a vesicle, and it is likely to be only one vesicle (Stjarne & Astrand, 1985b; Stjarne, 1986). At higher frequencies of stimulation ( $>0.5\text{Hz}$ ) the release becomes facilitated, due to calcium entering at a higher rate than its removal, and more vesicles are released (Blakeley et al, 1986). At even higher frequencies large vesicles are released, which contain neuropeptide Y (Stjarne & Lundberg, 1986). Each release from a single varicosity of a number of packets of transmitter produces a 'discrete event' post-junctionally; discrete events may summate to form excitatory junction potentials (EJPs) (Blakeley et al, 1979). The quantal release of packets of transmitter to produce discrete events provides good evidence for viewing the vesicle as the unit of neurotransmission at the sympathetic neuro-effector junction, analogous to that at the neuromuscular junction (Del Castillo & Katz, 1954; Blakeley et al, 1979). Stjarne & Astrand (1984b) suggested that each discrete event is made up of only one quantal packet of transmitter. Spontaneous EJPs (sEJPs) have also been observed, and are presumed to be due to spontaneous and random release of vesicles at the nerve terminal.

### Pre-junctional modulation of transmitter release

#### Alpha 1 and alpha 2 adrenoceptors

Many experiments produced confusing results and Ambache & Zar (1970), even considered noradrenaline to be inhibitory in the vas. The full explanation lies in the concept of pre-junctional modulation of transmitter release. Kirpekar & Puig (1971) put forward the idea of pre-junctional modulation. Negative feedback modulation implies that the released transmitter also binds to receptors on the nerve terminal, which then inhibit further release of transmitter. The first inklings that any such mechanism might be present came with the discovery that phenoxybenzamine, an alpha-blocker potentiated neuronal release (Brown & Gillespie, 1957). They however suggested that the noradrenaline was lost at the receptor. Phenoxybenzamine also blocks neuronal uptake and was found to increase noradrenaline release at concentrations that did not inhibit uptake (Enero et al, 1972).

The negative feedback mechanism as proposed by Kirpekar & Puig (1971), relies on a threshold of noradrenaline within the junction to stimulate feedback. In support of the threshold theory, reserpinisation produces a state where there is not enough noradrenaline to reach the threshold for feedback so alpha-antagonists are inoperative, and produce no enhancement of release (Enero & Large, 1973). It was by examining the relative potencies of alpha-blockers pre- and post-junctionally, that the division of alpha-receptors into two subtypes was proposed. Dubocovich and Langer (1974) showed that phenoxybenzamine had a near 30-fold greater effectiveness at the pre-junctional site over the post-junctional receptor. Langer (1974) later termed these alpha-1 and alpha-2 for the post- and pre-junctional adrenoceptors respectively. Though the definition of

two subtypes of alpha-adrenoceptors was originally based on the anatomical position further evidence has come from other antagonists and agonists such as yohimbine and clonidine respectively which have much higher affinity for alpha-2-adrenoceptors (Starke et al, 1975; Langer, 1977). The most telling evidence for alpha-2 mediated feedback control comes from the consistency of responses to alpha-2-agonists and antagonists in a wide range of tissues (Starke, 1987). There are some discrepancies to the theory, such as the differential actions of cocaine in blocking the pre-junctional action of clonidine, whilst not affecting the inhibition of alpha-methylnoradrenaline (Langer & Dubocovich, 1981). To explain this Ruffolo and colleagues (1984) suggested a two-site model for the alpha-2-adrenoceptors, with an Imadazoline binding site, and a phenylethylamine binding site that overlap. Uptake may only interfere with the imadazoline binding site.

The site of the alpha-2-adrenoceptor feedback control is likely to be on the pre-junctional nerve terminal or varicosity. Removal of the post-junctional site does not destroy negative feedback (Fillinger, 1978). Originally it was suggested that a trans-synaptic mechanism might operate. Prostaglandin E2 was suggested as an inhibitor of neuronal release, being produced at a post-junctional site, and acting on the nerve to inhibit further release (Swedin, 1971; Hedqvist, 1974a & b). Prostaglandin E2 does not produce any neuromodulation in some tissues, and Indomethacin does not affect modulation where Prostaglandin E2 is effective (Dubocovich & Langer, 1975; Clanachan, 1977).

Opponents of negative feedback have suggested that alpha-blockade may work at other sites, as attempts to block the feedback mechanism with yohimibine are not very successful. Kalsner & Quillan (1984) were sceptical of autoinhibition when they found that yohimibine became less effective as stimulation pulse width increased, though the antagonism should have been increased. Yohimibine has also been found to prolong potassium efflux, increasing the time for the action potential and subsequent probability of release at the varicosity (Kalsner & Quillan, 1984). Blakeley et al (1986) have also demonstrated discrepancies with yohimibine action using EJPs and discrete events as a measure of release. Clonidine and yohimibine altered the quantal content and probability of release. They also showed a differential effect of varying calcium concentrations. As calcium increased yohimibine became less effective, whilst clonidine became more effective. They consequently suggested that endogenous noradrenaline does not exert any feedback ( Blakeley et al, 1986).

#### **Purinergic receptors**

Other possible neuromodulators have been suggested, in particular Adenosine and its family of related purines, which are very active at the neuromuscular junction (Burnstock, 1986b). ATP is a known constituent of vesicles, and is possibly released as a cotransmitter with noradrenaline at the vas neuro-effector junction (Fedan et al, 1981; Sneddon & Westfall, 1984). Ginsborg & Hirst (1972) first demonstrated the prejunctional action of adenosine, and that it could be inhibited by the methylxanthine theophylline. Clanachan (1977) showed that adenosine and ATP could inhibit noradrenaline release from the neurons of the rat vas deferens. This suggested a pre-junctional purinergic receptor that could modulate

release. The pre-junctional P<sub>1</sub>-purinoceptor, can be further subdivided into A<sub>1</sub> and A<sub>2</sub> which show different agonist potencies, and stimulate or inhibit adenylate cyclase respectively (Van Calker et al, 1979). Recently a further subtype of P<sub>1</sub>-purinoceptor has been proposed which shows a different series of agonist potencies, and is termed A<sub>3</sub>. This may actually be a calcium channel, as dihydropyridine calcium channel blockers will block the pre-junctional action of adenosine (Riberior & Sebastiao, 1986). Blakeley et al (1988) have recently examined the pre-junctional receptor in the mouse vas deferens, and it appears to resemble the A<sub>3</sub> subtype in agonist potency studies. ATP is most probably broken down by ectonucleotidases on the post-junctional membrane to adenosine and can then bind to the pre-junctional P<sub>1</sub>-purinoceptor which shows higher affinity for adenosine and AMP than for ATP and ADP (Clanachan, 1977; Paton, 1981; Moody et al, 1984; Welford, 1987). This possible feedback mechanism has been subsequently confirmed in other tissues and species (Fredholm & Hedqvist, 1976; Sneddon & Westfall, 1984; Stjarne & Astrand, 1984). Though antagonists to P<sub>1</sub>-purinoceptors have been shown to reduce inhibition by exogenous agonists their actual role in vivo is still in doubt. Stjarne & Astrand (1984) using alpha, beta-methylene ATP to block the purinergic receptors demonstrated an increase in release in the guinea pig but not in the mouse. Similarly Blakeley et al (1988) failed to show any endogenous feedback inhibition in the mouse vas deferens. This apparent inactivity may be due to the high metabolism of Adenosine by the vas (Fredholm & Hedqvist, 1976; Paton, 1981). More recently Neuropeptide Y, another component of the sympathetic vesicle, has been suggested to feedback on the nerve. It can abolish EJPs and reduce noradrenaline overflow when applied exogenously, its role in vivo is still in doubt (Stjarne & Lundberg, 1986).

### Feedback control

The actual mechanism by which feedback is controlled is still open to discussion but appears in general to be mediated by altering calcium influx. There are two posulated sites for inhibition of transmitter release, at the varicosity itself, inhibiting the depolarisation-secretion coupling mechanism, or by preventing the spread of the action potential to the varicosity. Facilitation of release, and auto-inhibition are thought to affect different sites in the process of release, facilitation promotes secretion-coupling, whilst autoinhibition inhibits the spread of nerve impulses (Alberts et al, 1981; Blakeley et al, 1984; Starke, 1987). Inhibition by adenosine and noradrenaline may work by opening K<sup>+</sup> channels using cAMP as a second messenger, so decreasing the timecourse of an action potential, and reducing calcium entry and spread of the action potential (Starke, 1987). Alternatively adenosine and noradrenaline may reduce calcium currents directly (Paton, 1981; Schofield & Steel, 1988). If the A<sub>3</sub> adenosine receptor is a channel itself, this would allow for an easy control of calcium entry. Adenosine has been reported to act as a calcium channel antagonist, and behaves as an antagonist to calcium (Ribeiro & Sebastiao, 1986).



## Chapter 9

### Physiology of Vas Deferens Contraction

#### The response of the vas deferens to field stimulation

When Hukovic (1961) first described the response of the vas-hypogastric nerve preparation to nerve evoked stimulation, he described a monophasic response. This form of the response was considered the full response of the vas, till Swedin (1971) demonstrated not a monophasic , but a biphasic response, which became apparent as the duration of the stimuli was increased. After three seconds a second peak was observed which then decayed to produce a residual tonic component. Even before Swedin discovered this facet of the response, controversy had already erupted over the true nature of the nerve evoked response.

Sjostrand (1965) had shown the existence of ganglion cells near the vas. This explained a possible cholinergic input to the innervation, but the nerve evoked response still showed a 'non-adrenergic' component. Ambache & Zar (1970) even went so far as to suggest that noradrenaline was inhibitory to the nerve evoked response. They demonstrated that the nerve evoked response (the monophasic form) was not blocked completely by alpha -blockers such as phenoxybenzamine. Reserpinisation failed to abolish the response, though it could be abolished by 6-OH Dopamine (chemical sympathectomy). Swedin had found similar results in the biphasic response, except that the second response was affected by alpha -antagonists and reserpinisation. With this discovery the response of the vas was divided into the classic picture of a primary 'non-adrenergic' and secondary 'adrenergic' component. Since

that discovery in the guinea pig vas deferens, the same form of response has been observed in the rat, mouse, rabbit, and dog (Swedin, 1971; Anton et al, 1977, Stjarne & Astrand, 1985). It has not however been shown in man, which lacks the initial 'spike' and does not respond to single stimuli, but produces cyclic contraction and relaxation on sustained stimulation (Anton & McGrath, 1977). Dividing the vas into halves or sections has revealed a selectivity of each end for a different component, the 'spike' is dominant in the prostatic half, whilst the secondary component or 'hump' is dominant in the epididymal (Anton, Duncan & McGrath, 1977; MacDonald & McGrath, 1980). Altering the frequency of stimulation or the temperature also selects between the two components, with increased frequency especially, causing a large increase in the secondary response (Birmingham & Freeman, 1976; Stjarne & Lundberg, 1986).

McGrath (1978) observed that the response to a single impulse could also be divided into two phases. The primary response was again resistant to reserpine, alpha-blockade, and could be isolated to the prostatic half of the vas. On adding an uptake blocker (cocaine), a third component was observed by Brown et al. (1984), which was sensitive to adrenergic blockade. Work on the subdivision of the biphasic response also continued on electrophysiological lines. Burnstock & Holman (1966) found that EJPs could still be produced in reserpinised preparations. Blakelely et al. (1981) showed that nifedipine blocked the primary component of the response to a single stimuli. The EJPs were unaffected by nifedipine, which blocked the action potential. Prazosin did not inhibit the EJPs, but in fact potentiated them. Thus confirming that the EJPs mediated the primary component and were produced by the non-adrenergic transmitter.

The vas does not just consist of a longitudinal muscle, but also an inner circular layer that plays little part in the longitudinal response (Anstey & Birmingham, 1980). The circular layer also demonstrates a biphasic response, with a similar non-adrenergic 'twitch' and adrenergic secondary phase, that has the same distribution along the vas as the longitudinal response (Anton et al, 1977; Busatto & Jurkiewicz, 1985). The inner longitudinal layer does not affect either the overall longitudinal response or circular response (Anstey & Birmingham, 1980).

Ambache & Zar (1970) commented that ATP applied exogenously produced rapid contractions in the vas, but discounted it, due to the high rate of receptor desensitisation, and slow recovery. Holck & Marks (1978) demonstrated that the stable analogue  $\alpha,\beta$ -mATP could produce contractions in the vas and augment the response to noradrenaline. Westfall et al. (1978) using tritiated adenosine demonstrated the possible release of purines from the sympathetic nerves supplying the vas. It was not until the arrival of purinergic antagonists that the concept of ATP cotransmission began to be accepted. Fedan et al (1981) showed that ANAPP3 inhibited the response to ATP, and the primary components of the tetanic and single response. Further evidence came from electrophysiological studies where ANAPP3 produced an inhibition of EJPs which prazosin could not achieve (Sneddon et al, 1982).  $\alpha,\beta$ -mATP a stable analogue of ATP, was also used to good effect and could produce the same antagonism as seen with ANAPP3.  $\alpha,\beta$ -mATP produces a long term desensitisation and hence tachyphylaxis. The initial 'twitch' response of the tetanic response was obliterated (Meldrum & Burnstock, 1983).  $\alpha,\beta$ -ATP also blocked the EJPs (Sneddon & Westfall, 1984). Local application of ATP was found to mimic EJPs, whilst NA produced no such effect. The mechanical response to noradrenaline

mimics that of the secondary tetanic response, whilst ATP mimics the time course of the initial 'twitch' (Sneddon & Burnstock, 1984). Experiments on the pithed rat have confirmed the lack of inhibition by prazosin on the primary tetanic response, whilst Purinoceptor desensitisation using intravenous injection  $\alpha,\beta$ -mATP produced an inhibition of the primary response. The tachyphylaxis to  $\alpha,\beta$ -mATP was harder to maintain in vivo and the primary response could only be attenuated (Bulloch & McGrath, 1988). The desensitisation to  $\alpha,\beta$ -mATP has also been reported to affect the adrenergic component as well as the non-adrenergic response in the vas (Amobi & Smith, 1987a).

#### Cotransmission of neurotransmitters

Cotransmission implies the simultaneous release of two or more transmitters from the same neuron, which act upon the same target cell (Campbell, 1987). The concept of two transmitters being released from the same nerve has been around for some time, and more nerves are continuously being identified as sites of possible cotransmission (for a full review see Campbell, 1987). As discussed previously ATP is a known constituent of vesicles at the sympathetic terminals (Fried, 1980), so could show co-release. Westfall et al (1978) showed the release of tritiated purines; Kirkpatrick & Burnstock (1987) have recently demonstrated an increase in ATP on nerve stimulation by the luciferin-luciferase technique. Other work at the department of Physiology, (Leicester University) has also demonstrated ATP release in the mouse vas deferens preparation by the same method. 6 OH-Dopamine abolishes both components so the likelihood is that both adrenergic and non-adrenergic components come from the same adrenergic nerves (Furness, 1970; Kirkpatrick & Burnstock, 1987). There is no evidence of accompanying purinergic nerves (Westfall et al, 1978). ATP and noradrenaline have been

shown to act on the same site post-junctionally, providing different components of the nerve evoked response (Sneddon & Westfall, 1984). All this, when put together does suggest cotransmission. Noradrenaline-ATP cotransmission has been postulated for other tissues, such as dog mesenteric artery (Machaly et al, 1988), rabbit central ear artery (Kennedy et al, 1986), and many others (see Burnstock, 1986, for review).

#### **Y Receptor**

An explanation for the apparent resistance of the initial 'twitch' of the nerve-evoked response to  $\alpha$ -blockers came from Hirst & Neild (1980). They demonstrated a dual population of  $\alpha$ -adrenoreceptors in arteriolar tissue. One population produced only a brief contraction with no change in membrane potential, and was antagonised by  $\alpha$ -blockers. The other population produced EJPs, which occasionally fired an action potential, producing contraction. This last population was not inhibited by classic  $\alpha$ -blockers, and may be situated at a junctional site (Hirst & Neild, 1981). This receptor has been termed the y-receptor (Hirst et al, 1982).  $\alpha$ , $\beta$ -mATP has been shown to block the depolarising effect of noradrenaline on the y-receptor of the rat basilar artery (Byrne & Large, 1986).  $\alpha$ , $\beta$ -mATP also affects the noradrenergic component of the response in the vas (Amobi & Smith, 1987a). Though this is possible, it has yet to be demonstrated in the vas deferens, and fails to explain the apparent residual twitch response after reserpinisation. Further complications stem from the fact that in the mouse the effects of ATP seem of much less importance than in the guinea-pig. Reserpinisation reduces both the component of the biphasic response, whilst prazosin abolishes the initial twitch as well as reducing the secondary component (Stjarne & Astrand, 1985). Amobi & Smith (1987b), working on the rat vas deferens, have suggested an alternative explanation for the biphasic

response. They suggested that the adrenergic response contributed significantly, only to the primary tetanic response, whilst the secondary component was a result of potentiation of the non-adrenergic response by noradrenaline. This was based on the fact that the slow adrenergic phase of the response to a single stimuli decays rapidly with increasing pulses. Exogenous noradrenaline also potentiated the secondary 'non-adrenergic' response. In order to clarify these varying theories we require a specific P2x-purinoceptor antagonist, that will not block the  $\gamma$ -receptor. A recent possible antagonist has been identified in the competitive ATPase antagonist Suramin, which will block the response to exogenous,  $\alpha,\beta$ -mATP (Dunn & Blakeley, 1988).

#### The postjunctional response

The postjunctional response to sympathetic stimulation in the vas deferens is contraction. This response relies on an increase in cytoplasmic calcium from either an intra- or extra-cellular source. The calcium binds to calmodulin, which in consequence stimulates myosin light-chain phosphorylase, and so phosphorylates the myosin filaments allowing contraction to occur (Alberts et al, 1981). This mechanism allows for careful control of contraction and requires less ATP than skeletal muscle.

The receptor for noradrenaline on the vas is the  $\alpha$ -adrenoceptor as opposed to the  $\beta$ -adrenoceptor. It is more sensitive to noradrenaline than isoprenaline, and the effect of noradrenaline is not blocked by propranolol, a  $\beta$ -blocker. Stimulating the  $\alpha$ -adrenoceptor produces a rise in the intracellular calcium levels (Furchgott, 1959; Ambache & Zar, 1970, Burnstock & Costa, 1975). The receptor can be further classified as an  $\alpha_1$ -adrenoceptor on its postjunctional location and antagonism by

Prazosin, a potent  $\alpha_1$  antagonist (Langer, 1974; Dubocovich & Langer, 1974; McGrath 1978). Postjunctional  $\alpha_2$ -adrenoceptors are known to exist in vascular tissue, but do not play a large part in the contractile response of the vas deferens (McGrath, 1982; Long & Stone, 1986). The possibility of further subdividing  $\alpha$ -adrenoceptors, has recently been suggested (McGrath, 1982; Flavahan & Vanhoutte, 1986; Han et al, 1987). At present there is not enough evidence to allow further subdivision of  $\alpha_1$ -adrenoceptors in the vas deferens. It has been suggested that a heterogenous population of  $\alpha_1$ -adrenoceptors may exist in the rat vas (Hay & Wadsworth, 1983a; Amobi & Smith 1987; Han et al, 1987).  $\beta_2$ -adrenoceptors have been found in the rat and guinea pig vas deferens, and mediates an inhibition of excitatory responses on the addition of salbutamol (MacDonald & McGrath, 1980; Lotti et al, 1980). The significance of the  $\beta_2$ -adrenoceptors is unknown, but seems unlikely to play a major role in excitation of the tissue.

$\alpha_1$ -adrenoceptors are known to work via production of Inositol 1, 4,5-trisphosphate (IP3) ( Berridge, 1984; Berridge & Irvine, 1984). The vas deferens produces IP3 on stimulation of  $\alpha_1$ -adrenoceptors (de Scarnatti & Lappetine, 1974; Fox et al, 1985; Minneman et al, 1988). The relationship between receptor activation and production of IP3 is not linear, and there appears to be a large reserve of  $\alpha_1$ -adrenoceptors (Minneman et al, 1984; Minneman et al, 1988). IP3 is produced from phosphatidylinositol 4,5-bisphosphate (PIP2), which is found in the inner leaflet of the plasma membrane. On stimulating an  $\alpha_1$ -adrenoceptor PIP2 is hydrolysed to IP3 and diacylglycerol by means of a phosphodiesterase in the plasma membrane linked to the  $\alpha_1$ -adrenoceptor by means of a G protein. IP3 acts as a second messenger conveying the activation of the  $\alpha_1$ -adrenoceptor to the sarcoplasmic reticulum, from where calcium

can be released into the cytoplasm, possibly producing a contraction (Berridge, 1984; Berridge & Irvine, 1984; Burgess et al, 1984; Michell, 1985). IP3 is the second messenger for almost every process requiring an increase in cytoplasmic calcium (the skeletal muscle relies on depolarisation of the sarcoplasmic reticulum) (Michell, 1975; Berridge & Irvine, 1984). Diacylglycerol also acts as a second messenger activity activating protein kinase C, which can subsequently phosphorylate target proteins. Its role in smooth muscle is still uncertain (Berridge & Irvine, 1984). It has been reported that the sarcoplasmic reticulum shows a localisation at sites of IP3 production, and that calcium release may also be related to this site (Brown et al, 1984; Dawson et al, 1984; Michell, 1985). This might explain the appearance of sarcoplasmic reticulum near the close junctions of the vas deferens (see above).

The intracellular stores are not sufficient for full sustained contraction of smooth muscle, and calcium must be obtained from an extracellular source as well. In the rat vas, stimulation in a low calcium environment produces only a short phasic response in the prostatic half (Hay & Wadsworth, 1983a). Other workers using the same preparation have however shown a sustained tonic contraction in the epididymal half (Ashoori & Tomita, 1983). In human T-lymphocytes IP3 will also activate calcium channels in the plasma membrane, as well as releasing a transient intracellular source of calcium (Kuno & Gardner, 1987). In the anococcygeus noradrenaline causes a biphasic depolarisation. The primary depolarisation is due to an influx of chloride ions, and is secondary to an increase in intracellular calcium (Byrne & Large, 1985; Byrne & Large 1987). McGrath (1982) also reported two possible mechanisms for anococcygeus activity, dependent on intracellular or extracellular calcium. Han et al



(1987) have proposed another mechanism for calcium entry and contraction besides the use of intracellular calcium. They proposed a dihydropyridine-sensitive calcium channel which would be activated by the  $\alpha$ -adrenoceptor. This was based on the effects of the calcium channel blocker nifedipine, in removing a large component of the response to noradrenaline. The process by which this might be achieved is not known. It was demonstrated that IP<sub>3</sub> was not significantly involved in the contractile response mediated by the dihydropyridine channels (Han et al, 1987). This apparent discrepancy might help explain the large receptor reserve observed in the vas, and non-linear relationship of binding to IP<sub>3</sub> production (Minneman et al, 1984; Minneman et al, 1988). Other experiments have shown that although partial agonists may produce only 50% of the mechanical response of a full agonist, they can still produce the same amount of IP<sub>3</sub> (Fox et al, 1985). IP<sub>3</sub> then would not appear to be the sole stimulant for contraction. Hay & Wadsworth (1983a) discovered three apparent mechanisms of calcium-activated contraction. A nifedipine-resistant component, a component resistant to low concentrations of nifedipine, and a component that was not at all resistant to nifedipine. Hay & Wadsworth (1983b), have demonstrated further mechanisms of contraction by examining the rhythmic responses to BaCl<sub>2</sub>, KCl and methoxamine. They show an uneven distribution along the vas, and are blocked by different channel blockers, and at different concentrations. The contractions caused by methoxamine and BaCl<sub>2</sub> are much less sensitive to channel-blockers than the response to KCl. The phasic response to potassium depolarization may be mediated by fast calcium channel activity (Langton & Huddart, 1987). Ionophoretic application of noradrenaline to the vas does not produce a depolarization. Superfusion of the guinea pig vas to noradrenaline produced a very gradual depolarisation (Sneddon & Westfall, 1984). Sodium and calcium

influx are thought to generate the noradrenergic depolarisation (Bulbring & Tomita, 1987). The mechanism by which these channels could work, if not by voltage-gated mechanisms is not known. The resistant element has been demonstrated by many workers in both the response to a single impulse and to exogenous noradrenaline (Blakeley et al, 1981; French & Scott, 1981; Stone, 1981; Brown et al, 1984). McGrath (1985) has suggested that the apparent loss of the nifedipine-resistant component at low external calcium, is due to the uptake of noradrenaline by the nerve terminal. If the receptor mediating intracellular release is at a junctional site the noradrenaline may be taken up by the nerve terminal and may not have time to equilibrate to sufficient concentrations to provoke release before intracellular stores of calcium are depleted. Ashoori & Tomita (1983) also noted a possible intracellular source of calcium-producing contraction. Another idea stems from the increase in phosphatidic acid production on alpha-1-adrenoceptor stimulation in the vas (Takenawa et al, 1983). Phosphatidic acid may form an ionophore in the membrane for passage of calcium (Michell, 1975; Berridge, 1984). The possible subdivision of receptors into those utilising intracellular calcium and extracellular sources, is not merely limited to the vas deferens (McGrath, 1982; Coates et al, 1982; Beckeringh et al, 1984; Byrne & Large, 1985; Jim, 1985). Other examples abound. Hieble (1986) in his review cites canine saphenous vein in which hydroxylated phenylethylamines can activate intracellular calcium release, whilst the unhydroxylated do not (Jim, 1985). Species' differences are also apparent as for instance the potency of D600 (Methoxyverapamil) between the rat and the guinea pig. In the rat it blocks the response to ST587 and Sgd101/75, but has no effect in the guinea pig. It was therefore proposed that the alpha-receptor in the rat has two sites of action (Beckeringh et al, 1985). Opponents to the subdivision of the alpha-1-adrenoceptor suggest that differences are due to a spectrum of

agonist efficacies and affinities controlling a multitude of mechanisms mediated by the alpha-1-adrenoceptor (McGrath, 1985; Hieble, 1986).

Another approach to identifying possible separate subclasses of receptors, has been the comparison of antagonist-binding constants ( $PA_2$  values). Recent reviews on the relative binding affinities to vascular tissue, of prazosin, a potent alpha-1 antagonist, and yohimbine, a potent alpha-2 antagonist, that will bind to alpha-1-adrenoceptors at higher concentrations, have suggested a possible dichotomy in affinities. One receptor having a low affinity for both antagonists (7.8-8.5), the other a higher affinity (greater than 9.0) (Drew, 1985; Flavahan & Van Houte, 1986). Drew (1985) however only separated the two sites on account of their affinities for yohimbine, whilst the values for prazosin produced a full range of values, with poor separation of low and high affinity sites. Other criticism has stemmed from the fact that these pooled values would be liable to variations between laboratories and techniques employed (Docherty, 1987). Han et al (1987) using antagonist equilibrium binding constants for WB4101 and benoxathian antagonising  $^{125}I$ BE binding, found two populations of receptors in the vas with different binding affinities, in the ratio of 1 to 1. In contrast Kenakin (1984) found a homogeneous population of receptors in the vas, with a  $PA_2$  of 9.0 for prazosin, and a slope factor of one. Oxymetazoline, though a full agonist in the anococcygeus, was only a partial agonist in the vas. Kenakin explained this by the high affinity and low efficacy of the agonist. If the coupling between receptor and contraction was not as efficient a partial agonist would be severely affected. Another example discussed by Flavan & Vanhoutte (1987) is an experiment on the rabbit pulmonary artery, in which prazosin proved to be more effective against clonidine than

methoxamine, again implying two sets of receptors for which prazosin has different affinities (Holck et al, 1983). Though the evidence for two subtypes of alpha-1-receptors is large, caution is still advised due to the lack of full understanding of receptor operation and mechanisms leading to tissue responses. With the added problems of co-transmission in the vas deferens and other tissues, the entanglement of the mechanisms becomes even more pronounced. The question must be raised as to why we need so many mechanisms to control apparently the same effect of contraction. Perhaps as was suggested by McGrath, there is only one form of alpha-1-adrenoceptor, but that its multitude of actions depend upon the interactions of the agonist and the receptor (McGrath, 1982; Drew, 1985; McGrath, 1985; Hieble, 1986; Flavahan & Vanhoutte, 1986; Docherty, 1987; Flavahan & Vanhoutte, 1987).

The alpha-1-adrenoceptor has been shown to have a large receptor reserve (Mineman et al, 1983; Fox et al, 1988; Minneman, 1988). Some of this reserve is due to the nature of the vas, in that it is multi-layered organ, so agonists and antagonists will preferentially bind to the outer longitudinal layer. Perfusing the antagonists through the vasculature of the vas produces a much more even distribution and a better estimate of receptor binding. Nevertheless there is still a large receptor pool in the longitudinal layers, and a smaller reserve in the circular layer (Minneman, 1984). Other work has shown a population of silent receptors which play no part in contraction to noradrenaline. Alpha-1 blockade can leave 20% of receptors unblocked, yet still no contraction is observed. This could be due to inaccessibility, or the requirement of some mechanism to activate the receptors (Higuchi et al., 1985). Further vagaries in the distribution of alpha-1-adrenoceptors arise from studies of the half vas,

which demonstrates different sensitivities to noradrenaline in each half (McGrath, 1978; MacDonald & McGrath, 1980). The prostatic half shows a distinct nifedipine resistant population of receptors, and produces a rapid response. The epididymal component demonstrates a nifedipine sensitive population and has a much slower, tonic form of response (Hay & Wadsworth, 1983; Ashoori & Tomita, 1984; Brown et al, 1985). These differences could be due to separate receptor mechanisms, distributed unevenly within cells of each end, or merely a different population of cells, each with separate mechanisms of response. Recently Blakeley et al (unpublished) have identified two different cell populations within the outer layers of the vas that show either high or low resistance between neighbouring cells.

Though little is known of the response to noradrenaline or the possible receptors involved the response to purines is similarly unfathomed. Purinergic receptors are, similarly to adrenergic receptors, divided on the grounds of agonist potencies, such that P1- purinoceptors are defined as having greater potency to adenosine and AMP than ADP and ATP.

P2-purinoceptors showed a reverse order of potency, being more potent to ATP and ADP. P1-purinoceptors show inhibition by methylxanthines and stimulate cAMP (Burnstock, 1978). The processes by which P2-purinoceptors work are still relatively unknown. As we have already mentioned P1-purinoceptors can be subdivided into A1, A2, and possibly A3 (Van Calcar, 1979; Ribeiro & Sebastiao, 1986). P2-purinoceptors can also be subdivided, dependent upon the effect they produce in the tissue. P2-purinoceptors produce a contraction as in the vas (Westfall, 1978; Fedan et al, 1982). Alpha,  $\beta$ -mATP and  $\beta$ ,  $\gamma$ -mATP are more potent at producing

contraction than ATP. The converse is true of P2Y -purinoceptors found in the gut and rabbit portal vein, where ATP is more potent, and produces a relaxation of the tissue (Burnstock, 1985). Whereas P1 receptors have an abundance of antagonists in the form of the methylxanthines, the P2 receptors have very few. The main means of antagonism is via the desensitisation of receptors using  $\alpha$ ,  $\beta$ -mATP, or the non-specific antagonist ANAPP3.  $\alpha$ , $\beta$ -mATP is a less than perfect antagonist, as it also abolishes the supposed 'y' receptor response in the rat basilar artery (Byrne & Large, 1986). Recently however new antagonists have started to appear. Reactive Blue 2 is a selective antagonist for P2Y receptors (Reilly et al, 1987). Suramin has been postulated as a selective P2x antagonist, and as such could be very useful in examining cotransmission in the vas deferens (Dunn et al, 1988).

The response to ATP in the vas deferens, like that to noradrenaline is contraction. It relies on calcium entry into the cell. Originally the EJP produced by sympathetic release at the vas was thought to be mediated by noradrenaline (Burnstock & Holman, 1966), though later it was found to be resistant to blockade by  $\alpha$ -antagonists, and sensitive to purinergic blockade (Sneddon et al, 1982; Sneddon & Westfall, 1984). The EJPs produced by ATP release at nerve evoked stimuli correspond to the depolarisation produced by ionophoretically applied ATP (Sneddon & Westfall, 1984). EJPs may summate on repeated stimulation and reach a threshold to form an action potential, which will depolarise the membrane, activating voltage-gated calcium channels and allowing entry of calcium to provide the stimulus for contraction. The process behind the EJP in response to stimulation at P2x -purinoceptors has been studied in the rabbit ear artery, which produces an EJP similar to that seen in the

vas (Suzuki, 1985). It would appear to involve activation of a non-selective channel for mono- and bivalent cations that produces an inward current so causing a local depolarisation. The latency of the EJP is fairly small (28-72 ms), so it is likely that the receptor and channel are closely linked. It does not require calcium for activation, but could itself carry calcium across the membrane (Benham et al, 1987). Blocking the voltage-gated calcium channels with nifedipine prevents the formation of an action potential, and hence the resultant contraction. The EJPs however are unaffected (Blakeley et al, 1981). Nifedipine blocks the mechanical response to ATP very effectively; it also inhibits the 'non-adrenergic' primary component of the response to a single nerve impulse (Blakeley et al, 1981; Brown et al, 1984; Amobi & Smith, 1987). It must be recalled that the response to noradrenaline is also sensitive to nifedipine blockade (Hay & Wadsworth, 1983). Though the EJP is thought to be mediated by ATP, another contender is noradrenaline acting on the 'y' receptor (Hirst & Neild, 1980, 1981, 1982; Byrne & Large, 1986). Stjarne & Astrand (1984b), have observed a 'slow' EJP as opposed to the 'fast' EJP characteristic of the ATP response. The 'slow' EJP was only partly abolished by reserpinisation, and was resistant to sensitisation of purinergic receptors by alpha,  $\beta$ -mATP, though again it showed a slight decrease in amplitude. The mediator of 'slow' EJPs is unknown.

The post-junctional response to ATP is less than straight forward, and appears to be influenced by a number of factors, which suggests possible multiple sites of purine interaction. The concentration-response curve for ATP is not a straightforward sigmoidal curve but demonstrates a distinct 'kink' (Westfall, 1978; Fedan, 1982). The response to exogenously applied analogues also varies considerably, in both form of the response

and the concentration-response curves. The response is occasionally biphasic, in general though it consisted of a rapid phasic response, occasionally followed by a more tonic response or subsequent phasic responses. The concentration-response curves were often non-sigmoidal, and occasionally 'bell-shaped'. From this it would seem that some analogues became inhibitory at higher concentrations. The wide range of responses must suggest multiple interactions of agonist whether with purinergic receptors or other systems. The role of ATP in co-transmission may well be more complicated than a mere production of EJPs and subsequent contraction (Fedan et al, 1982a, b, 1986).

There is some evidence for further roles of purines in the vas deferens. Holck and Marks (1978) reported that adenosine and AMP could augment subsensitive adrenergic receptors in the guinea pig, promoting resensitisation, whilst ATP depresses the noradrenergic response. In the rat adenosine potentiated the response in the prostatic half, but retarded recovery and resensitisation, though not in the presence of yohimbine which blocks alpha-2-adrenoceptors (Long & Stone 1986). Amobi & Smith (1987) have suggested that noradrenaline potentiates the response to ATP in the secondary phase of the tetanic response, producing a synergistic reaction. The likelihood of purines and noradrenaline interacting seems very probable, though the nature of this interaction may be hard to disentangle if we consider the large numbers of possible mechanisms and receptors involved. To disentangle them we need specific antagonists for each of the possible receptor subtypes.



So far we have discussed only the properties of a single cell and the mechanism causing its contraction. Smooth muscle cells often produce a syncytium of cells that interconnect, and provide a means of rapid conduction of action potentials through the tissue, such that individual innervation of each cell is not required (as in the guinea-pig, see above) (Tomita, 1970; Burnstock, 1970). More recently Blakeley et al (unpublished) have observed two populations of smooth muscle cells in the vas with different membrane potentials and input resistance. Those cells with high input resistance and lower membrane potential were electrically isolated from other cells, and failed to transmit action potentials. This arrangement may be explained by the high density of innervation, and consequent lack of requirement for electrical spread and cable properties. The mechanisms producing contraction in the vas deferens, and the possible modulatory effects of the cotransmitters, are not yet fully understood, and require further study to elicit their possible roles. Most experiments are performed *in vitro*, so are forced to ignore many of the other factors controlling tissue functioning *in vivo*. The nature of any neuronally co-ordinated action of the vas is unknown. Experiments *in vitro* can only hope to uncover possible mechanism of transmission and neuromodulation.

## Chapter 10

### Vas Deferens Contractility and Sperm Transport

The prime function of the vas deferens is to transport sperm. The anatomists usually refer to the vas as the ductus deferens implying it's main function. As discussed in the preceding chapters to enable the vas deferens to perform this function, the vasa have a very thick circular muscle surrounded by an inner and outer longitudinal muscle, with specialized pseudocilia of its columnar epithelium.

It is the only tubular structure in the body that has a lumen with a diameter that is smaller than the thickness of its wall. Furthermore the vas deferens has a very dense adrenergic innervation of its muscle. Accompanying the vas deferens is also an extensive venous and capillary bed network, which may be involved in stiffening the tissue during ejaculation, so aiding flow (Hamilton & Cooper, 1978).

### Sperm Transport Hypothesis

Several hypotheses have been proposed recently to explain the mechanism by which the spermatozoa are transported away from the epididymis (Batra 1974). These are summarised as follows.

#### Van Welkenhuyzen's Hypothesis

Van Welkenhuyzen (1966) studied the motility of animal and human vas deferens in vitro. The vas specimens showed spontaneous local or global contractile waves of varying amplitude and frequency; this activity started

immediately or after several minutes of adjustment to the solution and lasted for periods of minutes or hours. Addition of adrenaline or acetylcholine promoted this activity, but no systematic patterns of influence could be inferred. Van Welkenhuyzen considered the spontaneous activity accidental and unrelated to sperm transport. In in vivo experiments the two extremes of the vas deferens of an anaesthetized rabbit were cannulated, and the vas was ligated gently to the inserted ends of the tube cannulas so as not to constrict blood flow to the tissue. Other ends of the cannula were attached to a Marey ampulla, through which the cannulas and the vas could be filled with Locke's solution. The pressure was controlled by the fluid column height, and the vas was clamped in the middle so that the fluid and the two halves were separated without constricting the flow of blood. The contraction, stimulated by polar excitation electrodes at the urethral end, travelled toward the epididymal end, causing a pressure increase in both sides of the vas. On the other hand, the contraction stimulated at the epididymal end did not propagate toward the urethral end; thus the pressure increased in the epididymal half only. It was concluded that there is a functional orientation in the vas. From the electrical activity of the smooth muscle of the vas in vivo it was inferred that hypogastric nerve stimulation results in flow of the activation potential from the urethra to the epididymis and that the vas smooth muscles behaved predominantly as multi-units. Thus vas contraction starts at the urethral end, spreads towards the epididymis, and induces a rapid rise in pressure inside the vas. Since the contents cannot escape toward the epididymis due to the sphincter closure, the flow occurs towards the posterior urethra. This emptying process occurs only once with each ejaculation. Re-filling of the vas occurs passively. Presence of a sphincteric system of ejaculatory ducts prevents the vas from emptying into the posterior urethra, except during ejaculation.

### Pabst's Hypothesis

Pabst (1969) cites the suggestion of Niemi (1965); that is, since the vas epithelium resembles that of the epididymis, their functions may also be similar, and therefore the sperm must be stored in the epididymis as well as in the vas before ejaculation. Also, Nikolowski's clinical findings (1962) suggest that the sperm maturation is carried out not only in the epididymis but also in the vas; Boeminghaus (1957) and Holstein (1969) found varying quantities of spermatozoa in sections from vasectomies, while Oettle (1954) found large quantities of spermatozoa in the vas deferens of young men 1-2 hours after death. In addition, Amann et al (1963) created a fistula in a bull vas and continually collected substantial quantities of sperm every day over an extended period of time. Thus there is the possibility of constant sperm flow from the cauda epididymidis to the vas deferens and ampulla, and the implication that such transport does not occur only at ejaculation. Pabst suggests that constrictions develop in the cauda epididymidis that prevent backflow from the vas deferens. Reference is made to the observations of Mitsuya et al (1960) using X-ray cinematography. During the excitement stage, the vas convolutions and limpness are lost. The vas becomes taut and is pulled toward the vesicles (Van Welkenhuyzen's contractile wave, starting at the urethral end and propagating toward the epididymis, may be associated with this phenomenon). During the pre-ejaculatory stage the vesicles become tense, and their peristaltic movement starts. Then the vas image is diminished quickly, followed by the disappearance of the ampulla image; their contents are poured into the posterior urethra through the ejaculatory ducts while the seminal vesicles, if not full already, are filled in the process. When the discharged material in the posterior urethra reaches a certain volume, the external sphincter opens to propel the semen

into the distal urethra. At this time, even contraction and peristaltic movement are visible in the vesicle wall, with an up and down motion of the proximal portion of the ejaculatory ducts; the contents of the seminal vesicle are discharged into the posterior urethra rapidly and periodically. Contractions of the seminal vesicles occur from 7 - 10 times in one ejaculation. The terminal stages of ejaculation are characterised by vesicle relaxation; the significant amount of material left in the vesicle begins to diffuse, and some displacement is observed toward the distal portions.

Pabst's hypothesis for sperm transport involves three major points:

- (1) Spermatozoa are continuously transported into the vas deferens and therefore the sperm are in the vas before ejaculation.
- (2) The emission stage consists of (a) the start of the contractile wave from the urethral to the epididymal end, (b) lumen contraction at the epididymal end to prevent backflow of semen, (c) increase in fluid pressure, and (d) a powerful reflux action of the muscles transporting the fluid into the ampulla.
- (3) The ejaculation.

#### **Baumgarten-Holstein-Rosengren Hypothesis**

Baumgarten et al (1971) maintained that the muscle coat of the ductuli efferentes and epididymis upto the proximal cauda (scarcely and randomly innovated), together with its smaller contractile cells, has a different motility behaviour than that of the vas with it's large, densely innervated smooth muscle. Spontaneous, local, slow, rhythmic, migrating contractions, sometimes resembling peristaltic movements, are observed under resting conditions in vivo. On the other hand, the vas was observed to be quiescent unless involved in a nerve-mediated, brief,

forceful reflex contraction. This difference in behaviour is believed to be largely a function of the difference in outer structure of the smooth muscle cells in the two regions. It is thus possible that the ductus epididymidis is adapted for continuous, slow transport of fluid from the testis to the sperm reservoir (the distal quarter duct and the vas). This permits maturation of the spermatozoa in the upper epididymis, storage in the lower epididymis, and expulsion of the fluid by a powerful, short, adrenogenically-mediated contractions of the distal, cauda epididymidis/vas deferens during the ejaculation.

#### Ventura-Freund-Davis-Pannuti Hypothesis

The hypothesis of Ventura et al (1973) regarding the mechanism of sperm transport by the vas is based on observations of spontaneous motility of the human vas deferens in vitro. Specimens were obtained from cadavers and from vasectomy patients under general, spinal, and local anaesthesia. Specimens in general showed spontaneous motility. The motility behaviour of cadaver specimens, depended on their location (proximal, central, or distal). The force of contraction was smallest in the proximal segment and largest in the central segment; the duration of the contraction was briefest in the central segment and generally most prolonged in the proximal segment, and the frequency of contraction was lowest in the proximal segment, and highest in the distal segment. Increases in the frequency of contractions from proximal to central to distal segments were designated as the rhythmicity gradient. The constant infusion of noradrenaline produced a marked increase in the contraction force, but the rhythmicity gradient was maintained. Thus Ventura et al (1973) proposed that intrinsic rhythmicity of the human vas depends on the local

concentration of noradrenaline, while the powerful and co-ordinated series of contractions that propel the sperm from the epididymis to the urethra during ejaculation are initiated and controlled by the release of substantial amounts of noradrenaline.

Specimens obtained under local anaesthesia from vasectomy patients showed no spontaneous motility; specimens from vasectomy patients under general and spinal anaesthesia also appeared to be somewhat impaired compared to the motility of cadaver specimens. The innervation of the vas deferens may be damaged seriously by the local anaesthetic and perhaps less seriously by spinal or general anaesthesia. Thus if the fluid transport through the vas is based on the rhythmicity gradient, it is conceivable that the relative success of vaso-vasostomy depends on the type of anaesthetic agent employed during vasectomy and subsequent re-anastomosis.

#### **Appraisal Of The Hypothesis**

Van Welkenhuyzen's hypothesis is based on (1) the study of electrical activity of the vas smooth muscle after stimulation of the hypogastric nerve, and (2) in vivo observations of pressure increase in the two halves of the vas, filled with Locke's solution and constricted in the middle, that was induced by stimulation at either end. Since the vas innervation comes from three different sources (the inferior hypogastric, middle gonadic, and inferior gonadic nerves), it would seem necessary to identify the role played by each. Van Welkenhuyzen's experiments have identified some of the influences of the inferior hypogastric nerve. It is questionable, however, whether an hypothesis can be based on neurotransmission behaviour alone until corresponding results for the

influence of stimulation of the inferior and middle gonadic nerves are also clarified. Moreover, from a hydrodynamic point of view, it is difficult to conceive how a purely longitudinal contractile wave originating at the urethral end and travelling toward the epididymis can provide momentum to the fluid in the opposite direction. Clearly, additional information on the mechanical stimuli at work in the vas must be obtained.

Estimates of the fluid volume in the vasa and ampulla tend to support the contention that a single reflex of the vas delivers the sperm to the posterior urethra. On the other hand, Freund & Davis data (1969) before and after vasectomy suggest that 60-70% of the sperm in a normal ejaculate must come from the epididymis and proximal part of the vas and that these sperms are contained in 50-60% of the total ejaculate volume. Thus Freund & Davis' data contradict Pabst's contention that a single reflex of the vas is associated with each ejaculation. The conflict may be resolved by the postulation of a peristaltic mechanism for sperm transport through the vas (Batra, 1974). Sperm transport through the pig oviduct occurs by the peristaltic mechanism (Blandau & Gaddum, 1974). The data of Freund & Davis (1969) showed that on an average 1.4 ml of the total ejaculate volume of 3.18 ml comes from the epididymis and the proximal part of the vas. The dimensions of vas and ampulla suggest that both sides of the vas together can store at most 0.56 ml of fluid. Thus the single reflex concept during emission stage cannot hold. The relative degrees of innervation of the epididymis and the vas suggest that the driving force comes predominantly from the vas. The most feasible alternative is therefore the peristaltic pumping by and through the vas.



The hydrodynamics of peristaltic pumping have been analysed for simple geometric wave shapes (Shapiro et al, 1969; Burns & Parkes, 1967). Influence of the mechanical properties of the tissue material (in the active and passive phases) has been lumped into the choice of the geometric shape of the peristaltic wave. Based on the results of this analysis, Batra (1974) has shown that the required quantities of the sperm-containing fluid could be delivered by the vas in as short a time as 12 seconds. Such a time period is physiologically quite realistic and supports the feasibility of peristaltic pumping of the sperm transport mechanism. Moreover, the peristaltic mechanism does not require a complete emptying of the vas for each ejaculation. This could explain the presence of sperm in several ejaculates after vasectomy (Freund & Davis, 1969). As well as the diminishing of the vas image in X-ray cinematography (Mitsuya et al, 1960). It would therefore be helpful to develop a quantitative model of flow to take into account the three-layered structure of the musculature. Such a model would require knowledge of the rheological properties of the seminal fluids and the mechanical properties of the musculature of the wall in the passive as well as in the active state.

#### **Mechanical Characterisations Of The Vas Deferens**

Mechanical characterisations of the vas deferens have been reported by Krepchin et al (1974) in the passive state and by Lau et al (1974) in the active state. The passive state experiments were carried out on rabbit and rat vasa. Typical load-elongation data (average curves, rat) were obtained at different rates of elongation. Although variability is typical of biological tissues, the load-elongation curves demonstrate characteristic curves at the lower rates of elongation (0.5 cm/min) are less stiff than those at higher elongation rate (12.5 cm/min). Such behaviour is typical of the

time-dependent visco-elastic materials. The visco-elastic behaviour of the rat vasa was further investigated in stress-relaxation experiments in which the vas specimen was extended rapidly to a certain stretch or force level and held at the new length; decay of the forces monitored as a function of time.

Visco-elastic phenomenon in the material are an indication of the presence of energy dissipation mechanisms at some level of molecular structure. Another manifestation of the energy dissipation can be observed in the hysteresis phenomenon associated with cyclic loading-unloading experiments. In the experiments performed, rat vas specimens were extended several times to a fixed level of stretch and then allowed to recover (the extension) at a fixed rate; force in the specimen was monitored during each cycle (Krepchin et al, 1974).

Active-state experiments were also carried out under field stimulations (Lau et al, 1974). The threshold voltage was found to be associated with the active response of the specimen; a maximal response under isometric conditions was obtained with alternating current stimulation at 60 Hz, 5 volts for 2 seconds at 37 degrees centigrade. The degree of initial stretch influenced the extent of maximal force induced but not the required stimulation parameters. Influence of the initial stretch on the active force induced was studied through quasi-isometric contraction experiments (Lau et al, 1974). This procedure was necessary in order to eliminate the influence of the visco-elastic effects. The active force (versus stretch) showed a hill-valley-plateau characteristic in the extension phase and a relatively constant force in the stretch recovery phase of the experiments. The mechanical properties discussed previously are associated with the length and direction of the vas. The three-layered structure of the vas

suggests that both the passive and active properties measured in these experiments can be associated with the inner and outer layers of the musculature, which are orientated longitudinally. Since the smooth muscle structure is known to be the same in all three layers, it appears reasonable to suggest that the musculature of the middle layer, orientated circumferentially, would behave in a similar fashion.

## Chapter 11

### The Immunological Consequences Of Vas Damage

Approximately 10-20 per cent of infertile couples have unexplained infertility; as demonstrated by normal semen analysis in the man and regular ovulation, patent fallopian tubes and normal post coital test in the woman (Pepperell 1985; Templeton 1982). Immunological factors may be responsible for a number of cases of unexplained infertility. Let us now consider the immunological consequences of vas damage. Any vas damage can lead to outflow obstruction and this can produce an immunological reaction.

The pathogenesis of immunity to sperm is still not clear. Mature sperm cells appear first in the male subject at puberty, long after the development of immunocompetence and tolerance to "self" antigens. Since spermatozoa express antigens that are foreign to the immune system their immunogenicity is not surprising. Sperm normally are sequestered from the immune system by a blood-testis barrier formed by the tight junctions of Sertoli cells in the seminiferous tubules (Gilula et al. 1976) and epithelial cell barriers elsewhere in the male reproductive tract (Anderson & Alexander 1979). The actual mechanism of autoantibody formation in man and in other animals (rat, rabbit, guinea pig, ram, rhesus monkey) is not certain but likely to be due to extravasation and release into the blood circulation of spermatozoal antigens, possibly similar in kind to the antigens responsible for autosensitization resulting from autoallergic orchitis or traumatic injury to the testis (Mancini 1976; Tung 1978). These antigens probably stimulate the reticuloendothelial system directly and induce the production of antibodies against spermatozoa. Disruption of

the blood-testis barrier by vasectomy has been associated in many men with the formation of antibodies to sperm, presumably owing to sperm antigen leakage (Linnet 1983). Other processes, such as trauma, inflammation or irradiation of the testes, or obstruction of the tubules or ducts of the male reproductive tract, similarly might stimulate antisperm antibody formation (Jones 1982). This might occur either by increasing the permeability of the male reproductive tract to immunocompetent cells or by allowing the passage of sperm antigens through the blood-testis barrier. After experimental vasoligation in animals, testicular lymph and regional lymph nodes consistently contain spermatozoa (Ball & Setchell, 1983), and spermatozoa have been found in a para-aortic lymph node one year after vasectomy in a man undergoing laparotomy (Ball et al. 1982). Therefore it is not surprising that antisperm antibodies develop in the serum of 60-80% of men following vasectomy (Hellema and Rumke, 1978; Rose and Lucas, 1979). It is, possible that in certain cases the antibodies formed after vasectomy can give rise to systemic disorders away from the surgical site, such as lymphadenopathy, arthropathy and thrombophlebitis. The evidence available at present for such disorders is weak, and especially the occurrence of circulating HLA lymphocytotoxic antibodies in vasectomized men has been questioned (Jennings et al. 1975). For further reference to immunological consequences of vasectomy several publications are listed: Alexander 1976, 1977b; Alexander and Anderson 1979; Alexander and Clarkson 1978; Alexander et al. 1974; Ansbacher 1973; Bigazzi et al. 1977; Friberg 1974; Gupta et al. 1975; Hekman and Rumke 1974; Quinlivan et al. 1975; Rumke et al. 1974; Rumke 1972; Shulman et al. 1972.

Controversy however does surround immunological infertility in the male subject. Some men who have undergone vasectomy do not acquire autoantibodies to sperm (Linnet 1983). In contrast, many infertile men

have antisperm antibodies but they have no known history to explain sperm extravasation across the blood-testis barrier (Jones 1982). Furthermore agglutination of human spermatozoa by blood plasma has been known to persist for several years even after successful surgical recanalization. Similar antibodies have also been frequently encountered in the blood plasma of men whose deferent ducts have failed to develop during embryogenesis. They can also occur sometimes in the blood and semen of certain infertile, mostly oligozoospermic men who have never undergone any surgery on the vas. The relevance of the quantity, rate and type of antigen exposure, as well as the variation in the immune response among individuals is undetermined to date. For all these reasons many investigators regard the circulating sperm antibodies as a potential but not absolute risk to male fertility.

#### **Effects of antisperm antibodies on fertility**

Antisperm antibodies can occur in men with normal or low sperm counts, and it is evident that these antibodies can interfere with the fertilising capacity of the spermatozoa by preventing them from penetrating cervical mucus. The incidence of antibodies at titres likely to interfere with fertility has been reported by a number of centres to be in the region of 7 % (Hargreave, 1982). Rumke et al. (1974) studied this question by following men who had normal sperm counts and positive serum agglutination tests for 10 years. Almost half of the men with serum titres of less than 32 produced pregnancies, whereas there was a progressive decline in fertility as the antibody titre rose above this level. Fjallbrant (1968) compared fertile and sterile men, and showed a strong negative correlation between the concentration of antibodies and the ability of sperms to penetrate ovulatory cervical mucus, and observed that the interrelation between

sperm penetration ability and subsequent fertility was very good. Estimates of the incidence of antisperm antibodies in men vary. The incidence of antisperm antibodies in fertile men presenting for vasectomy was 2%, compared with 13.4% in subfertile men (Halim and Antoniou, 1973).

The distinction between antisperm antibodies in serum (IgG) and in seminal plasma (IgA) is important because they do not always occur together, and because a blood test can only detect serum antibodies whereas it is the seminal plasma antibody which interferes directly with fertility (Price et al. 1984). Several mechanisms have been proposed and they may work together. They include immobilisation of sperm in mucus ( Kremer and Jager 1980); stimulation of complement mediated cell lysis (Bronson et al. 1982) or phagocytosis by macrophages ( London et al. 1985); interference with capacitation or acrosome reactions (Bronson et al. 1983); and defective interaction with the ovum (Mandelbraum et al. 1987). Antibodies directed against sperm heads appear to affect all of these functions, whereas antibodies against tails only weakly affect mucus interactions ( Bronson et al. 1982a).

About one-third of subfertile men with antisperm antibodies have oligozoospermia (Rumke and Hellings, 1959), but it is not clear whether the antibodies caused the low sperm count (Rumke,1981). Certainly immune orchitis can be induced experimentally in animals (Waksman, 1959) and man (Mancini et al. 1965). The main sites affected are the head of the epididymis, which becomes plugged with polymorphonuclear leucocytes, and in and around the rete testis, where mononuclear cells infiltrate the interstitium, although infiltration of the seminiferous tubules is uncommon. This is considered to be because the rete testis and epididymis are the weakest points in the blood-testis barrier (Brown and

Glynn, 1969). Thus there may be a cell-mediated component of the antisperm antibody reaction in subfertile men resulting in partial blockage to sperm flow in the efferent passages, which could contribute to the infertility by producing oligozoospermia.

#### Consequences of unilateral vas obstruction

Rumke and Titus (1970) showed that unilateral vasectomy led to antisperm antibody formation in rats, and Hendry (1982) reported on 32 infertile men with unilateral testicular obstruction, of whom 80% had such antibodies and 50% were severely oligozoospermic. However Bedford (1976) reported normal fertility in 7 rats and 2 rabbits more than one year after unilateral vasectomy. Silber (1986) has also commented on normal human fertility following unilateral obstruction.

Further animal work by Kessler et al. (1985), using inbred DBA/IJ mice, which are known to be high antibody formers, resulted in unilateral vasectomy consistently inducing an antisperm antibody response and significantly reduced fertility, whereas sham operation or unilateral orchiectomy did not. Furthermore, Alexander (1973) has shown that in guinea-pigs, a species vulnerable to autoimmune hypospermatogenesis, unilateral vasectomy resulted in impaired spermatogenesis on both the operated and the contralateral, unoperated side. Rumke (1965) reported that 6 of 64 men with sperm - agglutinating antibodies in their serum had had a prepubertal herniorrhaphy. Friberg and Fritjofsson (1979) presented 10 infertile men with sperm-agglutinating antibodies in their serum and a history of inguinal herniorrhaphy. In 5 of these men the vas deferens was occluded at the site of herniorrhaphy and in 3 others there was the presence of spermatoceles. Subsequent vas repair and removal of the



spermatocoeles failed to lower the antibody titre and none of the wives became pregnant. Hendry (1986) on investigating 80 infertile males with unilateral testicular obstruction found 76% and 65% to have raised agglutinating antibodies in serum and seminal fluid respectively. Following surgical reconstruction with prednisolone therapy where indicated by high antisperm antibody titres, 19 (32%) of 60 patients successfully impregnated their female partners. Removal of irreparably blocked testes in 10 men led to profound falls in high antisperm antibody titres, with production of 2 pregnancies.

In bilateral vas damage the reason of sterility are obvious, however, if only one vas is blocked immunological response may be relevant. There appears to be a higher incidence of antisperm antibodies in men with unilateral compared to bilateral vas damage (Parkhouse & Hendry 1991). It is known that the formation of antibodies to spermatozoa is less common with congenital obstructions than with acquired post pubertal blocks (Hendry et al. 1983; Patrizio et al. 1989). There is a possibility that there are a number of men with unilateral blocks acquired in childhood who have not developed antibodies and are fertile (Kumar et al. 1989).

In patients with unilateral testicular obstruction, fertility may be improved by a combination of surgical and medical management and removal of the obstructed testis to reduce the antigenic burden. Patients with bilateral obstruction have a poor prognosis, and the underlying cause of infertility does not appear to be primarily immunological. It is possible that the antigenic stimulus is small in cases of bilateral obstruction as a consequence of reduced spermatogenesis associated with failure of germ cell maturation (Friberg & Kjessler, 1975).

It appears therefore that it is important to recognize that unilateral vas damage can seriously impair fertility and on its establishment can be treated. The incidence of this complication is probably substantially higher than previously suspected, leading to infertility only when damage is bilateral or associated with high antibody titres.

#### **Sympathetic Orchio-pathia**

The damage to the contralateral testis following unilateral torsion has been named as sympathetic orchio-pathia (Wallace et al. 1982), because there is no evidence of an inflammatory reaction and therefore an autoimmune aetiology is suggested. This contention has been supported by the demonstration of increased titres of antisperm antibodies in the serum of rats undergoing experimental torsion when compared with controls (Harrison et al., 1981; Lewis-Jones et al., 1982; Thomas et al., 1984). Several authors have shown that fertility may be impaired following prolonged unilateral testicular torsion, not treated by orchiectomy (Krarup, 1978; Bartsch et al., 1980; Mastrogiamo et al., 1982). Experimental studies on several species of animals have demonstrated that unilateral testicular damage, performed in a variety of ways, can result in changes in the contralateral testis which produce impaired fertility (Merimsky et al., 1982), defective sperm production (Kaya and Harrison, 1975; Chakraborty and Jhunjhunwala, 1982) and focal changes of allergic orchitis (Collazo et al., 1972).

Wallace et al. (1982) on studying the contralateral testis of the Wistar rat following unilateral ischaemia, found no evidence of any morphological changes of experimental allergic orchitis nor of a cell mediated reaction. The blood testis barrier was intact but production of mature spermatozoa measured by Johnsen score counts was impaired in all experimental

groups. No fertility studies however were carried out. Their clinical experience of 5 patients in this study showed no benefit of orchidectomy in terms of sperm counts or serum TAT antibody titres. This contradicts the subsequent experience as reported by Parkhouse and Hendry (1991) that a testis badly damaged after torsion or a difficult orchidopexy should be removed and not returned to the scrotum as it removes the antigen origin. The mechanism of damage therefore remains obscure to date.

## Chapter 12

### Obstructive lesions of the male genital tract

Obstruction of portions of the conducting system in the male genital tract is a frequent cause of sterility (Young, 1970a). Vas deferens damage such as in advertent stripping, crush injury, external compression from a suture, ischaemia will all cause obstruction. In this context it is worth considering other causes and prevalence of obstructive lesions of the male genital tract.

Azoospermia is the complete absence of spermatozoa from the semen. It should be remembered that it is possible for a patient to have azoospermia due to a unilateral obstruction in the presence of contralateral testicular atrophy or other lesions. Patients with a complete obstruction present with azoospermia but there is increasing evidence that obstructive lesions can be incomplete and initially can be a cause of oligozoospermia (Jequier et al, 1983). There is no universal classification of azoospermia and the older concept of primary testicular failure refers to the abnormality being one of intrinsic failure of the testis rather than an extrinsic factor such as pituitary failure.

In 1972 Franchimont et al. and de Kretsner et al. demonstrated that plasma FSH levels were higher in patients without spermatogenesis and suggested that this was concomitant with spermatogenesis not proceeding beyond production of spermatocytes. The association between elevated levels of plasma FSH and a gross impairment of spermatogenesis is of basic importance in the management of azoospermic men. A classification based upon plasma FSH levels and the histological appearances of the testis; and associated factors is shown in Tables 12.1 and 12.2 respectively (Pryor 1983).

**Table 12.1      Classification of azoospermia based upon the plasma follicle stimulating hormone (FSH) level and the histological appearance of the testis**

1.      Plasma FSH level elevated
  1.      Anorchism, cryptorchidism
  2.      Klinefelter's syndrome
  3.      Germinal aplasia, Sertoli-cell-only syndrome
  4.      Testicular atrophy/focal sclerosis
  5.      Hypergonadotrophic hypogonadism
  
2.      Plasma FSH level 'normal'
  1.      Spermatogenic arrest  
          (hypogonadotrophic hypogonadism)
  2.      Normal spermatogenesis

**Table 12.2      General conditions associated with azoospermia (can be reversible in some cases)**

1.      Genetic disorders  
         Klinefelter's syndrome  
         intersex problems
2.      Congenital disorders  
         cystic fibrosis  
         myotonia dystrophica  
         bronchiectasis
3.      Hormonal defects  
         pituitary  
         adrenal  
         thyroid
4.      Severe systemic illness or malnutrition
5.      Infection  
         mumps  
         smallpox  
         bilharzia
6.      Drug therapy  
         cytotoxic drugs
7.      Irradiation
8.      Iatrogenic  
         inguinal surgery eg. herniotomy  
         scrotal surgery

The clinical classification of obstructive lesions is given in Table 12.3 and the aetiological factors subsequently discussed.

**Table 12.3 Clinical classification of Azoospermia with normal serum FSH**

Site of obstruction	Symptomatic/Asymptomatic	Spermatogenesis	Vasogram	Aetiological factors
Empty epididymis	Asymptomatic	Normal/absent or impaired	not required	Sertoli cell only maturation arrest immune orchitis
Caput epididymis	Asymptomatic	Normal	Normal	Usually Young's syndrome
Cauda epididymis	Asymptomatic	Normal	May be abnormal	Post-infective
Blocked vas	Asymptomatic	Normal	Abnormal	Traumatic infective
Absent vas	Asymptomatic	Normal	Not possible	Congenital
Ejaculatory duct	Symptomatic	Normal	Dilated	Congenital traumatic

Asymptomatic obstructive lesions may be sited anywhere from the seminiferous tubules up to and including the ampulla of the vasa deferentia (Jequier 1986). These peripheral obstructive lesions will therefore exclude from the ejaculate only the testicular and epididymal contributions to the semen. Obstructive lesions at the sites between the ampulla of the vas and the ejaculatory ducts on the verumontanum tend to be symptomatic. Obstruction at these points will exclude the seminal vesicular contribution to the ejaculate resulting in a substantial reduction in seminal volume and the absence in the semen of the chemical constituents of the seminal vesicular secretions. Such reduction in

seminal volume may be noticed by the patient. Also the contraction of the seminal vesicles against an obstruction can cause pain at emission. In older men with prostatic hypertrophy, prostatic secretions may also be excluded from the ejaculate.

#### **Aetiology of testicular obstruction**

##### **Sites of obstruction**

The epididymis is by far the most common site of the obstructive lesions causing azoospermia. Obstructive lesions in other sites including the vasa deferentia are rare causes of infertility. However, these obstructive lesions can occasionally occur in any site along the genital tract and it is of value to consider these sites individually.

##### **Intratesticular obstruction**

The site of the obstruction can be within the testis itself. The exact nature and site of the obstruction within the testis is, for the most part, unknown as it is not feasible to remove the testis in order to find this site. It is theoretically possible for the obstruction to involve the seminiferous tubules themselves as suggested in the hypercurvature syndrome (Averback & Wright, 1979). But an image-analysing computer system is required to make such a diagnosis on a testicular biopsy. It is also possible that the obstructive lesion may reside in the straight tubules or the rete testis itself (Guerin et al, 1981). Whether the condition known as intratesticular obstruction is in fact a tube obstruction or that this condition is simply due to failure of sperm transport through the testicular ductal system is unknown.



### **The hypercurvature syndrome**

This was first described as a cause of obstruction in 1979 by Averbach & Wright. In a method involving the use of computer-imaging of testicular biopsies, it was demonstrated that obstruction due to the presence of excessive curvature of the seminiferous tubules could cause obstruction. The transport of spermatozoa out of the tubules themselves may therefore be impeded, resulting in a functional if not an actual intratesticular obstructive lesion. However, whether this is, in reality, a cause of infertility in men still remains to be proved.

### **Epididymal obstruction**

In patients with obstructive azoospermia more than two-thirds of the lesions occur in the epididymis which is therefore by far the commonest site for this problem to occur. These lesions involve the duct at or near to the junction of the caput and corpus of the epididymis. This type of upper epididymal obstruction would appear to be the commonest site in patients whose obstructive azoospermia is associated with chronic chest disease. Infective causes of epididymal obstruction can involve more than one area of the epididymal duct, as well as the vas deferens and thus multifocal site of obstruction may be present. As at vasography, it is not possible to inject the contrast medium any distance into the epididymal duct; epididymal duct obstruction cannot be diagnosed by vasography. The only sure way to diagnose this condition is by surgical exploration.

### Empty epididymis

In most of these cases, there is absent or impaired spermatogenesis which has not been reflected by elevation of serum FSH levels; occasionally there is gonadotrophin deficiency which may respond to medical therapy. Rarely, there is normal spermatogenesis associated with very high antisperm, antibody titres (1024 or greater). Testicular biopsy may show focal, mononuclear cell infiltrates indicating that this is a form of autoimmune orchitis, which may respond to prednisilone therapy (Hendry, 1988).

### Caput epididymis

This is a common site of obstruction.

### Chronic chest disease

Chronic chest disease is closely related to obstructive azoospermia; in 1970 Young described a triad of disorders which has since become known as Young's Syndrome, but more correctly should be called the Berry-Perkins-Young Syndrome. This syndrome is made up of chronic sinusitis, bronchiectasis and obstructive azoospermia. It should be remembered however that there are many patients who had bronchiectasis and obstructive azoospermia in the absence of chronic sinusitis and there is a high incidence of other chronic respiratory problems in patients with obstructive azoospermia. It is also of interest that in young male patients with cystic fibrosis, obstructive azoospermia is the rule and is usually associated with the total obliteration of the vas deferens (Holsclaw, 1969). The distension of the epididymal tubules is confined to the heads of the epididymis and light microscopy shows that this coincides with the ductuli efferentes, where the epithelium is ciliated; the tubules are filled

with inspissated masses of spermatozoa and lipid. Electron microscopy shows that the cilia have normal 9+2 arrangement of microtubules and dynein arms are present (Hendry et al, 1978). Lung mucociliary clearance is impaired (Pavia et al, 1981), even though ciliary beat frequency measured by the technique of Rutland & Cole (1980) is normal. Despite intensive further studies, the aetiology of Young's Syndrome remains obscure. The ciliated columnar epithelial lining of the ductuli efferentes is similar to the lining of the nasal and respiratory passages. Since the cilia are ultra-structurally normal in Young's Syndrome, with normal beat frequency, increased viscosity of the fluid within the tubules seems the most likely explanation for the demonstratively impaired mucociliary clearance. Fat stains have revealed excess neutral lipid in the epithelial cells and in the lumina of the ductuli efferentes. Comparison with normal epididymes shows that this is abnormal in young men although it is seen increasingly often in older men (Hendry, 1990). Hence in Young's Syndrome there is abnormal accumulation of lipid, leading to impairment of flow in the ductuli efferentes and respiratory passages. In Hendry's study (1990) there was a definite past history of Pink Disease (mercury intoxication) in childhood in 10% of patients with Young's Syndrome. The relatively common occurrence of Young's Syndrome in England and Australia where Pink Disease was quite common up to 1955 when mercury-teething powders were withdrawn and the virtual disappearance of Young's Syndrome in men born after this date make it possible that mercury intoxication in childhood may have had a part to play in its aetiology as well. By contrast, Young's Syndrome is rare in the U.S.A. If the hypothesis connecting Young's Syndrome with mercury intoxication is correct, this condition should disappear (Hendry, 1990).

### **Cauda epididymis**

This is the appearance commonly seen following infection, which may be gonococcal or chlamydial, due to urinary infection or smallpox, or associated with a variety of unusual conditions such as Sandfly Fever or Bornholm Disease. Typically, the tubules within the epididymis are uniformly distended down to its tail. Of course, a similar appearance is seen when the vas is blocked, causing back pressure on the epididymis, and a vasogram is mandatory to ensure that it is clear or to localise co-existing vasal blocks which may also require surgical correction. After bilateral epididymal-vasostomies, about 50% of patients in this category regain normal sperm count, although this may take a year or more from the time of surgery (Hendry, 1988). A unilateral caudal block may be found, not uncommonly. The appearances at exploratory scrototomy are characteristic and easy to recognise by comparison with the opposite side.

### **Blocked vas**

This occurs in its simplest form after vasectomy which can serve as a good model of obstruction. Vasal blocks may also occur following infection, such as gonorrhea, when they may coexist with a caudal epididymal block, either on the same or contralateral side. Ipsilateral caudal block is excluded by finding a good flow of milky fluid on incising the vas. The most common site affected are the neck of the scrotum and in the internal inguinal ring, where the vas changes direction sharply. Totally impenetrable blocks are occasionally encountered, which generally turn out to be tuberculous. Vasal obstruction from inguinal surgery such as hernia repair in infancy or childhood is an important preventable cause of oligozoospermia. The level of the block may be defined by vasography, which should also confirm patency of the vas beyond the block. This from of obstruction is the main part of this study.

### Vasa aplasia

The vas deferens and ureter both develop from the mesonephros (Wolffian duct). Unilateral absence of the vas occurs in 0.5% - 1% of the male population (Michelson, 1949). The unilateral absence of the vas is often associated with an ipsilateral absence of the kidney (Ochsner et al, 1972) or renal abnormalities (Lukash et al, 1975). Bilateral vasa aplasia has been found in 2% - 20% of infertile patients (Dubin & Amelar, 1971; Pryor et al, 1978c). In patients with bilateral vasa aplasia the defect occurs at a later stage of development and in some patients it may be associated with cystic fibrosis (Holsclaw et al, 1971; Lukash et al, 1975). Bilateral absence of the vas is associated with low seminal volume, low pH and absent fructose. Hendry (1988) found in some cases of unilateral absence of the vas there were associated problems on the contralateral side, such as testicular atrophy, post-infective blocks, or other congenital anomalies. Hitherto considered untreatable, recent technical developments have allowed pregnancies to be produced by in vitro fertilization using motile spermatozoa obtained by micropuncture from the distended epididymal tubules (Silber et al, 1988).

### Ejaculatory duct obstruction

Obstruction at this level is rare but examples have been seen with congenital anomalies such as mullerian duct cysts, Wolffian duct malformations, diabetic megavesicles and malformations of the ampullary part of the vas and seminal vesicle. Obstruction may also occur after excision of the rectum or following surgery for imperforate anus (Hendry, 1990).

### Consequences of vas deferens obstruction

Bilateral vasectomy is an effective means of male contraception and can serve as a useful model of vas deferens obstruction. In man, the vas deferens can recover and failure rate for vasectomy attributable to surgical causes is generally reported as 1%-2%; the main causes are listed as spontaneous recanalization, surgeon's error in identifying the vasa, and the presence of an undetected supernumerary vas (Kaplan and Huether 1975). In properly vasectomized men one no longer expects to find any motile spermatozoa in ejaculates after 1-2 months, or at the latest at 3 months post-operatively; immotile (infertile) spermatozoa may occasionally still be found after a year and in rare cases even later; much depends on coital frequency after the operation (Marwood and Beral 1979).

Early advocates of vasectomy believed that this operation would produce a permanent shrinkage of the spermiogenic tissue, followed in due course by a compensating hypertrophy of the interstitial, androgenic tissue (Steinach 1920). Vasectomy fails to boost significantly the level of either testosterone or gonadotrophin in the blood circulation (Alexander et al. 1980; Koblinsky et al. 1976; Skegg et al. 1976; Smith et al. 1976; Varma et al. 1975; Whitby et al. 1979), but of special interest is the reduced content of dihydro-testosterone in the seminal plasma, which becomes obvious 1 month after the operation and is gradually accentuated with passage of time (Purvis et al. 1976a), and the diminished output of some prostatic secretory products, such as citric acid, in the seminal plasma of men vasectomized 1-8 years previously (Naik et al. 1980). The general medical consensus seems to be that the emotions experienced after vasectomy, positive or negative, are attributable to psychological rather than hormonal factors, particularly in couples with a prior history of emotional

disturbance, sexual maladjustment, tension caused by fear of pregnancy and other marital problems

With regard to early (transient) in contrast to late (permanent) effects of vasectomy, hormonal complications cannot be completely ruled out, in view of certain observations made with male accessory secretions in animals. It is conceivable that the uncommonly high values for fructose and citric acid sometimes encountered in ejaculates from vasectomized rams and bulls are the consequence of an increase in the androgen-dependent secretory activity of the seminal vesicles (Mann 1956). Similarly, in mature rats, fructose levels in the accessory organs have been reported to increase after vasoligation (Thakur et al. 1972). On the other hand, there are findings pointing in the opposite direction: in young rats in particular, a reduction in the urinary levels of 17-ketosteroids was recorded after vasectomy and vasoligation (Sackler et al. 1973).

Let us consider now the changes which occur in the spermatogenic function of the testis after this operation. Experiments on a variety of species, have produced good evidence that vasectomy or even vasoligation itself, can lead to serious, but not permanent, disturbances in the function of the germinal epithelium. In men, the disturbances in most vasectomized individuals are transient and do not produce a lasting arrest of spermatogenesis. From animal studies it appears that spermatogenesis may suffer as a result of surgical complications, such as interference with the vascular blood supply to the testis, cryptorchidism, and decreased activity of the germinal epithelium owing to distension of the seminiferous tubules and efferent ducts by the accumulating fluid and flattening of the germinal epithelium under the influence of the greatly increased hydrostatic pressure (Howards et al. 1975a; Igboeli and Rakha

1970; Neaves 1975a, 1978b; Tischner 1971a,b; Turner et al. 1979a; Vare and Bansal 1973). An immediate and unavoidable effect of vasocclusion upon the epididymis is the increase of intratubular pressure and congestion, which is seriously aggravated by the continuing influx of spermatozoa from the testis, which in some cases results in the formation of cysts filled with spermatozoa. A spermatocele of this kind can appear either in the epididymis itself or at the site of ligation on the vas, and once it has developed it may produce an adverse effect on sperm maturation in the epididymis. There is species variation in development of spermatoceles. They develop readily in bull and rat but not so in rabbits. However in all species the epididymis becomes grossly enlarged and characteristically distended after vasoligation.

Apart from these effects, vasectomy involves certain other hazards of particular concern to men (for review, see Alexander 1976; Leader et al. 1974). Some of the complications are: acute epididymo-orchitis, adhesion of the vas to the skin surface, cutaneous fistula, ligature abscess, scrotal haematoma and postoperative hydrocele. More frequent after-effects are formation of nodules or granulomas in the vas and epididymis, and the appearance of sperm-agglutinating or sperm-immobilizing antibodies in the blood plasma.



## **Section 2**

### **Experimental Work**

### Purpose of the Experimental Study

The aim of this thesis is to study the potential damage of the vas deferens during inguinal surgery and its effect on fertility.

This involves six different aspects:

- 1 The development of an experimental Wistar rat model.
- 2 The effect of surgical technique on the immature vas deferens
- 3 The effect of surgical technique on the mature vas deferens
- 4 An examination of the autonomic and peptidergic innervation of the vas deferens following surgical manipulation
- 5 A study of the consequences of surgery on vas deferens contractility
- 6 Report on clinical patients with inadvertent vas deferens damage and sterility

## Chapter 13

### The Wistar Rat Model

The Wistar albino rat is a recognized laboratory animal. It was developed at the Wistar Institute, Philadelphia, Pennsylvania. This is a quiet, moderately prolific strain which has spread to laboratories throughout the world; it is rather resistant to infection and has a low incidence of spontaneous tumours.

### Life Span

The laboratory rat will live for at least 3 years, provided it is in good health. The great majority of laboratory rats however develop chronic respiratory disease, which causes progressive damage to the lungs, so that by the time the animal is 1.5 to 2 years old a large proportion of the lung tissue will have been destroyed. Such animals will not achieve a life span of 3 years.

### Development

The rat weighs about 5g at birth. It is hairless, with closed eyes and ears, and no erupted teeth. The new-born rat is scarlet in colour, but at two days it is pink. It is active and will suck at the mother's nipple almost from the first hour of extra - uterine life.

The body hair begins to appear on the 4th day and the eyes and ears open on the 13th day. By the 10th day the animals are well covered with fur, and begin to wander away from the nest. On about the 16th day they will begin to eat any solid food they can find in the cage, and to drink from the water bottle if they can reach it. They will also begin to nibble faecal pellets, for

the rat practises refection or coprophagy as a normal part of its feeding behaviour.

#### **Breeding Cycle**

The laboratory rat is sexually mature at 6.5 to 7.5 weeks of age, and the female will have her first oestrous cycle at 6 to 7 weeks. The testes of the male descend at about this time, but they are retractable throughout life. Maximum fertility is said to be reached in 100-300 days.

The oestrous cycle in the female lasts for about 12 hours, and recurs every 4 or 5 days; there is also a post-partum oestrus.

The rat has usually been regarded as a spontaneous rather than an induced ovulator. It is true that a female rat will normally have a regular cycle, unless she is with a group of females, when oestrus may be suppressed. She will, too, normally be receptive to the male only at oestrus. But a vigorous and experienced male rat will forcibly mate with a female that is not in oestrus and the female will frequently ovulate, and become pregnant as a result.

Pseudopregnancy is quite rare. Infertility can occur in both the male and the female. Vitamin E deficiency will cause sterility which is permanent in the male but reversible in the female. Too high a temperature will also depress male fertility. Controlled illumination is important for breeding and 12 - 16 hours of light in 24 hours are recommended. A male rat will be able to serve satisfactorily a harem of six to nine females, and if young will be expected to impregnate all. A female rat however will not always tolerate another female in the cage once she has a litter. If rats are bred in harems, therefore, the females have to be removed when heavily pregnant and placed on their own in maternity cages.

After mating, the rat will show a vaginal plug, and usually this tends to fall out within a few hours. A more certain way to know if a mating has occurred is to examine a vaginal smear. If spermatozoa are seen in the smear, then mating must have occurred within the last 12 - 24 hours.

#### Male Genitalia

The scrotum of the adult rat is large and forms a prominent subcutaneous swelling immediately ventral to the anus. The testes descend into the scrotum at about 4-5 weeks of age and have very large fat masses surrounding their cranial poles. These project through wide inguinal canals that remain open and allow withdrawal of the testes. The fat bodies surround the epididymis and the gonadal vessels while in the scrotum but as they pass through the inguinal canals the fat bodies leave these and project cranially into the abdominal cavity.

Before joining the urethra each vasa has a swelling or ampulla which is surrounded by ampullary glands. These open by a single duct into the corresponding ampulla and the vasa then narrows again before entering the urethra.

Unlike the human there are paired vesicular glands which are large, lobulated and rather hook shaped. The paired coagulating glands occupy the inside curve of the hook and are included in the same sheath of fascia. There are two pairs of prostate lobes, ventral and dorsal (in addition to the coagulating glands) and these practically surround the entry of the deferent ducts into the urethra (Fig13.1). The bulbo-urethral glands are globular, paired, and open into the urethra near the ischial arch. The terminal and slightly rough glans occupies the prepuce. An os penis is present. A pair of relatively large preputial glands open directly into the prepuce just inside its external orifice.

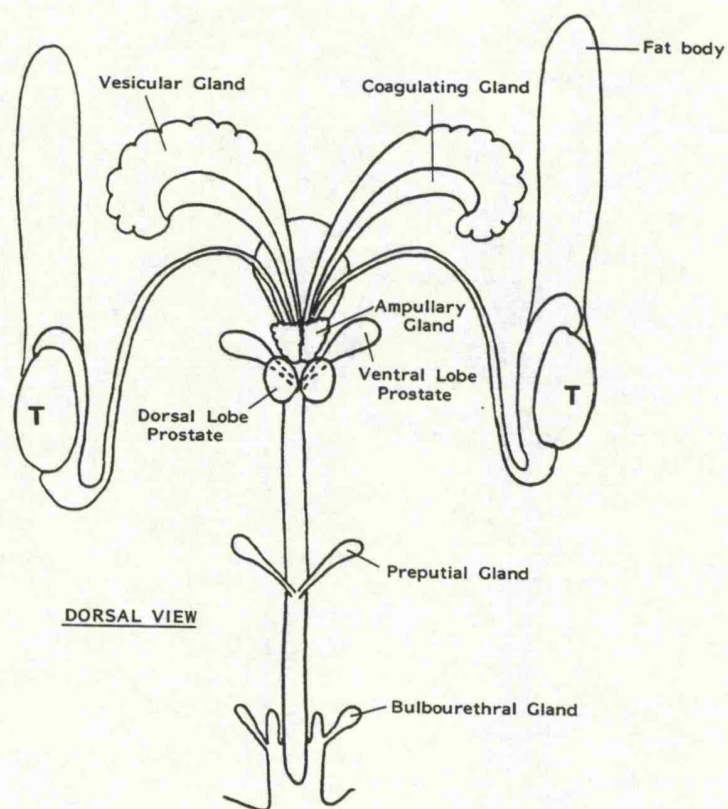


Fig 13.1 Anatomy of the male Wistar rat. Note the pair of large fat bodies attached to the testis (t).

### Development of the Wistar rat model

The Wistar rat is highly fertile and female rats have short oestrous cycles and multiple pregnancies. Therefore as a fertility model the animal is ideal.

All operations were done under full aseptic technique using intraperitoneal neuroleptanalgesia consisting of a cocktail of Hypnorm (Fentanyl citrate 0.315mg + Fluanisone 10mg/ml) and Hypnovel (Midazolam HCl. 10mg/2ml) (Fig 13.2). Fentanyl is an analgesic of the morphine type. Fluanisone is a neuroleptic of the butyrophenone group. Midazolam is a potent Imidazobenzodiazepine with a rapid action and of short duration. The rats were given oxygen by mask and further 1% halothane if necessary (Fig 13.3). The skin was shaved and prepared with chlorhexidine solution. Sterile plastic drapes were used. The surgery was carried out through a scrotal neck incision. This gave good access to the cord and the inguinal ring and caused minimum disruption to the scrotum thus enabling the testis to be replaced in the scrotum with ease. Initial dissection revealed the cord to be seen clearly delivered from the inguinal canal. The anatomy and surgical technique is shown in Figs 13.4-13.10. The fat body is separate and since the cord is not invested with multiple layers of spermatic fascia experiments on the vas deferens and the inguinal ring are easily reproducible. Hence different experimental groups are comparable. The use of bipolar diathermy was kept to an absolute minimum as the former is quite destructive. When ever possible cat gut ties were used instead of diathermy. Inguinal ring reconstruction was undertaken using non absorbable 3-0 nylon sutures over 2mm and 4mm pins (Figs 13.8; 13.9). This mimics conventional surgery of tight and loose inguinal ring repair respectively, and the non absorbable nylon allows ease of identification of sutures subsequently. Replacement of testes

in the scrotum at times can be difficult due to swelling and the size of the fat bodies. There is a risk that the testis can end in a dartos pouch. To avoid this it is easier to place the testis in the abdomen and then milk them down into the scrotum. This avoids unnecessary trauma to the tissues which can lead to further scrotal swelling and tightening of the skin sutures. The latter point is important as the animals will readily respond to discomfort by licking the scrotum and chewing through the skin sutures. This can lead to complications as shown in Figs 13.10 - 13.15.

#### FIGURE 13.2

##### ANAESTHESIA USED

Intraperitoneal cocktail:-

1. One vol. Hypnorm [Fentanyl Citrate 0.315 mg  
+ Fluanisone 10mg/ml]
2. Two vol. Hypnovel (Midazolam HCL. 10mg/2ml)
3. One vol. of water

Dose given: 3mls per kg. of body weight/intraperitoneal injection



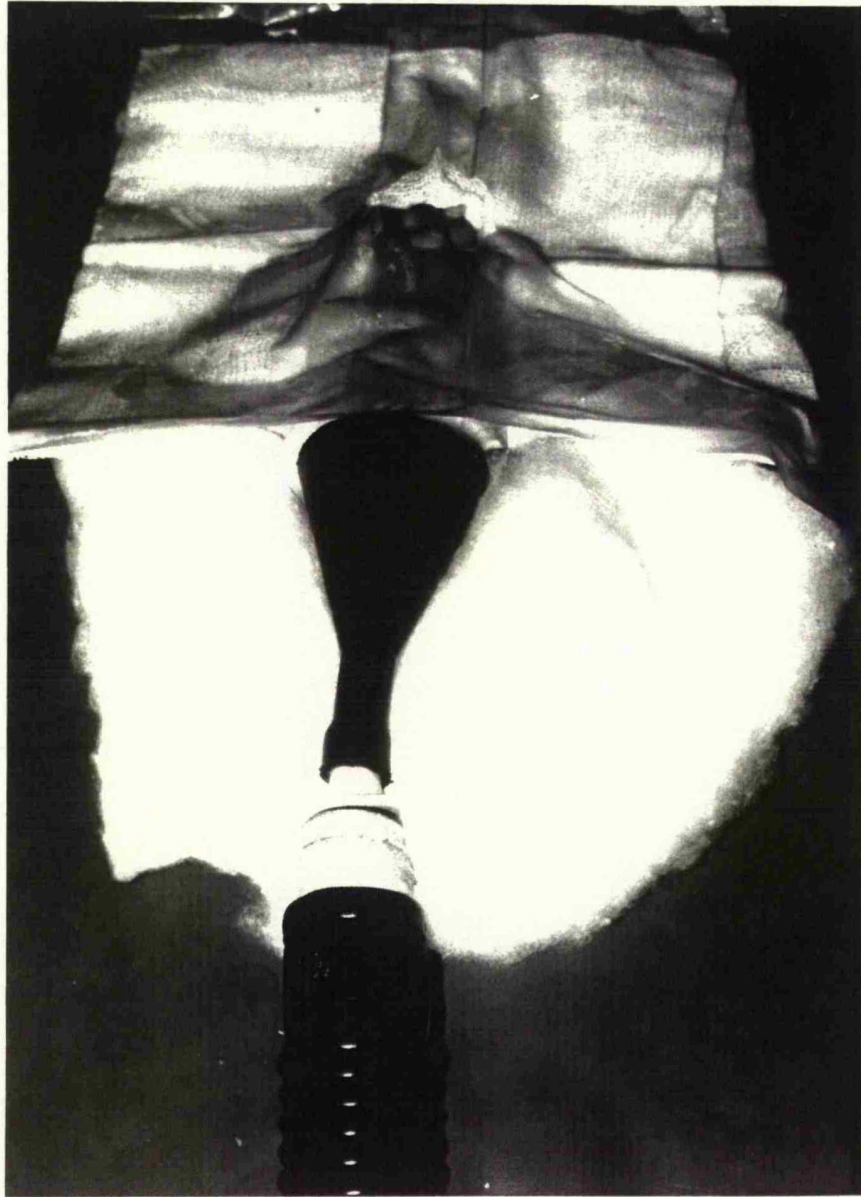

Fig 13.3      Operative technique: The rat receives continuous oxygen and 1% halothane mixture while the testis are delivered through sterile drapes.

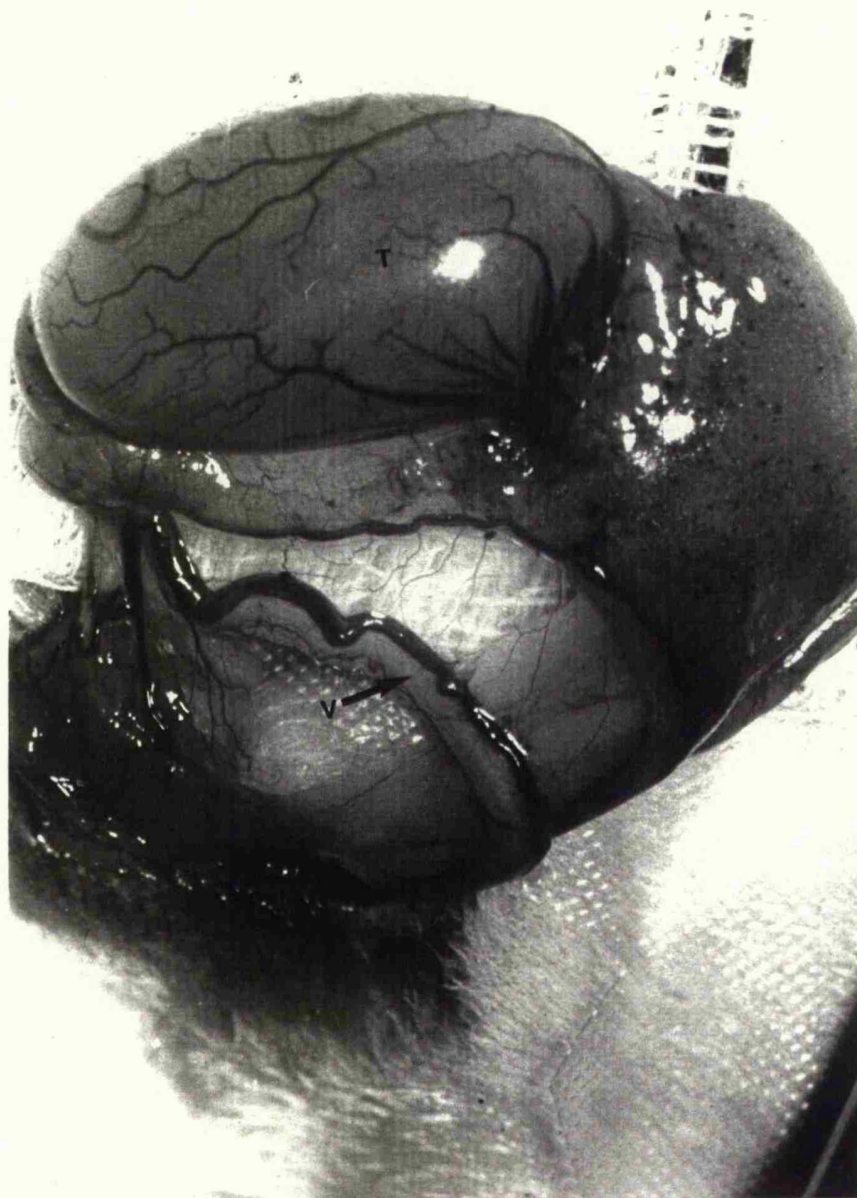


Fig 13.4 The vas (v), and testis (t) delivered from the inguinal canal. Note the artery to the vas lying superiorly.

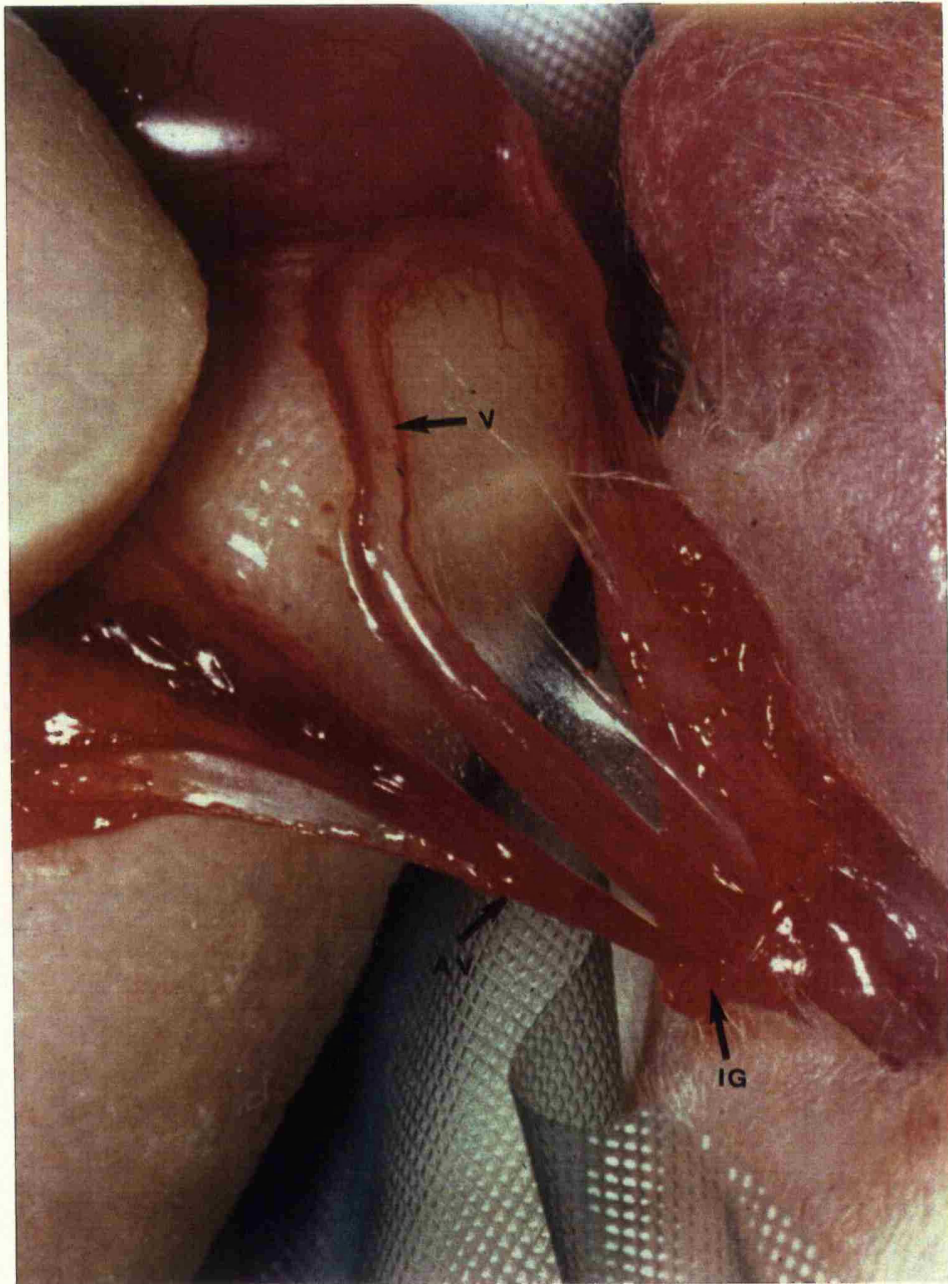


Fig 13.5      Anatomy of the inguinal ring (ig). The vas (v) and testicular artery and vein (av) can clearly be identified



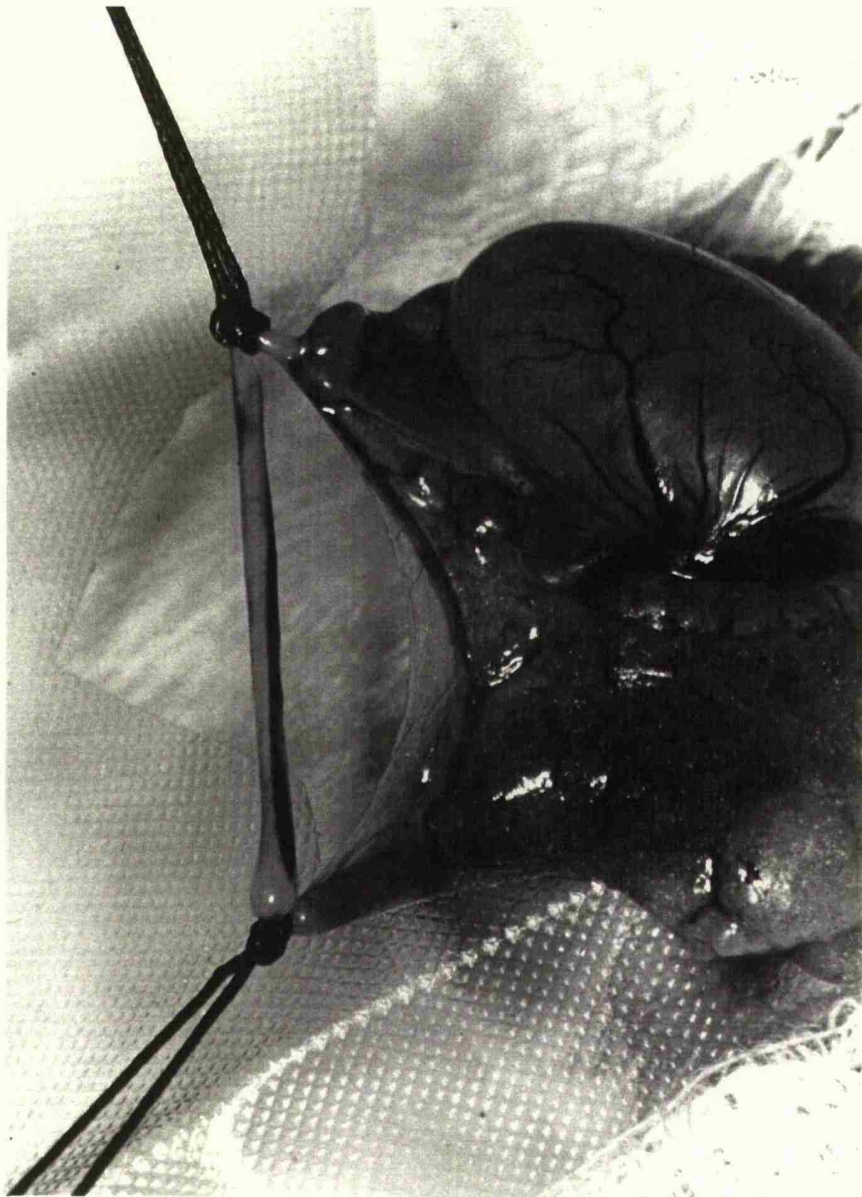


Fig 13.6      The two ends of the vas are tied prior to vasectomy

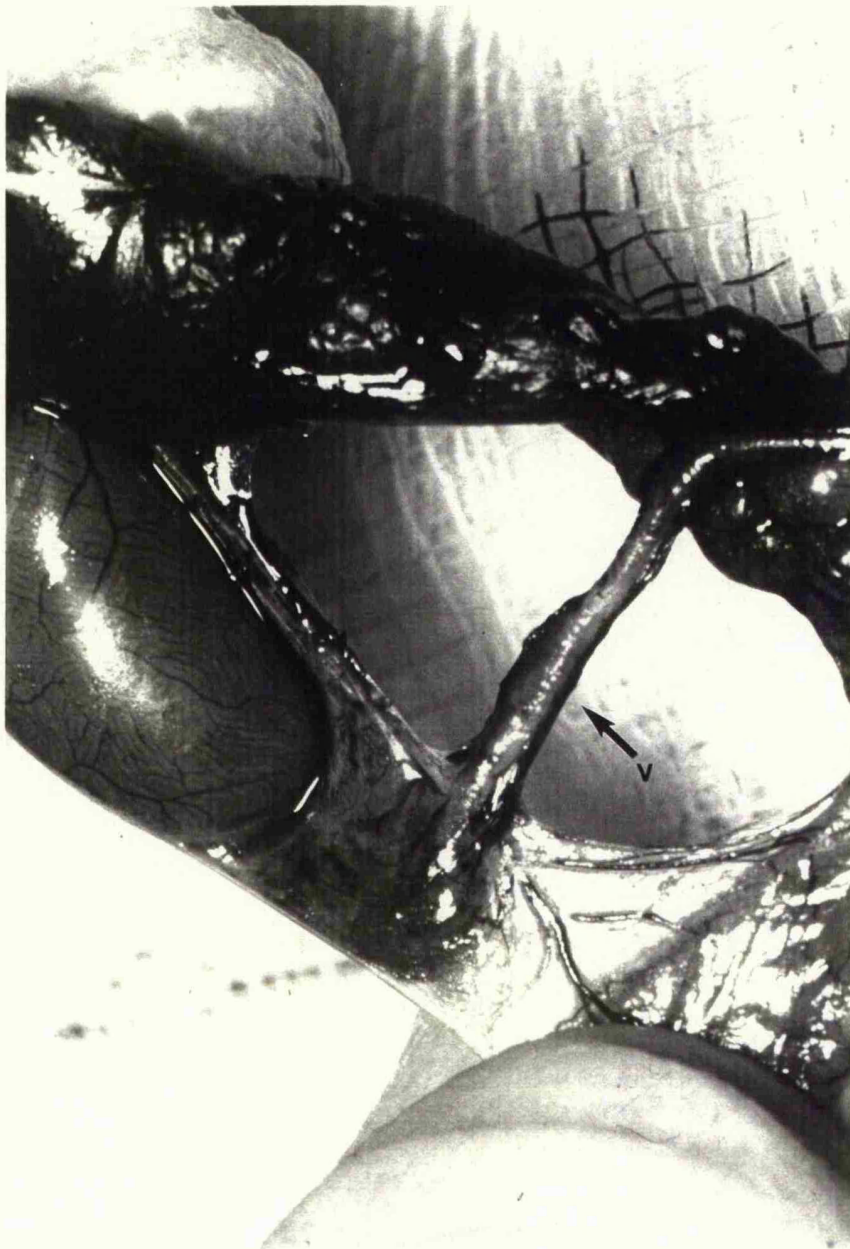


Fig 13.7      Vas deferens (v) that has been stripped by sharp and blunt dissection

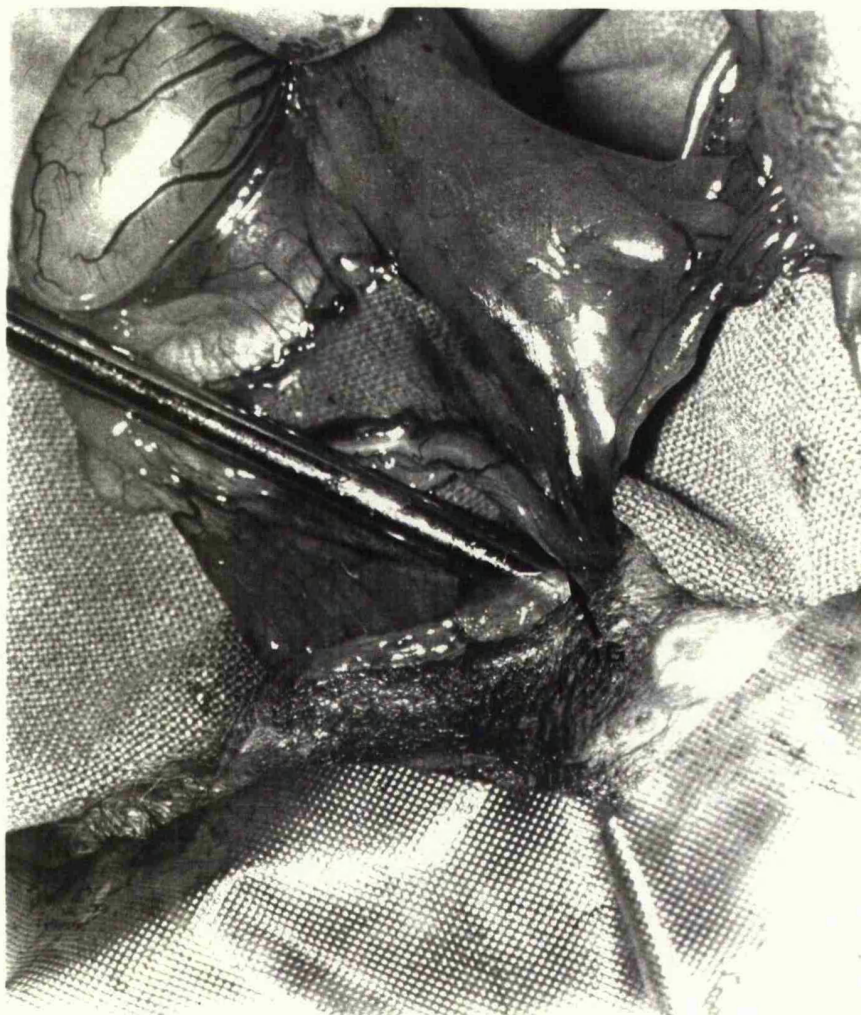


Fig 13.8 Tight inguinal repair. A 2mm pin has been placed in the inguinal ring (ig) prior to it being tightened.



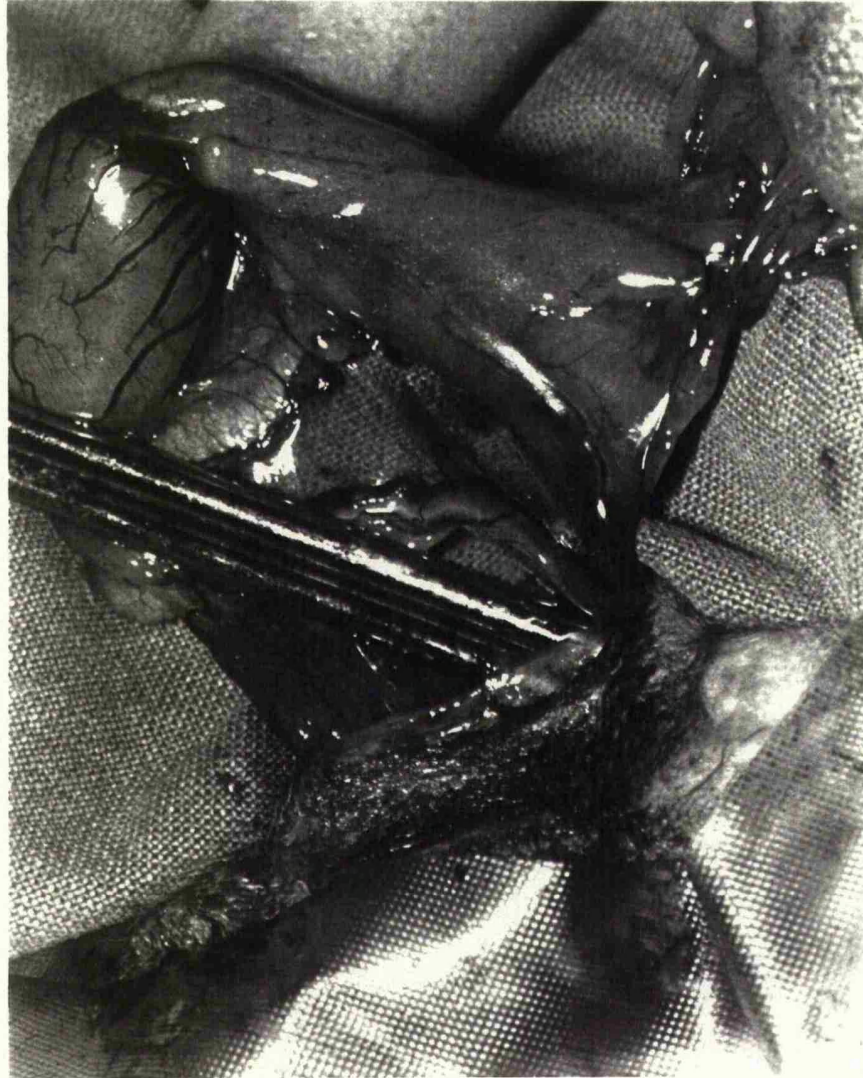


Fig 13.9      Loose repair of the inguinal ring is facilitated by using two 2mm pins.

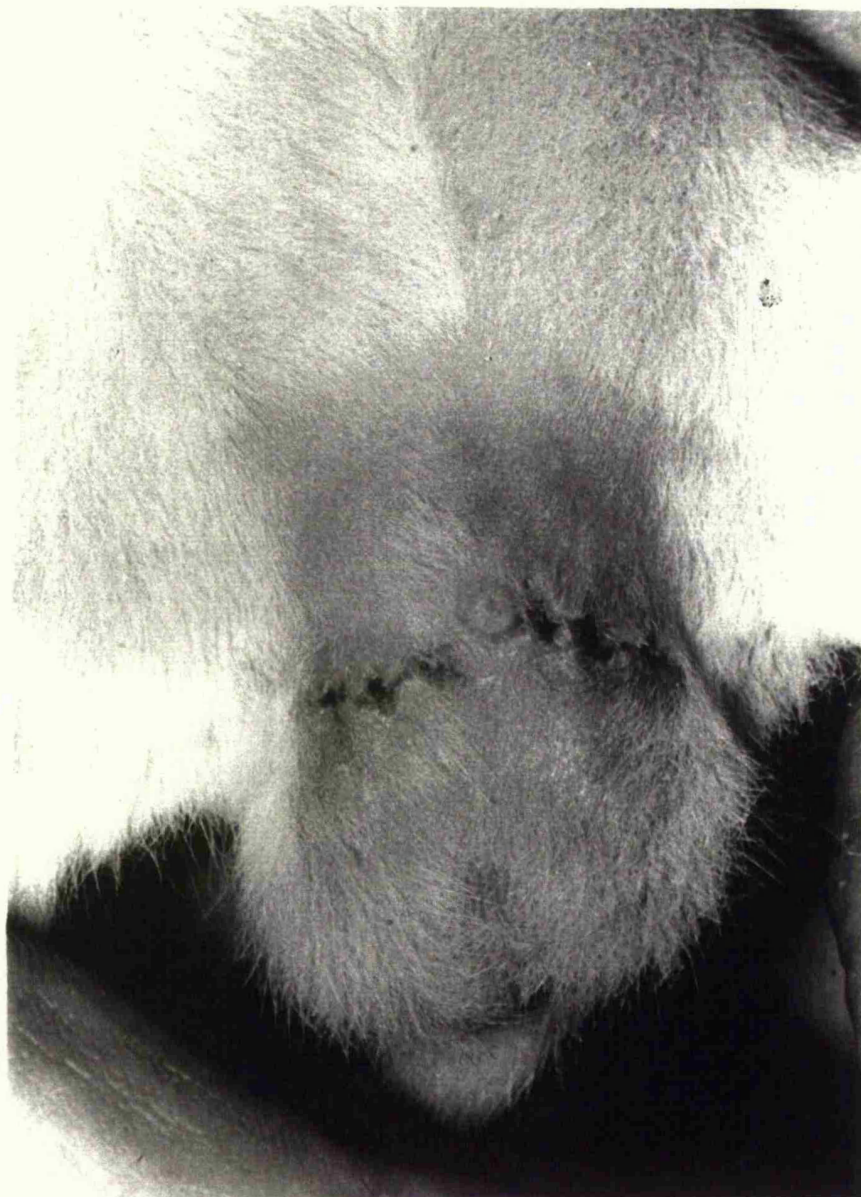


Fig 13.10 A typical well healed scrotal wound



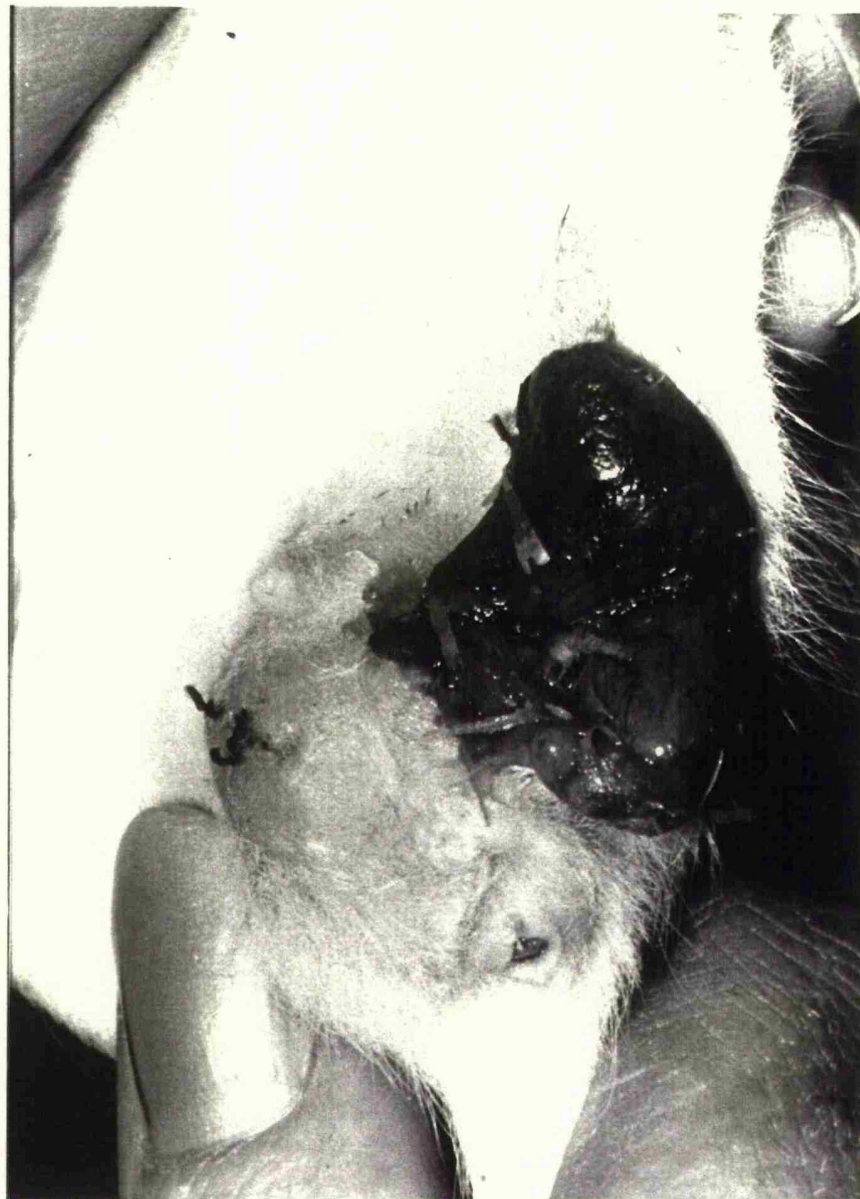


Fig 13.11      Daily wound inspection is necessary as following scrotal surgery the animals lick and chew the wound. This can lead to disruption with a burst wound and epididymorchitis necessitating sacrifice of the animal

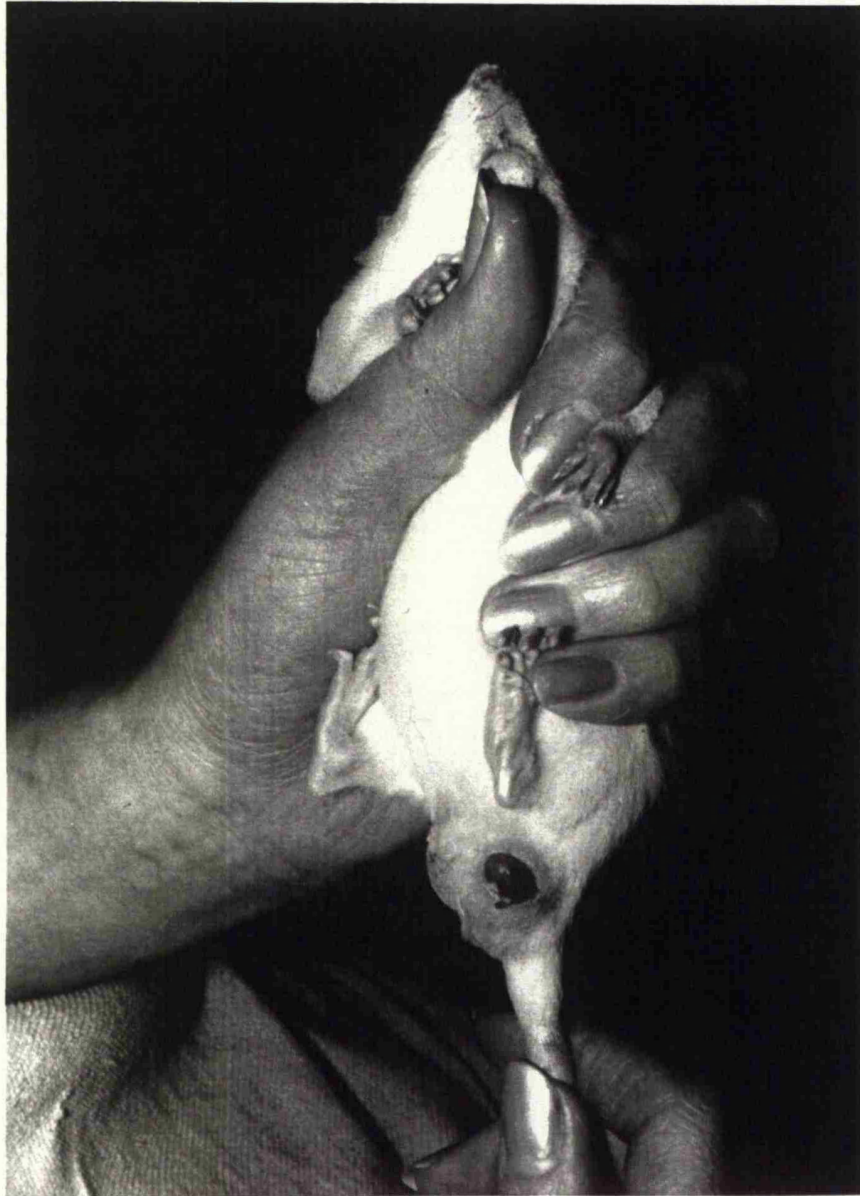

Fig 13.12 This animal was saved by resuture of the scrotum.

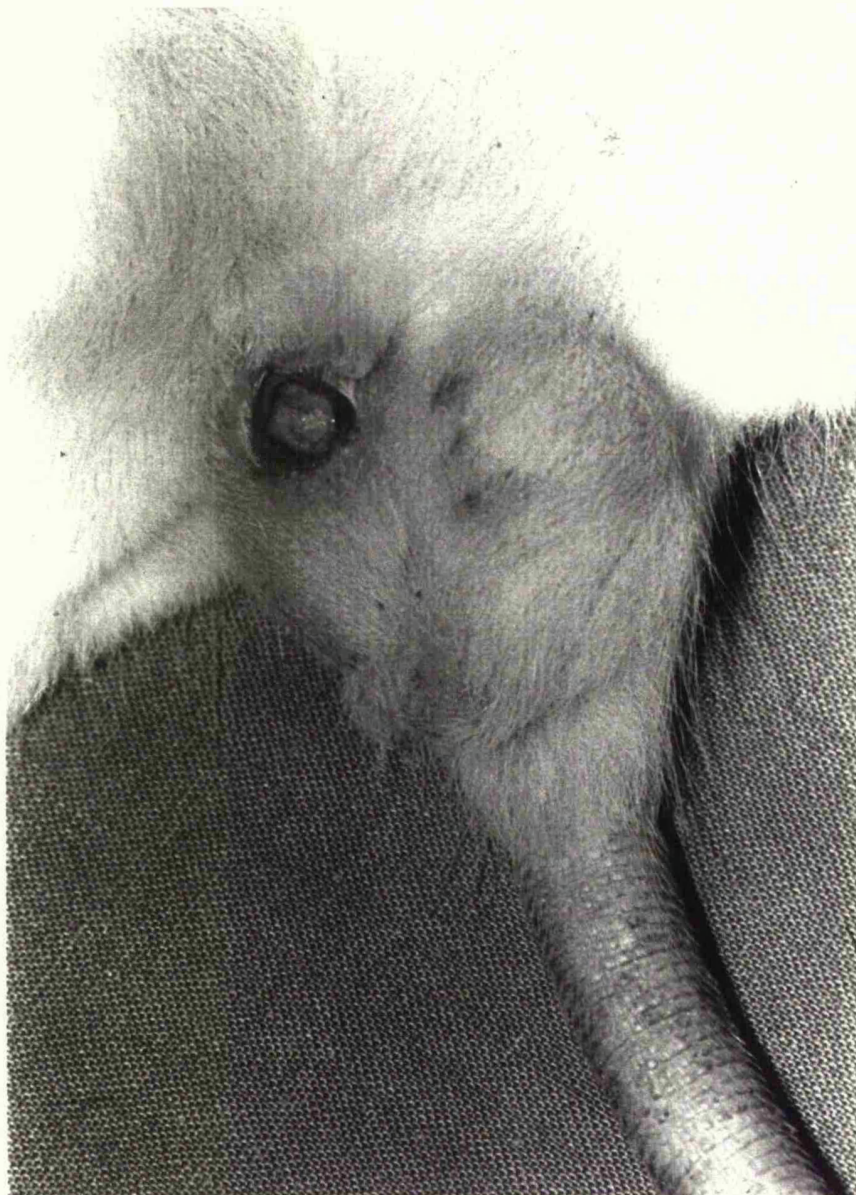


Fig 13.13 Late wound infection that required resuturing of scrotum



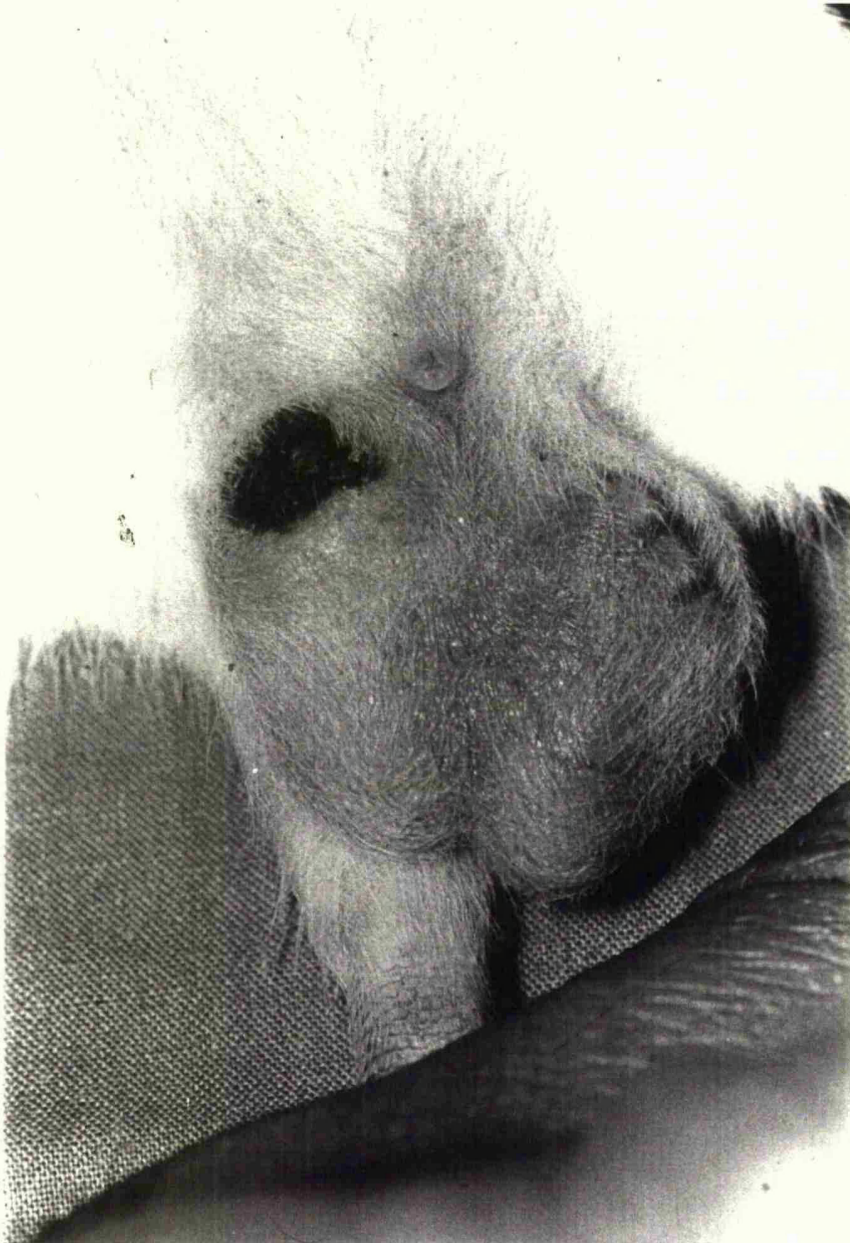


Fig 13.14 Ulceration of scrotum that healed spontaneously

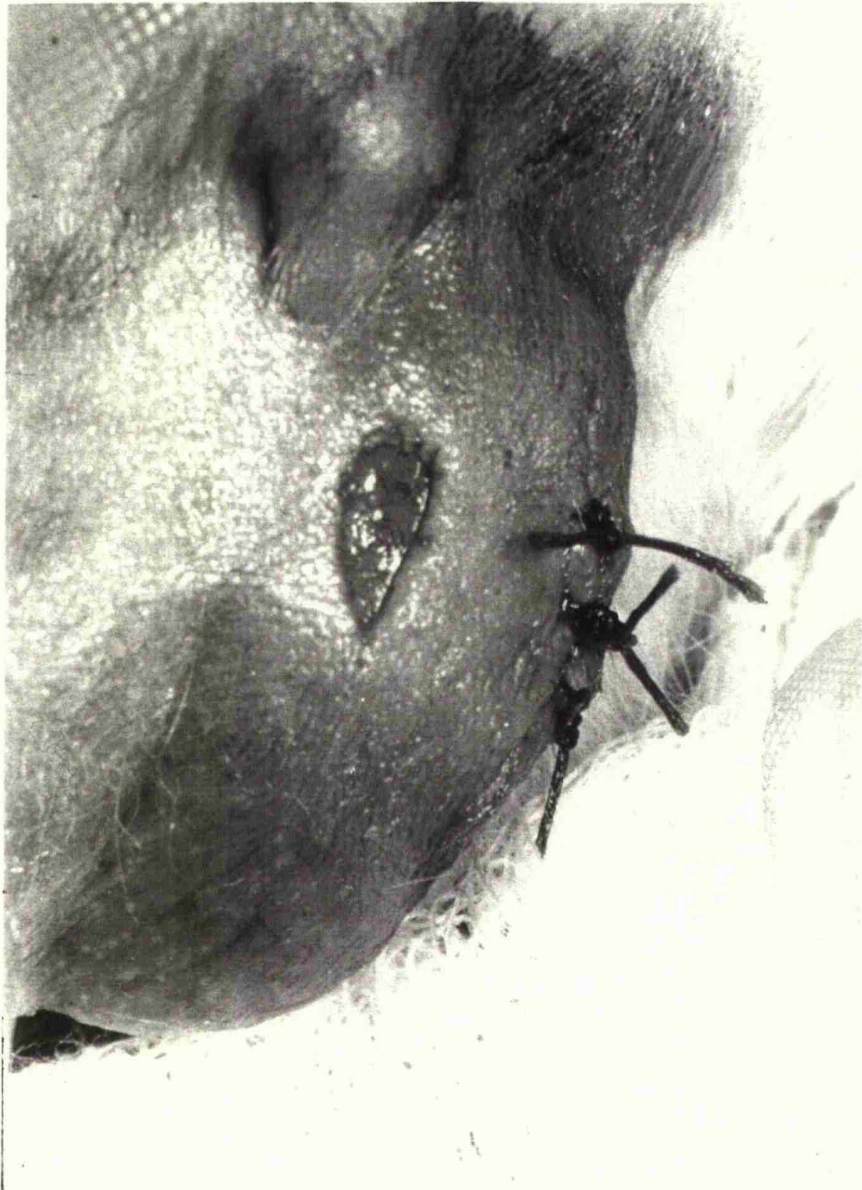


Fig 13.15 Early postoperative odema with superficial ulceration

## Chapter 14

### Effect of Surgical Technique on the Immature Vas Deferens

#### Summary

Following unilateral vasectomy the contralateral vasa of 52 four week old Wistar rats were subjected to 7 different manipulations. After 7 weeks a fertility trial was conducted. All sham operated rats (n=18) were fertile. Twenty two of the remaining 34 rats (65%) were sterile. All with tight ring reconstruction (n=6) were sterile, due initially to venous obstruction. Nine out of 14 rats with acute clip trauma (65%) remained fertile but 11 out of 14 (78%) with full mobilisation were sterile due to extensive avascular fibrosis of the vas deferens. These results suggest that over zealous cord handling and operative technique in the immature animal is counterproductive and leads to vasal occlusion. This may have important repercussions in paediatric inguinal surgery with subsequent higher incidence of azoospermia and male subfertility.

#### Material And Methods

The Wistar rat does not become sexually mature till the age of 6 - 7 weeks. Hence operative manipulations were performed on fifty two four week old sexually immature random bred male Wistar rats (74-115g). They were divided into eight groups and underwent different operative manipulations as shown in Table 14.1. Apart from Group 1 the unoperated controls, all rats underwent a vasectomy on the left side, and a different operative manipulation on the right side. Groups 2 (Sham ) & 3

(Cord mobilization) had minimal handling of the cord. In Group 4 the artery to the vas deferens was stripped by sharp and blunt dissection. In Group 5 the vas deferens was crushed by means of an arterial clip for 30 seconds. Herniotomy and extensive mobilization of the cord can cause odema and pressure on the vas at the deep inguinal ring especially if the sac transfixation suture catches the edge of the canal. Certainly in inguinal herniorrhaphy, as part of the posterior wall repair the deep ring is tightened and in a younger man with a congenital hernia an over enthusiastic repair can cause ischaemic damage to the vas deferens and the testis. With the above in mind, a tight herniorrhaphy repair was simulated by a constricting ring reconstruction over a 2 mm diameter pin in Group 6. A looser repair over a 4mm pin was done in association with stripping the vas and crush injury in Groups 7 and 8 respectively. All operations were done under full aseptic technique using intraperitoneal neuroleptanalgesia consisting of a cocktail of Hypnorm and Hypnovel as described in Chapter 13 (Fig 13.2). The rats were given oxygen by mask and further 1% halothane if necessary.

The male rats were then caged separately and allowed to mature for a further 7 weeks. At the age of 11 weeks, each male rat was caged with five female Wistar rats. This extensive fertility trial lasted for 3 weeks, during which the females had at least three oestrus cycles. The presence of vaginal plugs confirmed mating. At the completion of the fertility trial the rats were sacrificed. The presence of pregnancy, litter size and any foetal abnormality was recorded. The weight of each testis and total prostate weight per 100g body weight was recorded, and histological assessment of the vasa deferens and the testes was performed without knowledge of experimental groups. The histological features that were used to assess vasa and testis damage are shown in Figs 14.1 and 14.2 respectively. In some of the rats (n=8) vasograms (Fig 14.3 - 14.5) were

undertaken at the time of sacrifice to demonstrate vas deferens patency or an obstructive lesion. In this study this was not carried out on the full series in case this caused difficulty in interpreting the histological data. It is possible that even a fine needle may strip the pseudocilia, cause luminal damage and wash the sperm away.

#### Statistical Analysis

Comparisons within a rat group were made by means of the paired t- test, and those between rat groups using the two sample t-test.

#### Results

##### Fertility data

The fertility data is summarised in Table 14.2 giving a total sterility rate of 42%. Complete data involving this study is given in Appendix 14.1 - 14.8. The 18 rats in Groups 1-3 (no operation, sham procedure, mobilising the cord respectively) had minimal handling of the cord and were all fertile. In the remaining five groups 22 of 34 rats (65%) were sterile (Table 14.3 ). In Group 4 stripping of the vasa resulted in a sterility rate of 71% (n = 5). Severe crush injury to the vas deferens in Group 5 produced a low sterility rate, with only two out of seven rats sterile. In Group 6 (tight repair) all six rats were sterile; testis infarction occurred in four but the remaining two had histologically normal testis (Fig14.6A) and vasa deferentia (Fig14.7A) In Group 7 stripping the vasa together with loose inguinal reconstruction was particularly destructive with a high sterility rate of 86% (n=6) . In contrast crush injury and loose inguinal reconstruction in Group 8 resulted in a sterility rate of only 43% with three out of seven rats sterile.



In this series (Groups 4-8) the incidence of testis infarction (Fig14.6B), (n=8) was 24%, but in four rats, testis infarction was associated with an abnormal vas deferens. In the remaining four cases (12%) testis infarction was the sole cause of infertility and these were all related to Group 6 with tight reconstruction of the ring (Table 14.3).

The histological pattern of vas deferens damage in this study (Fig14.7B) appears uniformly over a long segment, which is the case seen with post operative occlusion, unlike infection which is likely to produce multiple vasal blocks.

#### Testis weight data

The mean left testis weight/100g body weight 0.48 (S. D.0.09) (Table 14.2) was significantly higher compared with the right (operative manipulation) side 0.42 (S.D.0.17); ( $p=0.027$ ). Comparing the fertile right testis with the sterile right testis, the mean weight of the right testis was less in the sterile group 0.35g (S.D. 0.24) compared with the fertile group 0.47g (S.D. 0.06) and this was statistically significant at  $p<0.01$ .

#### Prostate weight data

The prostate weight was slightly higher in the fertile group (mean=0.92gms s.d.0.19) compared with the sterile group (mean=0.83gms s.d.0.14)  $p < 0.06$ . However this data includes the weight of the coagulating gland and hence is not truly representative of the prostate.

#### Discussion

These results show that surgical technique, intended or unintended may significantly affect fertility. Ring reconstruction and stripping the vas is particularly destructive. Nine rats with acute clip trauma (65%) remained

fertile but 11 (78%) with full mobilization were infertile due to extensive avascular fibrosis of the vas (Fig 14.7B). In Group 6 all rats (n=6) with tight ring reconstruction were infertile. But in two of these there was no vasal block (Fig 14.4) and histologically the testis (Fig 14.6A) and vas (Fig 14.7A) looked normal. One further rat in Group 8 ( crush & loose repair ) had a normal vas and testis. These 3 rats underscore the fact that vas patency is not always associated with fertility as other factors such as vas contractility and secretion may be important. The other 4 rats in Group 6 had a normal vas but an infarcted testis (Fig 14.6B) due initially to venous obstruction. Suprisingly accidental crush trauma over a short segment of the vas frequently resolved completely (28% sterility rate), but extensive anatomical vas mobilisation (as commonly practised to obtain extra length) for an undescended testicle is physiologically destructive.

**TABLE14.1: Details of Operative Procedure in Groups 1-8.**

Group number	Number of rats	Operative procedure on right side
1	3	Nil
2	8	Sham operation
3	7	Mobilising the cord
4	7	Strip the vas
5	7	Crush injury arterial clip 30 secs.
6	6	Tight repair inguinal ring over 2mm diam. pin
7	7	Strip vas + loose repair inguinal ring over 4mm diam pin
8	7	Crush injury arterial clip 30 secs + loose repair inguinal ring over 4 mm diam. pin

Note: Gps. 2-8 vasectomy performed on left side.

**TABLE14.2: Summary of Fertility Data and Testis Weights.**

Group no.	No of rats	No. fertile	Sterility rate	Mean right testis wt.	Mean left testis wt.
1 control	3	3	0%	0.45g	0.48g
2 sham	8	8	0%	0.49g	0.48g
3 mobilise cord	7	7	0%	0.48g	0.46g
4 strip	7	2	71%	0.48g	0.46g
5 crush	7	5	28%	0.45g	0.48g
6 tight repair	6	0	100%	0.22g	0.43g
7 strip+loose repair	7	1	86%	0.37g	0.49g
8 crush+loose repair	7	4	43%	0.40g	0.53g

Testis weights are expressed in g\ 100g body weight.

**Figure 14.1**

**Histological Criteria for Vas Assessment**

- 1 General architecture
- 2 Presence of endothelial spiral
- 3 Pseudocilia damage
- 4 Presence of sperm in lumen
- 5 Luminal narrowing
- 6 Muscular damage
- 7 Presence of polymorphs

**Figure 14.2**

**Histological Criteria for Testicular Assessment**

- 1 General architecture
- 2 Size of tubules
- 3 Spermatogenesis - layering of cells normally 5-6
- 4 Contents of tubules
- 5 Presence of sperm in tubules
- 6 Infarction

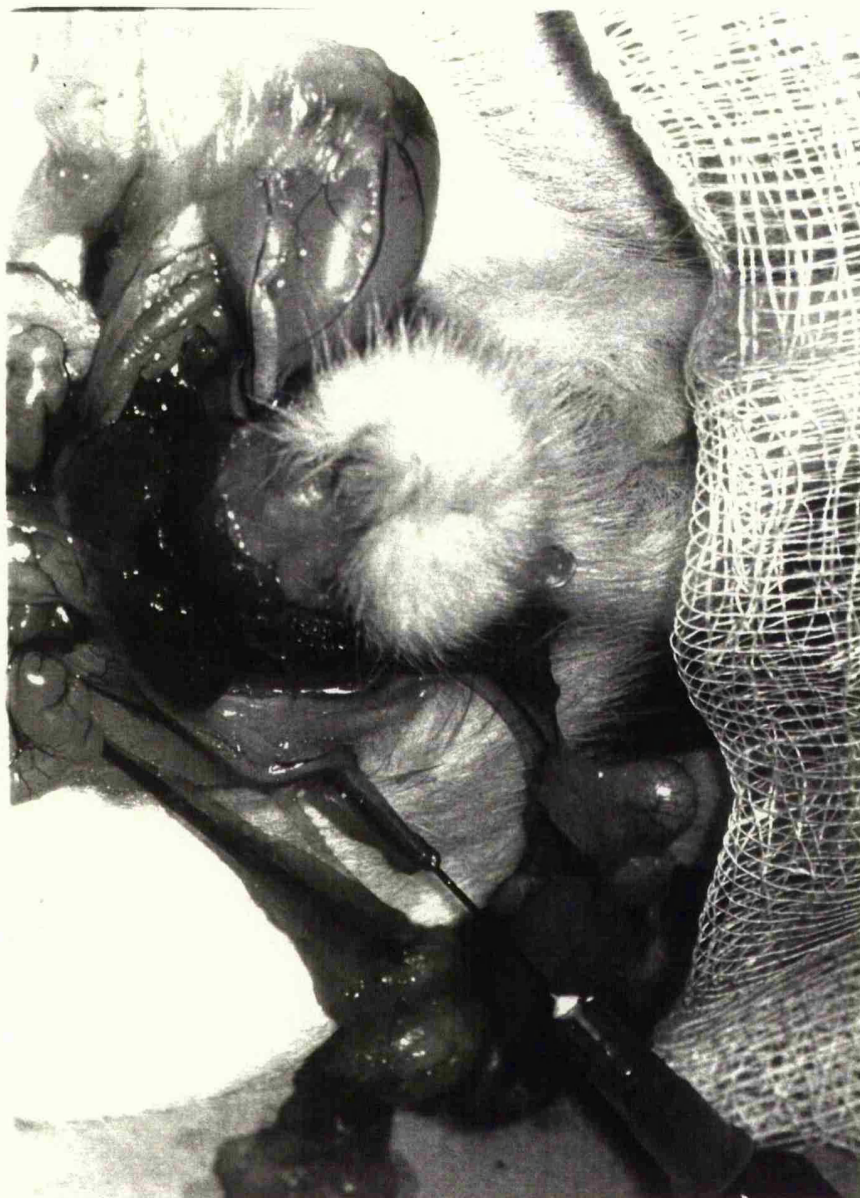


Fig 14.3 Vasography using saline or contrast media was undertaken using a fine 27 G needle. Absence of resistance and filling of the bladder denotes a patent vas

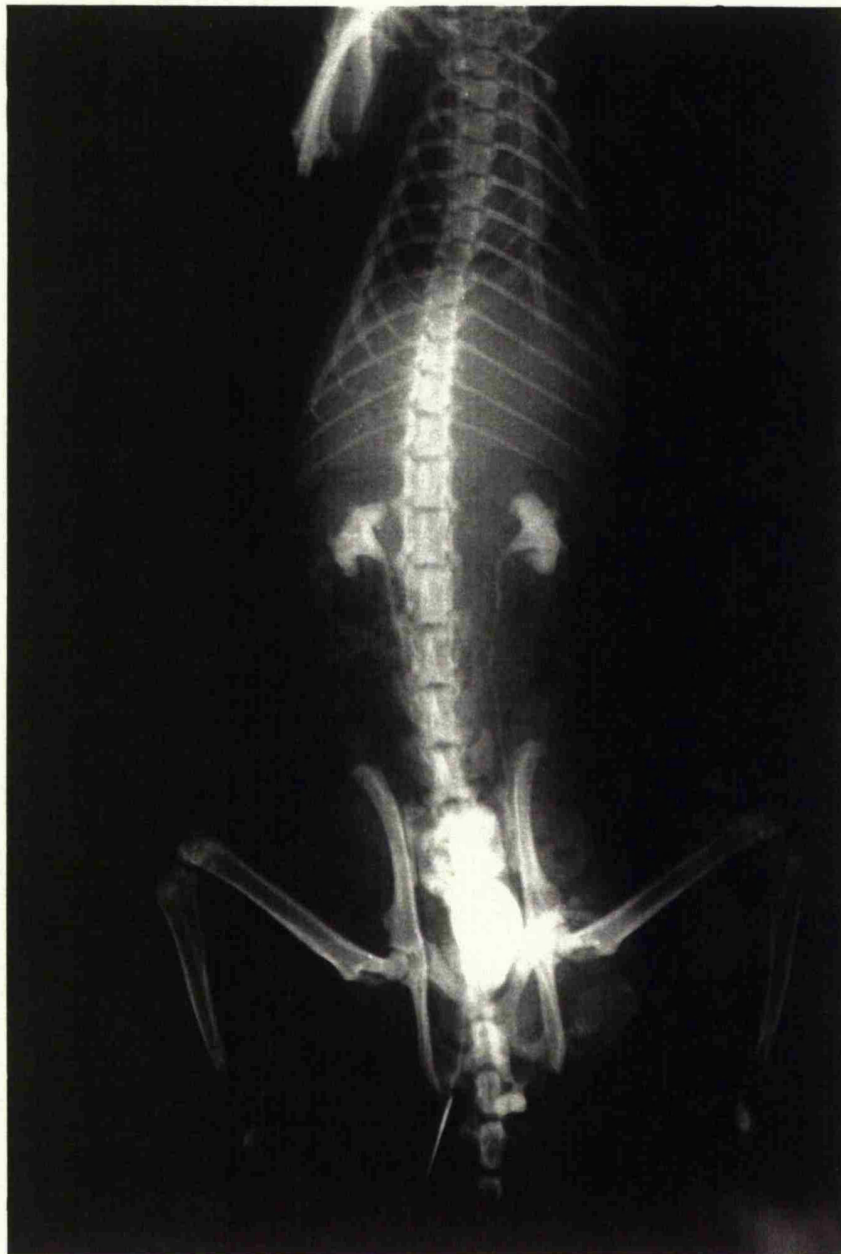

Fig 14.4 Xray of a vasogram demonstrating a patent right vas deferens, bladder full of contrast and incidental bilateral retrograde pyelograms

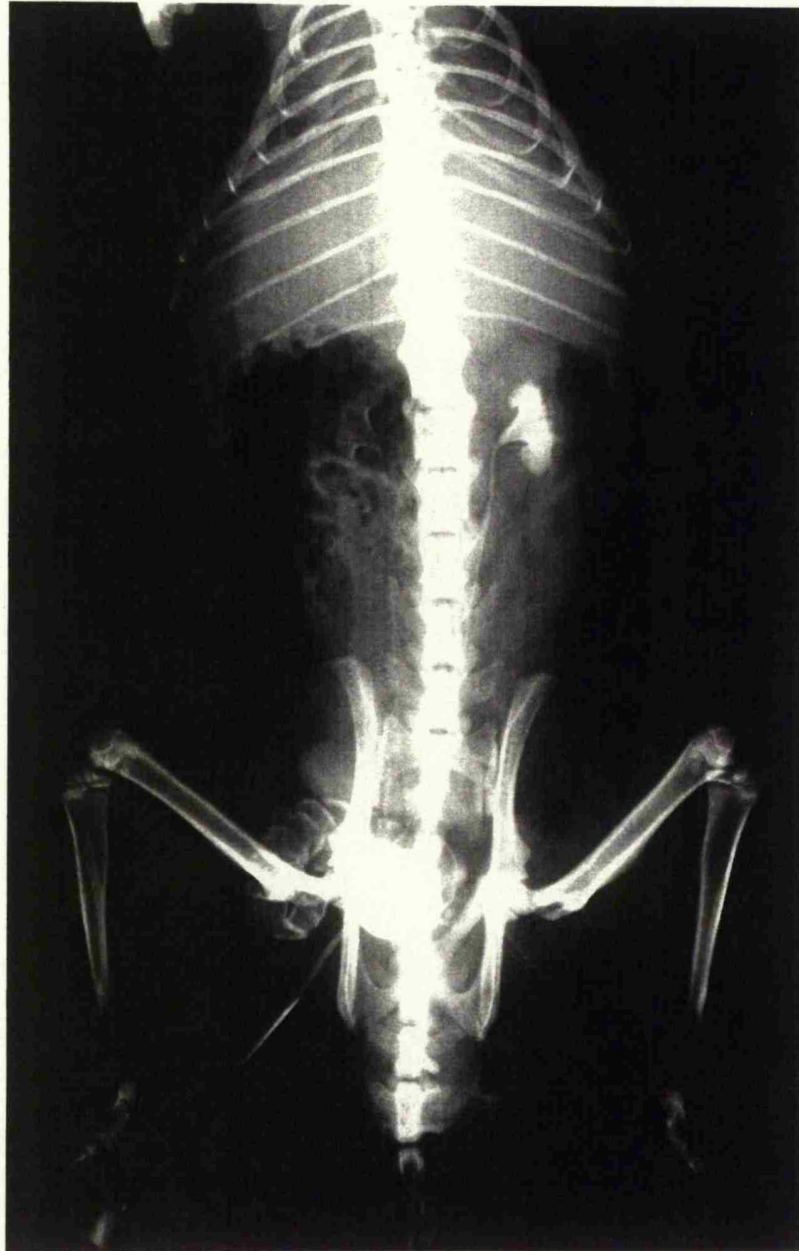


Fig 14.5      Another example of an Xray demonstrating a patent vas deferens with filling of the right seminal vesicle



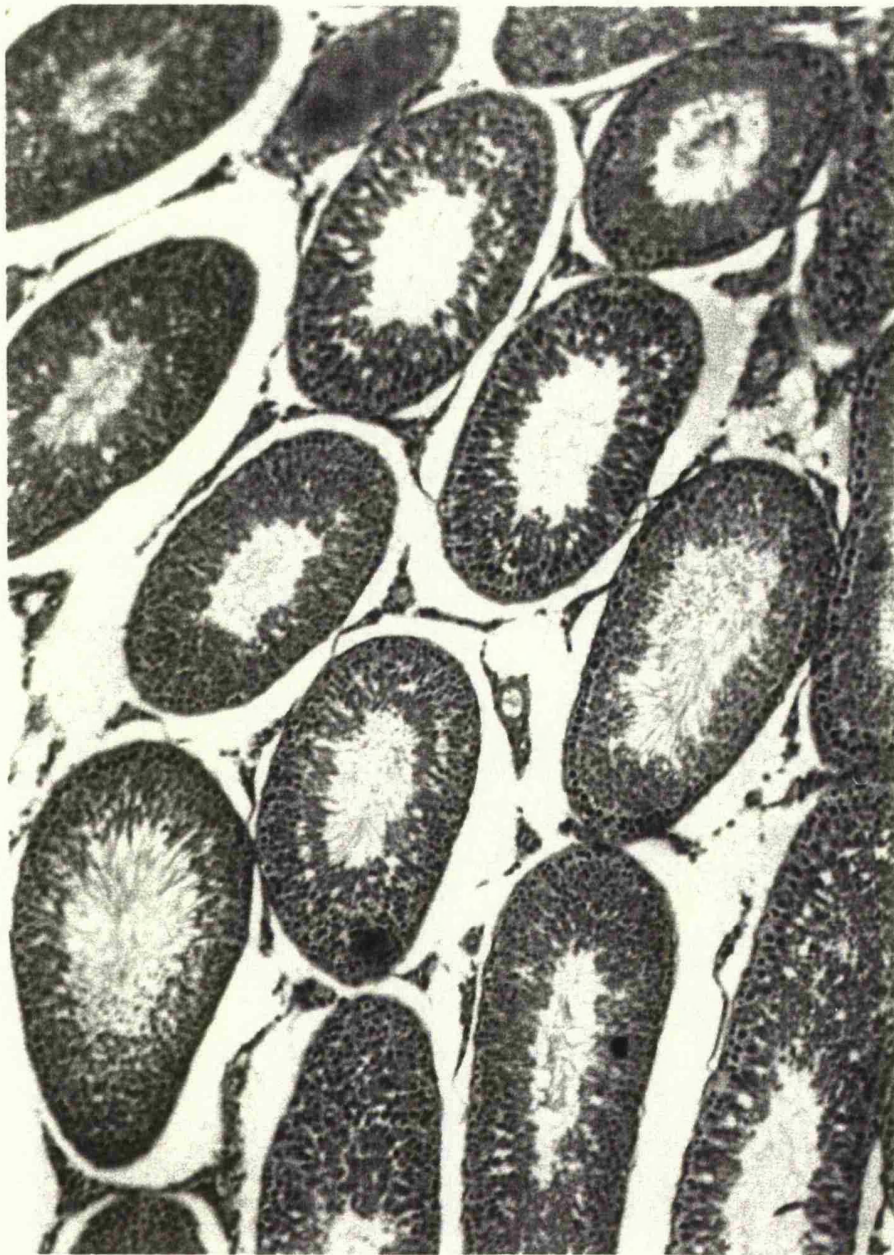

Fig 14.6A Normal rat testis with active spermatogenesis

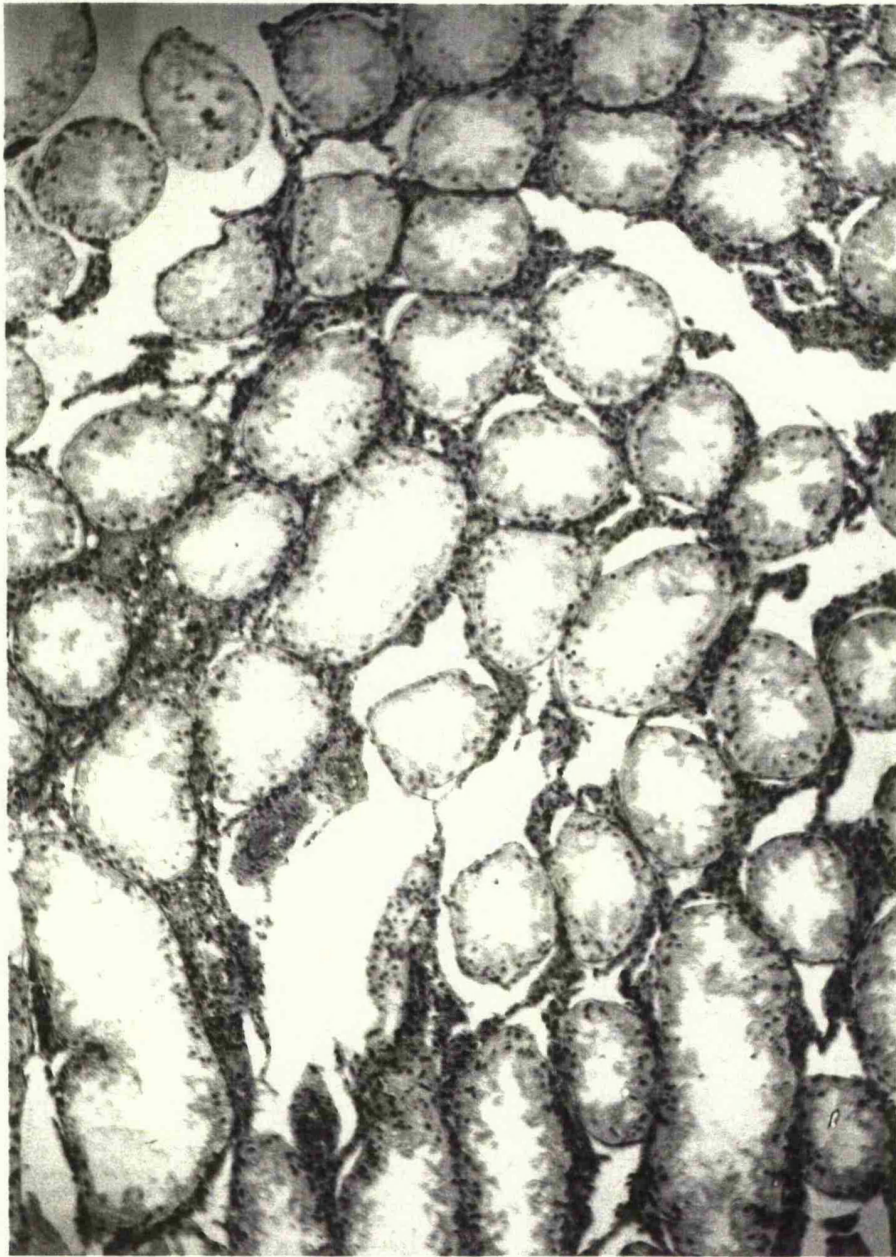

Fig 14.6B    Severe infarction of a testis following a tight inguinal repair



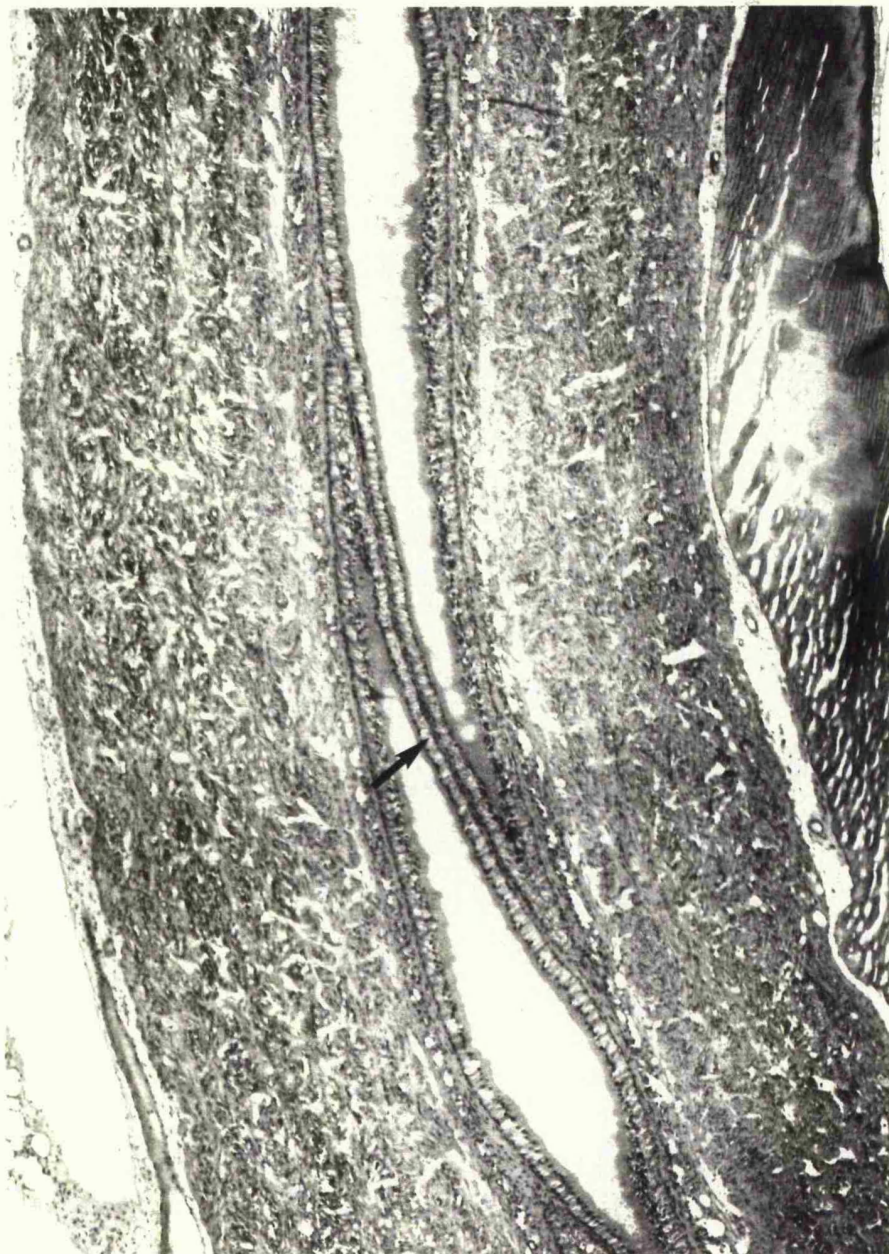

Fig 14.7A Normal rat vas deferens with an epithelial spiral (arrow) with pseudocilia and sperm in the lumen

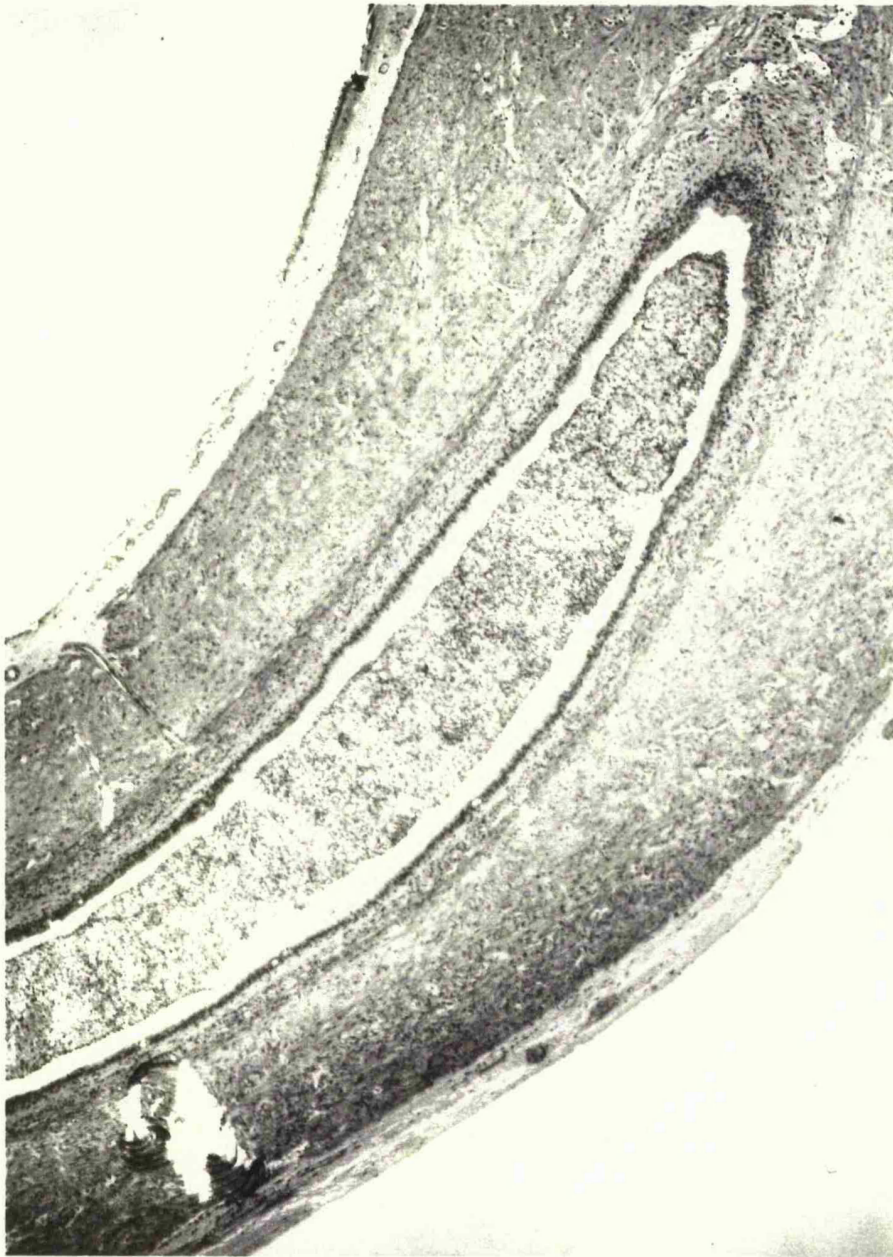


Fig 14.7B     Abnormal rat vas deferens from the inguinal region that had been stripped. There is loss of epithelial spiral, pseudocilia and absence of sperm with only cellular debris in the lumen.

## Chapter 15

### The Effect of Surgical Technique on the Mature Vas Deferens

#### Introduction

The experiments discussed in chapter 14 confirmed the increased vulnerability of the immature vas deferens. All sham operated rats (n=18) were fertile; but 22 of the remaining 34 rats (65%) were sterile. Stripping the vasa deferentia and tight inguinal reconstruction were particularly destructive with sterility rates of 78 and 100 per cent respectively.

The purpose of this further study was to determine the effect of operative manipulation on the mature vas deferens. At the same time 10 sexually immature animals were included to repeat the stripping of the vas deferens experiment as the earlier study produced such a high figure of sterility. A repeat study would validate the belief that stripping the vasa deferentia is much more destructive as the damage occurs over a longer segment with less chance of repair. This group will be discussed separately.

#### Material and Methods

Fifty-two 3 month old randomly bred male Wistar rats were divided into 9 groups (Table 15.1) and underwent similar operative manipulations as with the immature group discussed in Chapter 14. However unlike the previous study some changes to the experiment design were made.

1. Since it became clear that unoperated controls and sham operations do not appear to affect fertility; only a small number of rats were used for these groups ( control:2; sham:5) to avoid unnecessary sacrifice of animals.
2. Bilateral vasectomy was added as a new group as it is a common scrotal procedure.
3. In the group with tight repair the experimental design was altered as earlier studies demonstrated a tight repair over a 2mm diameter pin to be too damaging with 100% sterility. In view of this nylon sutures were placed so that the pin was held in place but not tightened against it. This perhaps is more representative of inguinal herniorrhaphy.
4. Vasography using saline was undertaken in the full series.
5. Fertility studies were not undertaken till the animals were at least 6 months old.
6. Since the total prostate weight includes the weight of the coagulating gland; this was not recorded as the dissection was time consuming, and this would seriously interfere with the transport of fresh tissue for the contractility and autonomic/peptidergic experiments.

Apart from group 1 the unoperated controls, all rats underwent a different operative manipulation on the right side with a contralateral vasectomy. All operations were done under full aseptic technique using intraperitoneal neuroleptanalgesia consisting of a cocktail of Hypnorm and Hypnovel . The rats were given oxygen by mask and further 1% halothane if necessary (for anaesthetic details see chap. 13). The rats were then caged separately for 3 months and at the age of 6 months underwent an extensive fertility trial; 1 male: 5 females. As before this lasted for 3



weeks which would ensure that each female would have at least 3 oestrous cycles. The presence of vaginal plugs ensured that mating took place. At the end of the fertility trial the rats were sacrificed. The presence of pregnancy and litter size and any foetal abnormality was recorded in all females.

Previous experience allowed vasography of the right vasa to be undertaken with saline. A patent vas deferens does not require any pressure to be inserted and fills the bladder easily. The use of saline should obviate any contrast damage. The weight of each testis/100g body weight was recorded. A portion of the epididymal end of the vas deferens and testis was assessed histologically blinded.

## Results

The results are summarized in Table 15.2. Complete data from this study is given in Appendix 15.1 - 15.10. There were 2 post operative deaths. Total infertility rate was 33%. The unoperated controls (gp1; n=2) and sham operation (gp2; n=5) were all fertile. Out of the remaining 43 rats 16 (37%) were sterile. Five of these had bilateral vasectomy (gp3; n=5). In essence therefore, 11 out of 38 rats with significant operative manipulation were sterile (29%). Crush injury with an arterial clip (gp4) allowed half the vasa deferentia to recanalize with a 50% sterility rate (n=2; note 1 post operative death). In group 5 (n=5) stripping the vasa caused 2 rats (40%) to be sterile. A modified tight ring reconstruction in group 6 (n=10) produced only a single sterile animal and this result was identical in group 7- loose ring reconstruction (sterility rate=10%). Stripping the vasa and tight repair of the inguinal ring (gp8; n=5) was the most damaging with 3 rats sterile

(60%). A 50% sterility was noted in group 9 (n=5) (strip + loose repair) where 2 rats were infertile (note: 1 post operative death).

There was no significant difference between the weight of the left testis/100g body weight, 0.32g and the weight of the right testis/100g body weight, 0.325g. The 2 sterile rats in groups 6&7 both had infarcted testis with a mean weight of 0.1g compared to a mean weight of 0.37g of their contralateral testis.

The reason for sterility can be seen in Table 15.3. Individual rat numbers can be identified from the data given in the appendix. Group 3 with bilateral vasectomy has been excluded as the former procedure was the clear aetiological factor. In the remaining 11 rats, the two cases with tight (F5) and loose (G8) ring reconstruction had infarcted testis. In rat F5 the vas appeared to be partially obstructed on vasography as a lot of pressure had to be applied to get any filling of the bladder. In rat G8 the vas deferens was also caught by a nylon suture which was embedded in the vas at the inguinal ring. In 7 further animals (D1,D4,E2,I4,H3,H4,H5) the vasa were obstructed on vasography and abnormal on histology. Two rats (E3,I2) had a patent vasa deferentia on vasography, normal histology of their testis and vas deferens and yet were sterile.

#### **Result from 2nd immature vas deferens study**

The complete data from this repeat experiment is given in Appendix 15.10. Five out of 10 rats were sterile resulting in an infertility rate of 50%. On this occasion the fertility trial was conducted when the animals were 6 months old instead of 11 weeks as in the earlier study. The incidence of infertility is lower than the earlier figure of 71% for the immature vas deferens, but higher than the 40% sterility rate seen with the mature vas deferens suggesting increased vulnerability of the immature vasa.



### Summary

These results confirm the importance of surgical technique during inguinal surgery. Stripping the vas together with inguinal reconstruction (gps.8&9) remains destructive with an incidence of 50% sterility. The incidence of infertility however is much lower in comparison to the immature vas deferens of 29% vs 65% suggesting the vulnerability of the immature vas, and the ability of the mature animal's vasa to sustain damage and repair itself.

**Table 15.1:**

**Details of Operative Procedures in Groups 1-9**

<b>Group no.</b>	<b>No. of rats</b>	<b>Operative procedure on right side</b>
1	2	Nil
2	5	Sham
3	5	Bilateral vasectomy
4	5	Crush injury arterial clip 30 secs.
5	5	Strip the vas
6	10	Tight ring reconstruction 2 mm. diameter pin
7	10	Loose ring reconstruction 4 mm. diameter pin
8	5	Strip vas + tight repair inguinal ring
9	5	Strip vas + loose repair inguinal ring

Note: Gps. 2-9 vasectomy performed on left side

**Table 15.2: Results of Adult Fertility Trial**

operated rats 50 - 2 deaths  
 number of infertile rats - 16  
 infertility rate - 33%

Group and number of rats	Number infertile	Infertility rate
clip (5)	2 -1 death	50%
strip (5)	2	40%
tight ring reconstruction (10)	1	10%
loose ring reconstruction (10)	1	10%
strip + tight ring reconstruction (5)	3	60%
strip + loose ring reconstruction (5)	2 - 1 death	50%

**Table 15.3: Reason for Sterility in Adult Trial**

sterile rats - 16

bilateral vasectomy - 5

Group	Abnormal vas	Abnormal testis	Normal vas and testis
clip (2)	2	-	-
strip (2)	1	-	1
ring	-	2	-
reconstruction (2)			
strip + tight	2	1	-
repair (3)			
strip +	1	-	1
loose repair (2)			

## Chapter 16

### The Effect of Inguinal Surgery on the Autonomic and Peptidergic Innervation of the Vas Deferens

#### Introduction

As discussed in chapters 6 & 7 previous studies have examined the origin and distribution of the autonomic fibres (Noradrenergic and cholinergic: acetyl cholinesterase- positive fibres); and peptidergic innervation. The latter studies have especially concentrated on Vasoactive Intestinal Polypeptide (VIP) and substance P. Other potential peptide neurotransmitters such as enkephalin (Alm et al. 1982) and neuropeptide tyrosine (Sternquist et al. 1983), have been observed in the female reproductive organs of the mammalian species (Papka et al. 1985). Sparse attention appears to have been given to the vas deferens and the literature is notable by the absence of any study on post operative specimens.

This investigation is an immunohistochemical study to determine the distribution of Neuropeptide Y, Vasoactive Intestinal polypeptide, acetyl cholinesterase- positive and noradrenergic nerves in the vas deferens of the Wistar rat. The second part concerns the changes in the density of the autonomic and peptidergic innervation induced by surgical trauma.

#### Material and methods

The animals used in this study belong to the second fertility study where mainly mature Wistar rats which were used to determine the effect of surgical technique on infertility (Chap. 15). Twenty-two adult wistar rats (32 vasa deferentia) were entered into the study. The procedures that each

vasa had undergone are shown in Table 16.1 . In group 1, 3 vasa deferentia which were unoperated upon served as controls. Group 2, comprised of 10 contralateral vasa deferentia from other groups that had undergone a standard vasectomy. In the vasectomy group it is the proximal (urethral end) vas which has been examined in these animals as the distal segments were damaged by shrinkage, fibrosis and sperm granulomas. Crush injury to the vas deferens was applied for 30 seconds to 2 vasa deferentia in group 3. In group 4, the vas deferens was stripped by means of sharp and blunt dissection in 6 vasa . A tight hernia repair was simulated by tight ring reconstruction over a 2mm diameter pin (group 5) in 3 vasa deferentia. A looser hernia repair was simulated by ring reconstruction over a 4mm diameter pin with 3 vasa deferentia (group 6). In groups 7 and 8 the vasa deferentia were stripped out as in group 4 but also underwent tight and loose repair in 2 and 3 vasa deferentia respectively. All operations were performed under full aseptic technique using intraperitoneal neuroleptanalgesia (see chap. 13 for details). The subsequent fertility trial is described in chapter 15 .

One half of each specimen of vas deferens was studied histochemically to demonstrate catecholamines containing Acetylcholinesterase- positive nerves while the remaining half was studied immunohistochemically for the localisation of Vasoactive Intestinal Polypeptide (VIP), Neuropeptide Y (NPY) and Dopamine -B- Hydroxylase (DBH).

#### Neuro-Histochemistry

##### Catecholamine Fluorescence

Portions of tissue were immersed in a freshly prepared solution of 2% w/v glyoxylic acid in 0.1 M phosphate buffer (pH 7.0) at room temperature for 1.5 hours. Transverse and longitudinal cryostat sections (10µm) of the vas

were air-dried at room temperature for 30 seconds, placed in fresh glyoxylic acid solution for 1-2 minutes at 4°C, dried for 10 minutes at 37°C and incubated at 100°C for 6 minutes. The sections were then viewed with an Olympus microscope fitted with epifluorescence.

#### **Acetylcholinesterase histochemistry**

Both transverse and longitudinal cryostat sections (10µm) of vas were fixed in 10% formalin and 1% calcium chloride, and acetylcholinesterase (AChE) activity subsequently localised according to the method of Gomori (1952). Non-specific cholinesterase activity was inhibited by preincubation in  $10^{-5}$  M tetraisopropylpyrophosphoramidate before transferring to the incubating medium containing the substrate acetylthiocholine iodide (Boehringer). After counterstaining with haematoxylin the sections were viewed using bright field microscopy.

#### **Immunofluorescence**

VIP, NPY and DBH, immunoreactive nerves were demonstrated by using the indirect fluorescence technique (Gomori 1952). Small portions of vas deferens were fixed at room temperature in 4% p-benzoquinone in phosphate-buffered saline (PBS) for 2 hours. The tissues were then thoroughly washed with 7% sucrose in PBS containing 0.01% sodium azide and stored for 24 hours at 4°C. 10 µm cryostat sections were incubated for 18 hours at room temperature with polyclonal antisera to VIP (ICN), NPY (IDS) and DBH (Eugene Tec) raised in rabbits, at dilutions of 1 : 500 (for VIP) and 1 : 250 for the remainder. All the antisera showed no cross-reactivity to other peptides (suppliers notice).

Sites of antigen-antibody reaction were revealed by incubating for 1 hour at room temperature with goat anti-rabbit antiserum, conjugated to

fluorescein isothiocyanate (FITC) diluted 1 : 100 (ICN). The preparations were washed, mounted with glycerol: PBS (1 :1) and viewed in an Olympus microscope equipped with epifluorescence.

For the controls the the tissue sections were incubated with non-immune rabbit serum in place of the primary antiserum and were incubated with antibody inactivated by the addition of excess antigen (10 nmol per ml of diluted antiserum). Cross-reactive tests were carried out by incubating each antibody with inappropriate peptides or amines.

### Histology

Some 10  $\mu$ m cryostat sections were stained by Masson's trichroma method for routine histology.

### Results

The results discussed here relate only to the autonomic and peptidergic innervation of vas deferens from the control and experimental groups of the Wistar rat. The results of the fertility trial are described in chapter 15. The fertility data from these 22 rats is given in appendix 16.1. A full cross section of surgical procedures has been performed with 13 fertile and 9 sterile rats. In particular there is a bias towards stripping the vas and ring reconstruction as these have been found in earlier studies to be the most damaging.

The density of the autonomic and peptidergic innervation of the control and experimental groups is shown in Fig 16.1. Noradrenergic innervation of the vas is mainly in the muscle but there are significant amounts in the sub-epithelial plexus (Fig 16.2). This appears to be identical with Neuropeptide Y



which has dense innervation of the muscle (Fig 16.3) in contrast to the subepithelial plexus (Fig16.4). Conversely the parasympathetic innervation as demonstrated by the acetylcholinesterase positive nerves is rich in the sub-epithelial plexus and very sparse in the muscle (Fig16.5). This is again identical with vasoactive intestinal polypeptide - rich in the sub-epithelial plexus, sparse in the muscle (Fig16.6).

As shown in Fig 16.1 the distribution of the autonomic and peptidergic innervation was similar in the experimental groups and on fluorescent photographs decreased in comparison to the control animals however there was no statistically significant difference between the groups. The number of animals is too small to make any valid comment regarding any differences between the sterile and fertile animals (Fig16.7). Examples of vas deferens neuropeptide granules on electron microscopy from the subepithelial and muscle plexus are shown in Figs 16. 8 - 16.10.

### Discussion

The muscle of the Wistar rat vas deferens has a very rich sympathetic innervation to allow for the powerful contractions to occur. Neuromodulation of this by NPY is possible as it has an identical distribution to the sympathetic innervation. As expected the parasympathetic system is mainly in the sub-epithelial plexus. VIP appears to mirror the parasympathetic system and together they may have a role in vas repair and regeneration, secretory aspects of the vas deferens and phagocytic activity for dead sperm. It appears therefore that perhaps NPY modulates the sympathetic system and VIP the parasympathetic system.

The distribution of the autonomic and peptidergic innervation appears to be similar between the control and experimental animals. Because the numbers are small although there appears to be decreased density in the

experimental groups (Fig16.1) statistically there was no difference; and this appears to be the same on comparing the sterile and fertile animals (Fig16.7). It would however be reasonable to suggest that damage to the autonomic and peptidergic innervation of the vas deferens may reach a critical level and interfere with sperm transport although we have no direct proof of this.

**TABLE 16.1 Group numbers and procedures undertaken  
on the 32 vasa deferentia**

Group no.	Number of vasa	Procedure undertaken
Gp 1	3	Skin incision - controls
Gp 2	10	Vasectomy (contralateral vasa from other groups )
Gp 3	2	Crush injury
Gp 4	6	Strip
Gp 5	3	Tight inguinal reconstruction - over 2mm diam. pin
Gp 6	3	Loose inguinal reconstruction - over 4mm diam. pin
Gp 7	2	Strip and tight repair
Gp 8	3	Strip and loose repair

Rat	Neuropeptide $\gamma$		Dopamine - $\beta$ - hydroxylase		Vasoactive intestinal polypeptide		Acetylcholinesterase positive	
	muscle	sub -epithelium	muscle	sub -epithelium	muscle	sub -epithelium	muscle	sub -epithelium
Control Rats	+++++	+++	++++	+++	+	+++++	+	++++
Experimental groups	+++	++	++++	+++	+	++++	+	+++

Fig16.1 The density of the autonomic and peptidergic innervation in the control and experimental groups of the Wistar rat

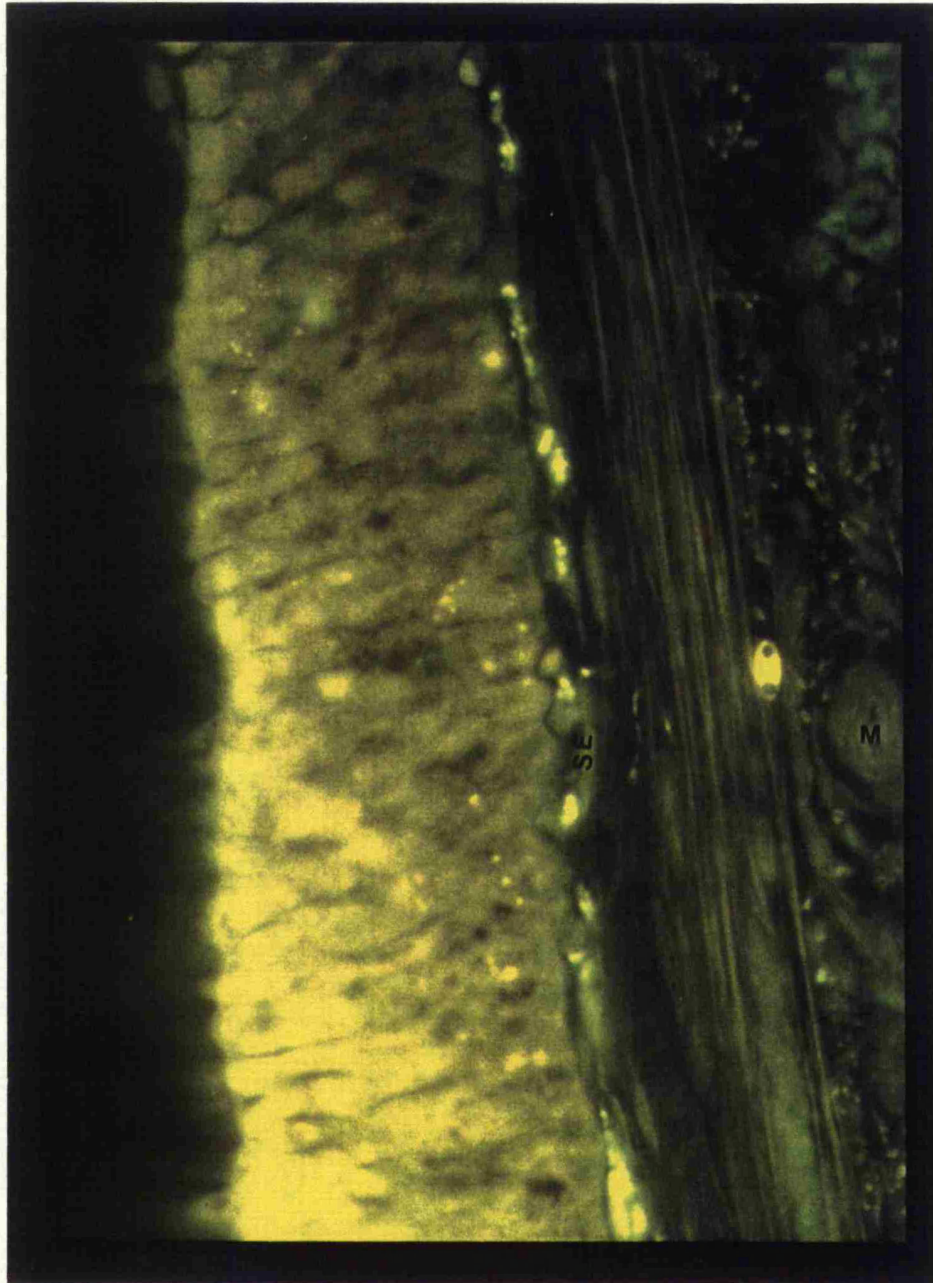


Fig 16.2      Reduced density of noradrenergic innervation of the sub-epithelial plexus (se) of the vas deferens in comparison to the muscle (m).

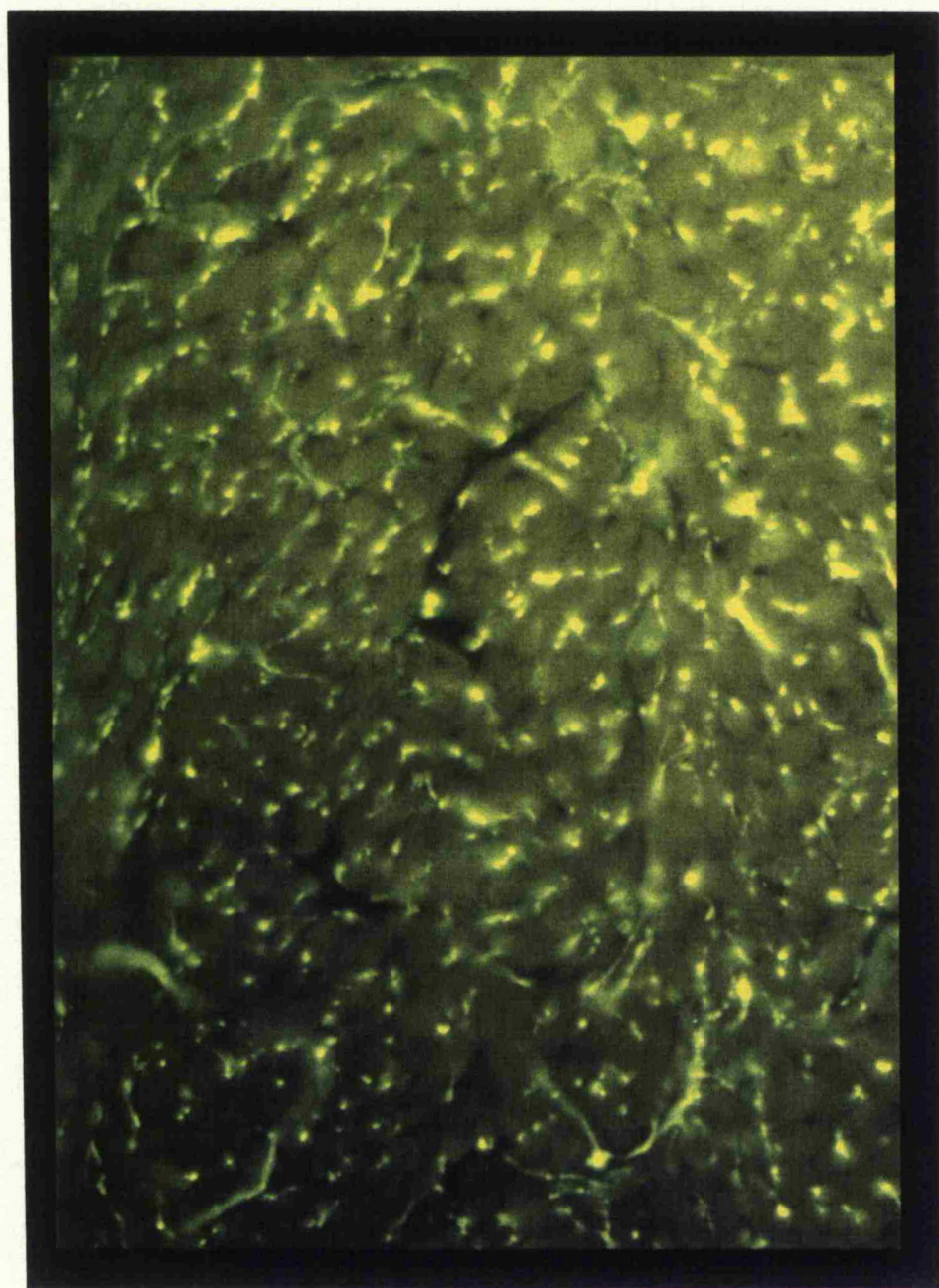


Fig 16.3 Dense Neuropeptide Y innervation of the vas deferens muscle



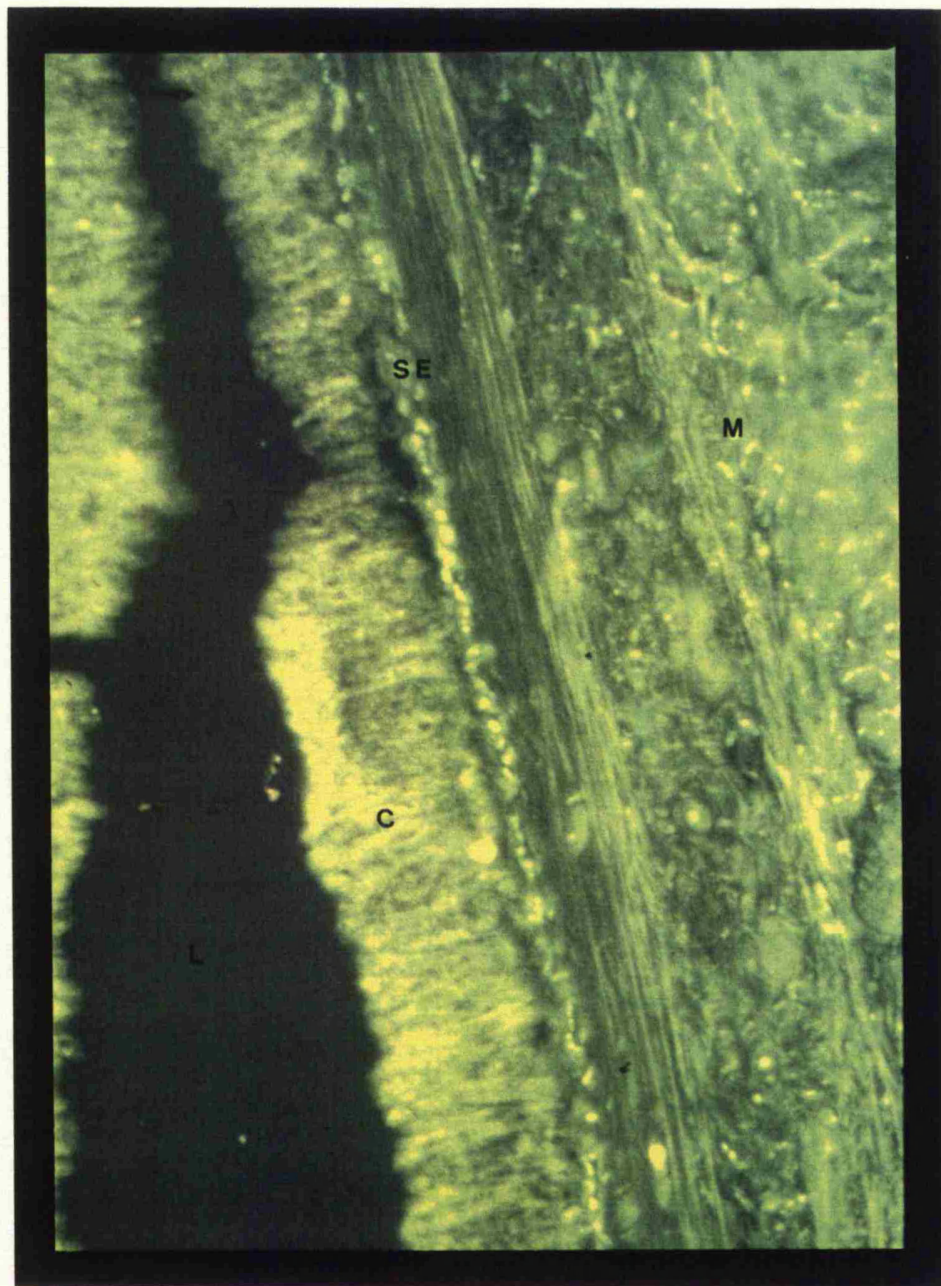


Fig 16.4      Neuropeptide Y appears to have an identical distribution to the noradrenergic nerves with dense innervation of the muscle (**m**) in contrast to the sub-epithelial plexus (**se**). [ l- lumen; c- cilia)

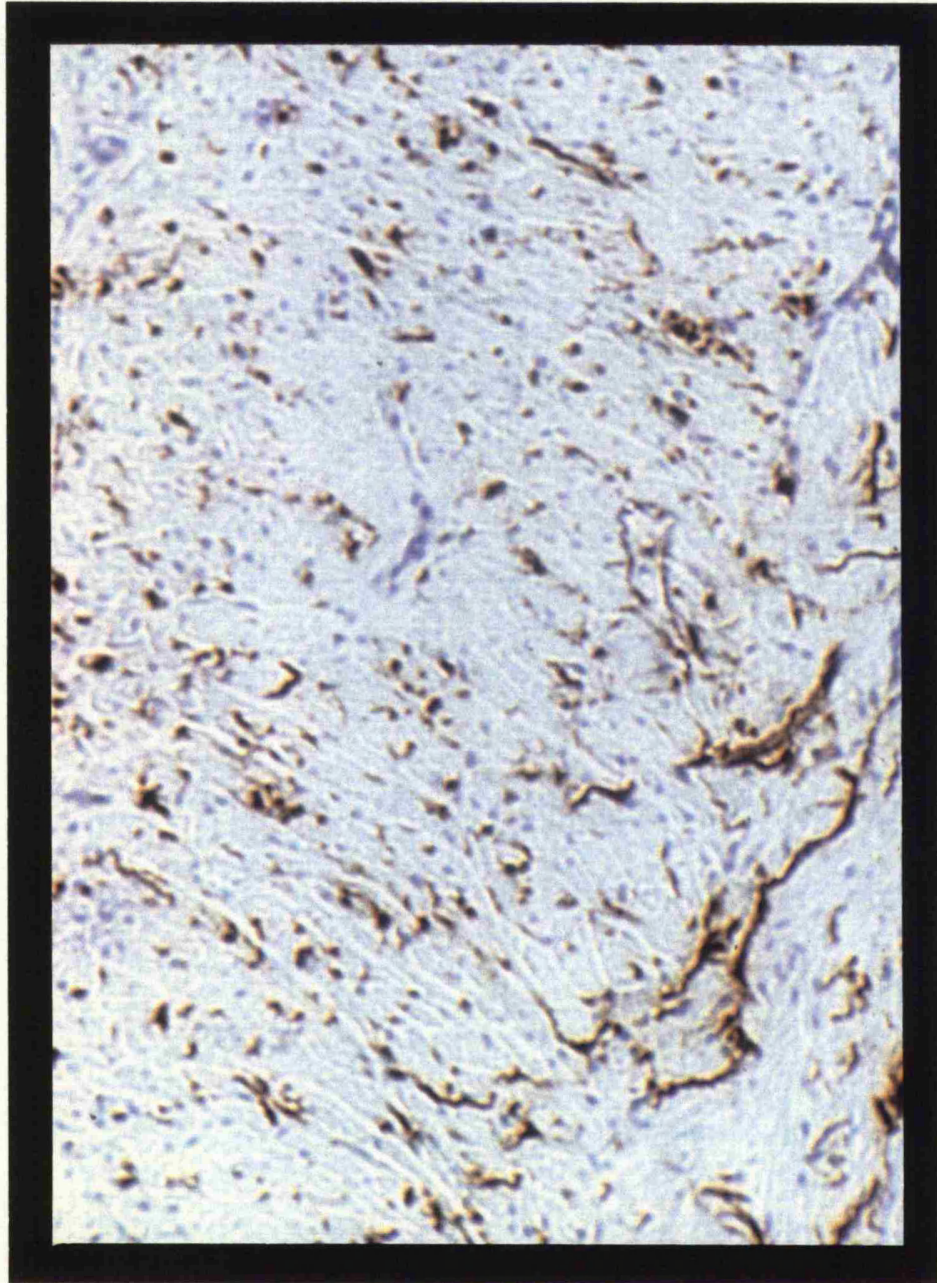


Fig 16.5 Sparse distribution of acetylcholinesterase positive nerves (parasympathetic system) in the muscle.



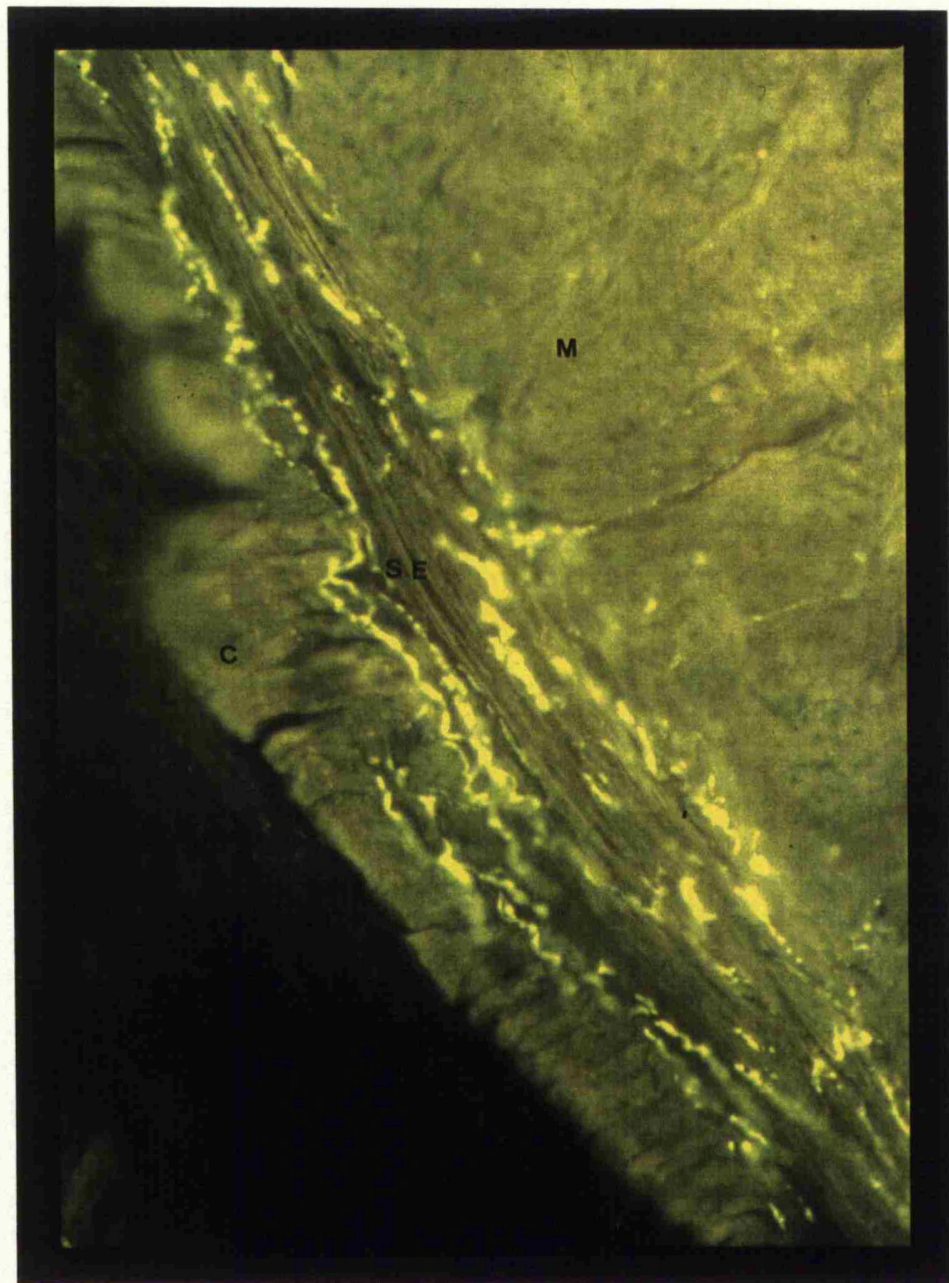


Fig 16.6 Dense innervation of vasoactive intestinal polypeptide in the subepithelial plexus (se) and virtually absent in the muscle (m). [ l- lumen; c- cilia]

Rat	Neuropeptide Y		Dopamine - $\beta$ - hydroxylase		Vasoactive intestinal polypeptide		Acetylcholinesterase positive	
	muscle	sub -epithelium	muscle	sub -epithelium	muscle	sub -epithelium	muscle	sub -epithelium
Control Rats	+++++	+++	++++	+++	+	+++++	+	++++
Fertile expt. rats	+++++	++	++++	++	+	++++	+	++++
Sterile expt. rats	++++	++	++++	++	+	+++	+	+++

Fig 16.7 The density of the autonomic and peptidergic innervation of the fertile and sterile Wistar rats

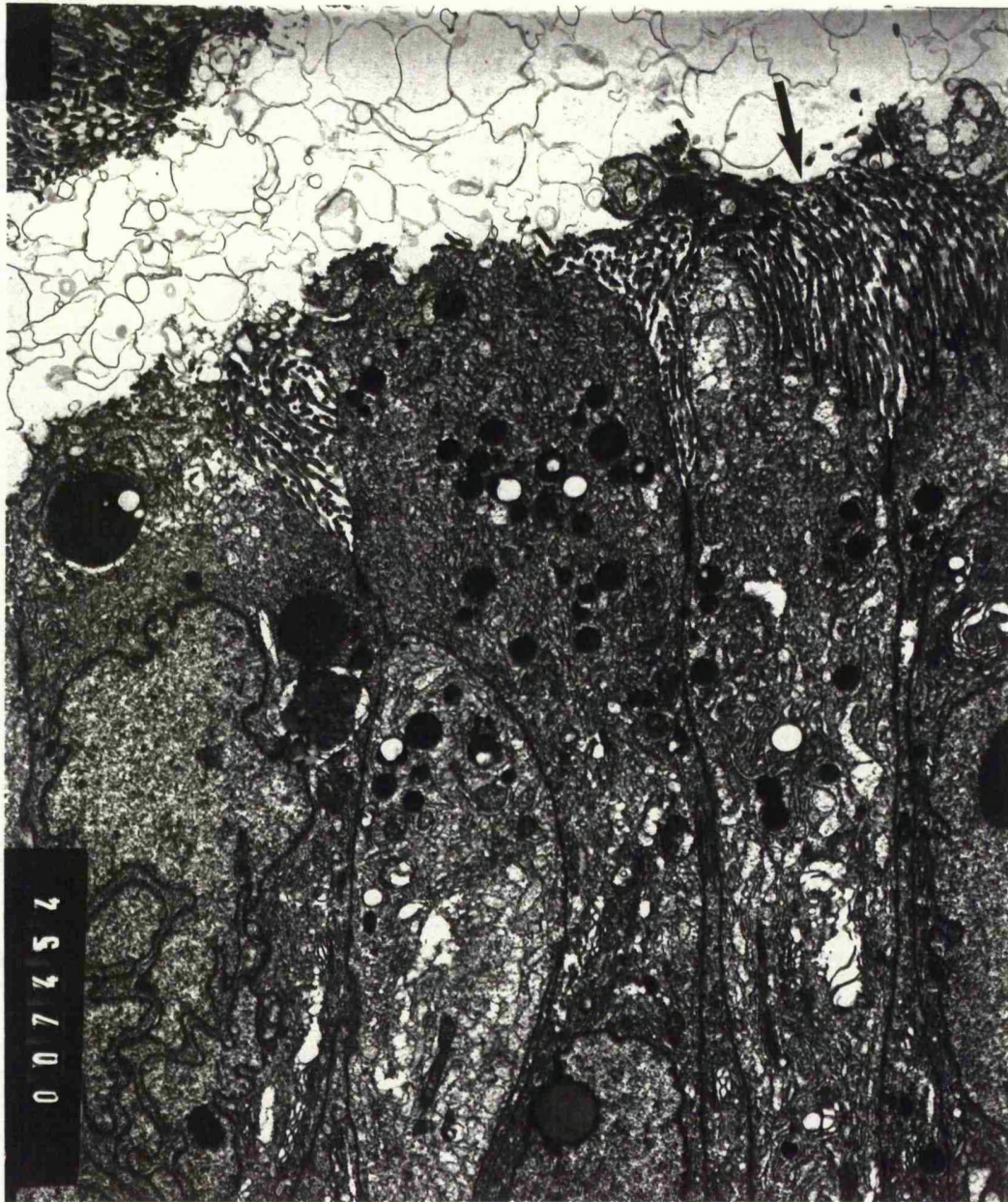


Fig 16.8 Pseudocilia of the epithelium of the rat vas deferens (arrow) as seen on electron microscopy



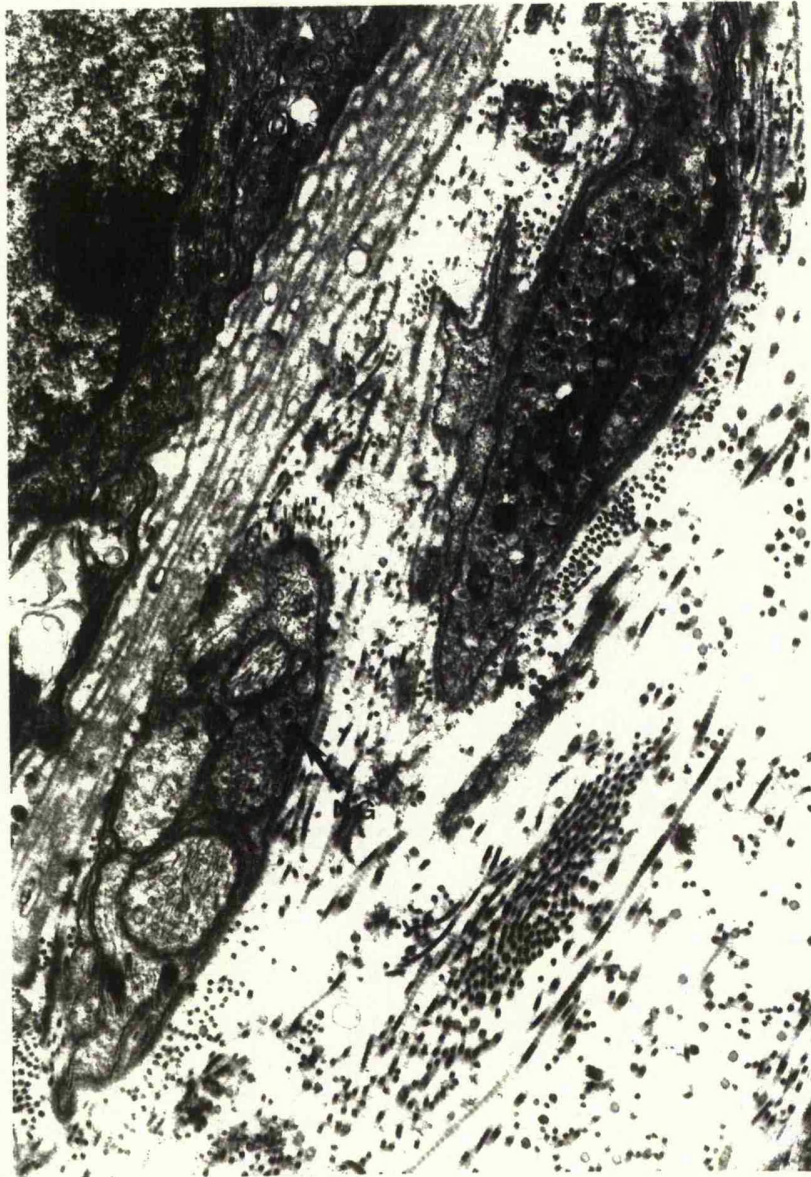


Fig 16.9      Neuropeptide granules (ng) on electron microscopy in  
the subepithelial plexus (arrow) of the rat vas deferens

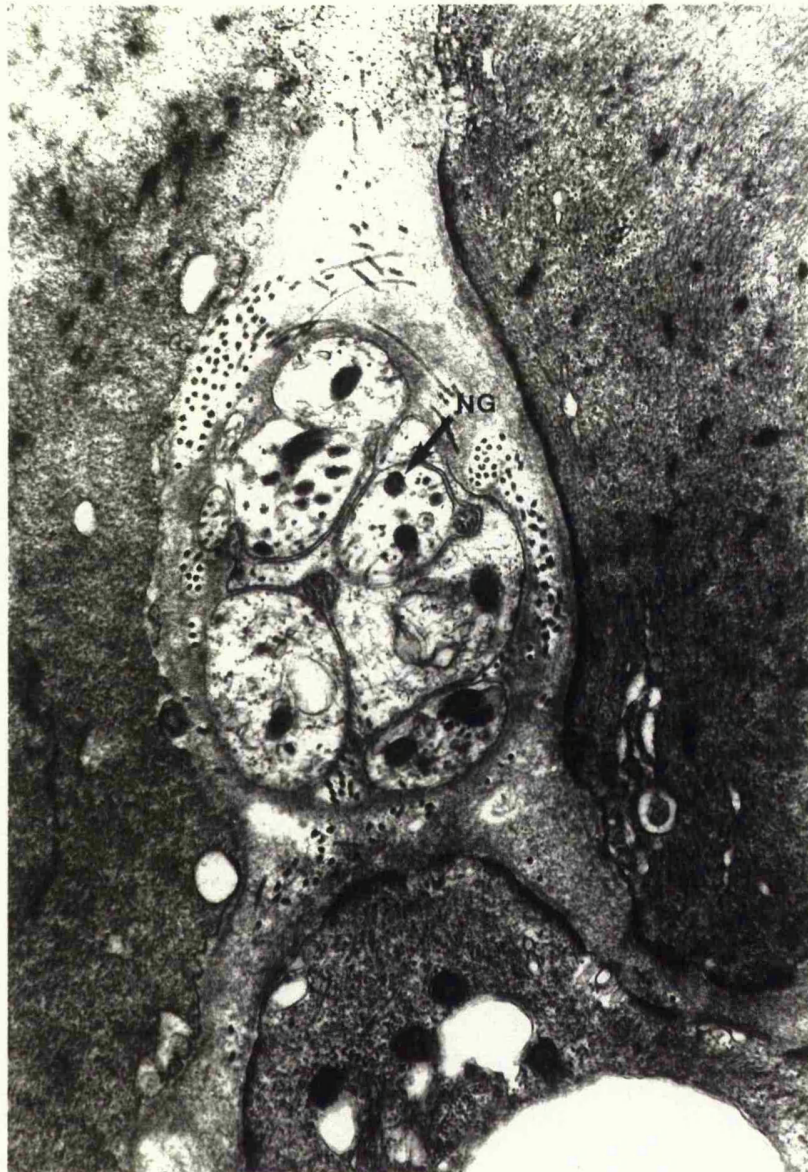


Fig 16.10    Neuropeptide granules (ng) on electron microscopy in  
the muscle (arrow) of the rat vas deferens

## Chapter 17

### The Effect of Surgical Technique on the Contractility Properties of the Vas Deferens

#### Introduction

Sperm transport in the male genital tract is complex. The vas deferens is a dynamic structure with specialised epithelial spiral and pseudocilia with a dense adrenergic innervation of its 3 muscular coats, together with sub-epithelial innervation by acetylcholinesterase positive nerves. Spermatozoa are stored in the epididymis with only possibly 2% being stored in the epididymal portion of the vas deferens. During development in the seminiferous tubules, immature spermatozoa are incapable of self propulsion; transport out of the testes is accomplished by a combination of rete fluid pressure and the action of cilia lining the ductuli efferentes. During their transport through the epididymis, spermatozoa mature and become capable of motility. Spermatozoa in the caput epididymis remain viable for long periods of time because they are immotile and therefore maintain a low metabolic rate. The final maturation process occurs in the cauda epididymis and the epididymal portion of the vas deferens. Hence sperm are itinerant cells which once on the move, must adjust to a continuously changing and specialised environment from the composition of testicular fluid to epididymal plasma and semen. In ejaculation the spermatozoa from the vas deferens and from the tail of the epididymis are rapidly forced into the urethra by muscular contractions of the duct walls, mingling with the secretions of certain accessory glands whose ducts lead into the terminal part of the vas deferens or into the urethra. The male accessory glands in man and several species consist of

the ampullary glands, the seminal vesicles, the prostate, the urethral or Littre's glands, the bulbo-urethral or Cowper's glands. The contributions from these sources with secretions from the testes, epididymis and vas deferens, and the suspension of the spermatozoa, together constitute the semen. The contractile properties of the vas deferens is an important part of sperm transport and operative handling may effect this prime function. To examine this the wistar rat model has been utilized to determine what effect operative manipulation of the vas has on contractility and this has been correlated with the fertility status of the animal.

#### **Material And Methods**

The animals used in this study belong to the mature vas deferens fertility trial (see details in chapter 15). Fifteen wistar rats (13 adult 255-325g and 2 immature rats 105g) underwent different operative manipulations as shown in Table 17.1. Apart from 2 unoperated controls all rats underwent a vasectomy on the left side and a different operative manipulation on the right side. Rat numbers 3 and 4 had only a skin incision made. Rat number 5 had a bilateral vasectomy performed. Rat numbers 6 and 7 had crush injury to the vas deferens by the application of an arterial clip for 30 seconds. In 3 rats, 1 adult and 2 immature rats (numbers 8,9 & 10) the vas deferens was stripped by means of sharp and blunt dissection as may inadvertently occur in an attempt to dissect out a hernial sac. As described earlier a loose herniorrhaphy repair was simulated by an inguinal ring reconstruction over a 4mm diam. pin in rat number 11. A tight herniorrhaphy repair was simulated in rat number 12 over a 2mm diam. pin. Stripping the vas (rat no. 13) together with loose and tight repair was undertaken in rat numbers 14 & 15 respectively.

All operations were performed under full aseptic technique using intraperitoneal neuroleptanalgesia consisting of a cocktail of Hypnorm (Fentanyl Citrate 0.315mg + Fluanisone 10mg/ml) and Hypnovel (Midazolam HCL 10mg/2ml). The rats were given oxygen by mask and further 1% halothane if necessary (details in chapter 13). These fifteen male rats were then allowed to recover and mature for a further 5 months. After this each male rat was caged with 5 female rats. This extensive fertility trial lasted for 3 weeks, during which the female had at least 3 oestrous cycles. The presence of vaginal plugs confirmed mating. At the completion of the fertility trial the rats were sacrificed. The presence of pregnancy, litter size and any foetal abnormality was recorded. The absence of pregnancy in all 5 female wistar rats denoted a sterile male rat. The weight of each testicle per 100g body weight was recorded. Histological assessment of the testes was undertaken to confirm adequate spermatogenesis.

At the time of sacrifice the rats were killed with a blow on the head and exsanguination. Both vasa deferentia were rapidly dissected and incubated in Kreb's solution (Table 17.2) for 1 hour at 37°C. They were then suspended under 0.05g tension in 50ml organ bath containing Kreb's solution which was continuously gassed with 95% O<sub>2</sub> : 5% CO<sub>2</sub>. One and a half cms of the experimental portion of the vas deferens was used with the prostatic end held upwards. The vas deferens was passed through parallel ringed platinum electrodes (Fig 17.1) and contractions were elicited by supra maximal field stimulation (frequency of 5Hz with a pulse width of 0.5 millisecond and a voltage stimulus of 20 volts). Contractions were recorded isometrically using a strain gauge and an ultraviolet oscillograph.



## Results

The fertility data is summarised in Table17.1. Six out of these 15 rats (40%) were sterile. (The histological data of the testis together with vasography findings is given in Table17.3). Rat number 5 with bilateral vasectomy was sterile for obvious reasons. However, apart from possible damage to the vas deferens in rat number 9 & 12 the right testis in both these cases underwent infarction. Hence out of the 6 rats that were sterile 3 had normal testes with active spermatogenesis and in the presence of normal sexual activity it is likely that the vas damage is the primary cause of their sterility. Contractility data is only available on 28 vasa deferentia as with rat number 6 there was an apparatus failure. For each vas deferens the 3 best contractions were summated to give a mean value for the peak and tonic contractions. This is shown in Appendix 17.1. The corresponding value in terms of grams tension is shown in Table17.4. Figures 17.2 - 17.9 are examples of the response of the vas deferens to supra maximal field stimulation in the various groups. There was a significant difference in the peak contraction response of control vas deferens compared with the operative side;  $p < 0.001$  (Fig17.10). Vasa deferentia that underwent vasectomy also responded poorly to field stimulation compared with controls. The fertile vas demonstrated powerful rapid contractions compared with the sterile vasa deferentia; with a significant difference between sterile and fertile vasa deferentia at  $p = 0.028$ . These results are mirrored by the tonic contraction response for the respective groups as shown in figure 17.11.

## Discussion

Sperm transport is an important pre-requisite of conception. However, this includes a number of other important factors such as copulatory behaviour, the anatomy of the male genital tract, site of insemination, physiological and biochemical characteristics of the semen and the secretions of the female tract so few generalisations can be made.

The epididymal portion of the vas deferens together with the cauda epididymis has three special roles consisting of storage and maturation of spermatozoa and sperm transport. To enable this to happen the wistar rat vas has 3 muscular coats an inner and outer layer of longitudinal muscle with central circular muscle and epithelial pseudocilia. Distinct from the human vas it also has an epithelial spiral to promote efficient contractility and emptying of the vas deferens lumen. Supramaximal field stimulation produces a classical biphasic response (Fig.17.2). This is largely due to the dense adrenergic innervation of the smooth muscle of the vas. In particular over the last few years transmural nerve induced contractions have proved useful in assaying compounds which are alpha adrenoreceptor antagonists such as Prazosin (see Chapters 10 & 11). Hence this proven useful model can be used to determine the effect of operative handling on vas deferens contractility and directly on sperm transport. The nerve supply of the vas deferens is very superficial and therefore may be easily damaged. The small pulse width that has been used ensures that only the nerves are stimulated and not the muscle. Stripping the vas and in particular ring reconstruction appears to be particularly destructive leading to sterility. Out of the 6 cases of sterility (Table 17.3) in two rats (no.9&12) the testis was infarcted. In rat number 5 sterility was due to bilateral vasectomy. However, the other 3 vasa with normal testes on histology are likely to have suffered vas damage. Vasography using saline

undertaken in these vasa deferentia from the urethral end demonstrated a block in the vas in rat Nos 6 & 15 however in No 13 the vas was patent and the testis was normal. Previous work using this experimental model has already demonstrated that occasionally after operative manipulation a histologically normal looking vas and testis may still lead to an infertile animal. This mirrors the clinical problem of azoospermia after hernia repair despite normal testis biopsy and vasogram. The total number of animals studied here are too small to make any comparisons between the different operative manipulations but these results support our previous experience that full vas mobilisation and stripping the vas together with ring reconstruction is particularly destructive. The control vasa deferentia had enormous contractions; while any vas that underwent a vasectomy or an operative manipulation both the rapid and tonic contractions were seriously diminished. In this experiment there was no difference between the vasectomy and operative groups. The reason for this is that to perform a vasectomy involves considerable amount of dissection and equivalent amount of trauma and hence the vasectomy and operative manipulation groups are comparable.

In this study we have shown the vulnerability of the vas deferens to inadvertent damage and subsequent contractility. This may seriously affect sperm transport. These results again indicate the great care needed in handling the vas deferens during inguinal operations.

**TABLE 17.1      Fertility   Status**

<b>Rat No.</b>	<b>Right Vas Operative Procedure</b>	<b>Left Vas Operative Procedure</b>	<b>Fertility Status</b>
1	Control	Control	Fertile
2	Control	Control	Fertile
3	Skin incision	Vasectomy	Fertile
4	Skin incision	Vasectomy	Fertile
5	Vasectomy	Vasectomy	Sterile
6	Clip (Apparatus Failure)	Vasectomy	Sterile
7	Clip	Vasectomy	Fertile
8	Strip (Adult)	Vasectomy	Fertile
9	Strip (Immature)	Vasectomy	Sterile
10	Strip (Immature)	Vasectomy	Fertile
11	Loose Repair	Vasectomy	Fertile
12	Tight Repair	Vasectomy	Sterile
13	Strip + Loose Repair	Vasectomy	Sterile
14	Strip + Tight Repair	Vasectomy	Fertile
15	Strip + Tight Repair	Vasectomy	Sterile

TABLE 17.2

**Composition of Krebs Solution**

Na Cl 6.92 g/l

K Cl 0.35 g/l

NaH CO<sub>3</sub> 2.10 g/l

NaH<sub>2</sub> PO<sub>4</sub> 0.18 g/l

Glucose 1.98 g/l

Ca Cl<sub>2</sub> 2.1 mls of 1 molar solution

Hg Cl<sub>2</sub> 1.1 mls of 1 molar solution

TABLE 17.3

Rat number	Procedure performed	Findings on vasography	Testis histology
5	bil. vasectomy	block	normal
6	clip	block	normal
9	strip	block	infarction
12	tight ring	patent	infarction
13	strip+loose repair	patent	normal
15	strip+tight repair	block	normal

*Details of vasography and testis histology from the 6 sterile rats*

TABLE 17.4

Category	No. of vasa	Mean rapid contraction in mm.	Mean rapid contraction tension	Mean tonic contraction in mm.	Mean tonic contraction tension
Control	6	95	2.38g	41	1.03g
Vasectomy	12	20	0.50g	5	0.13g
Right operative side	10	22	0.55g	5	0.13g
Right operative side sterile	5	14	0.35g	3	0.08g
Right operative side fertile	5	30	0.75g	8	0.2g

Results of vas deferens isometric contraction in grams tension


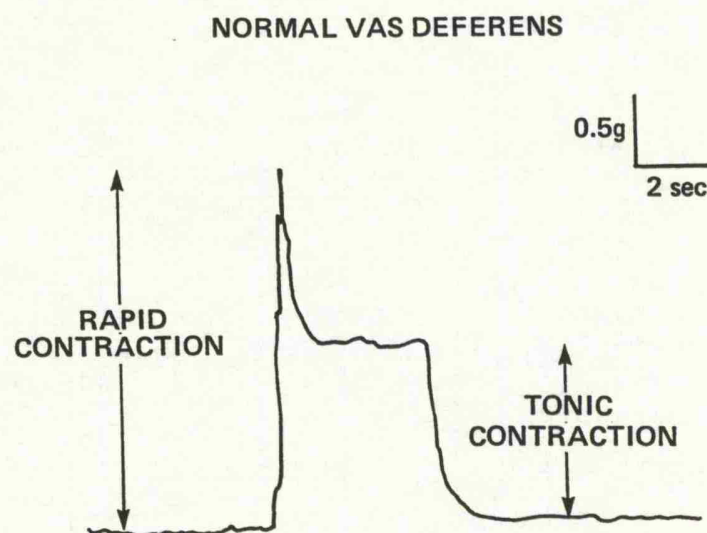


Fig 17.1      Vas deferens attached to a strain guage and suspended in Kreb's solution between ringed platinum electrodes and contractions elicited by supra maximal field stimulation.





**Fig 17.2** Rapid and tonic response of the vas deferens to supra maximal field stimulation with a frequency of 5 Hz, pulse width of 0.5 millisecond and a voltage stimulus of 20 volts

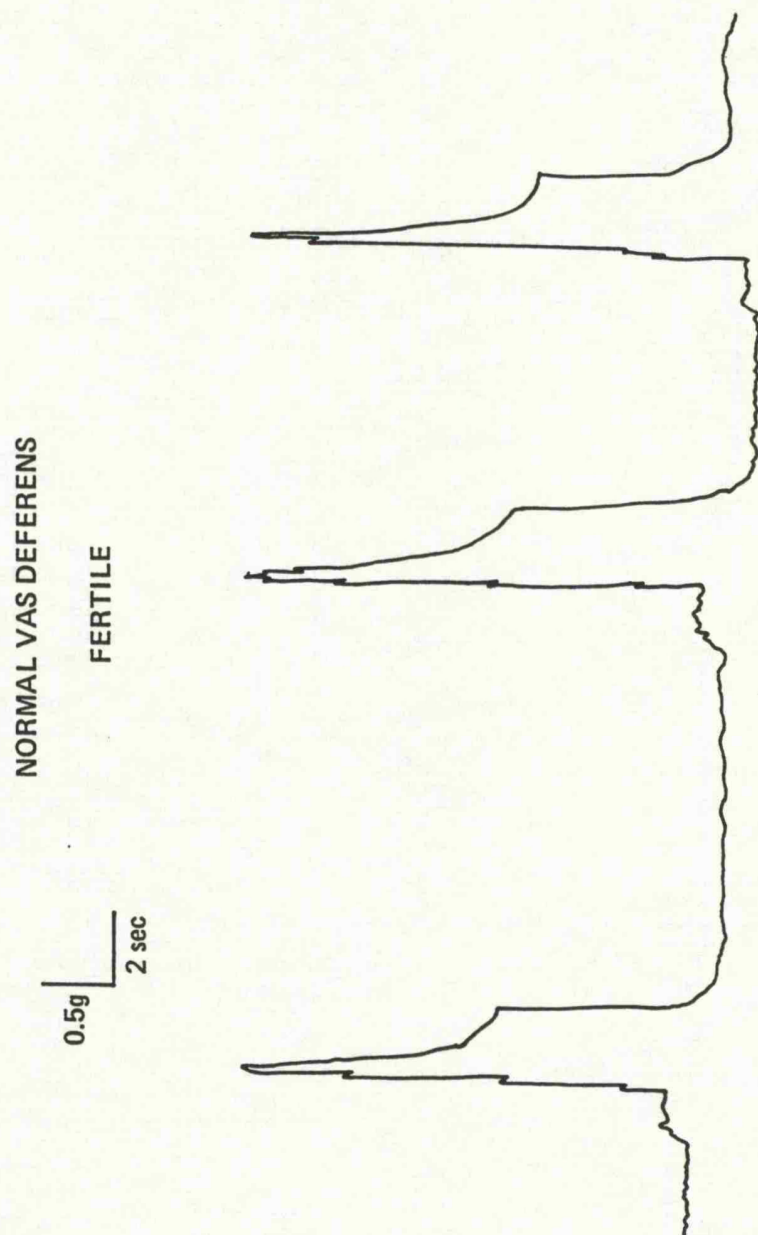


Fig 17.3 A run of powerful contractions from a control vas deferens.  
The scale is 50% reduced compared with the operative groups

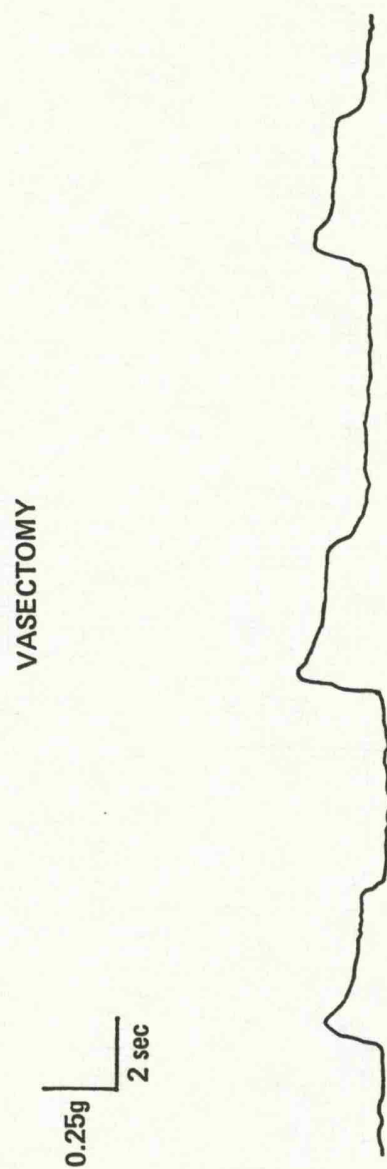


Fig 17.4 Vasectomy is a significant operative manoeuvre and produces diminished contractions

STRIP  
STERILE

0.25g  
2 sec

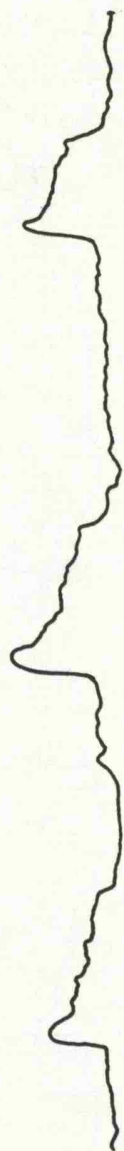


Fig 17.5 Poor contractions from a vas that has been stripped and associated with sterility

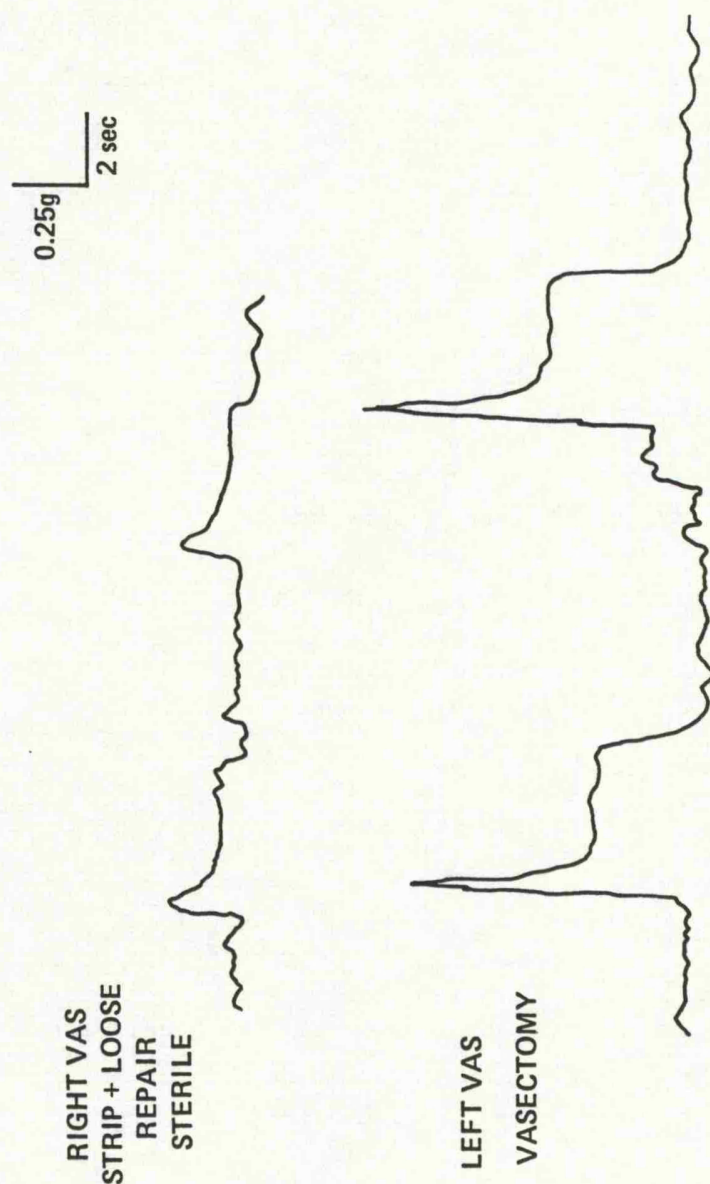


Fig 17.6 A vas that has been stripped and had a loose inguinal repair performed contracts poorly in comparison with the contralateral vasectomy






Fig 17.7 Fertile vas deferens with loose inguinal reconstruction

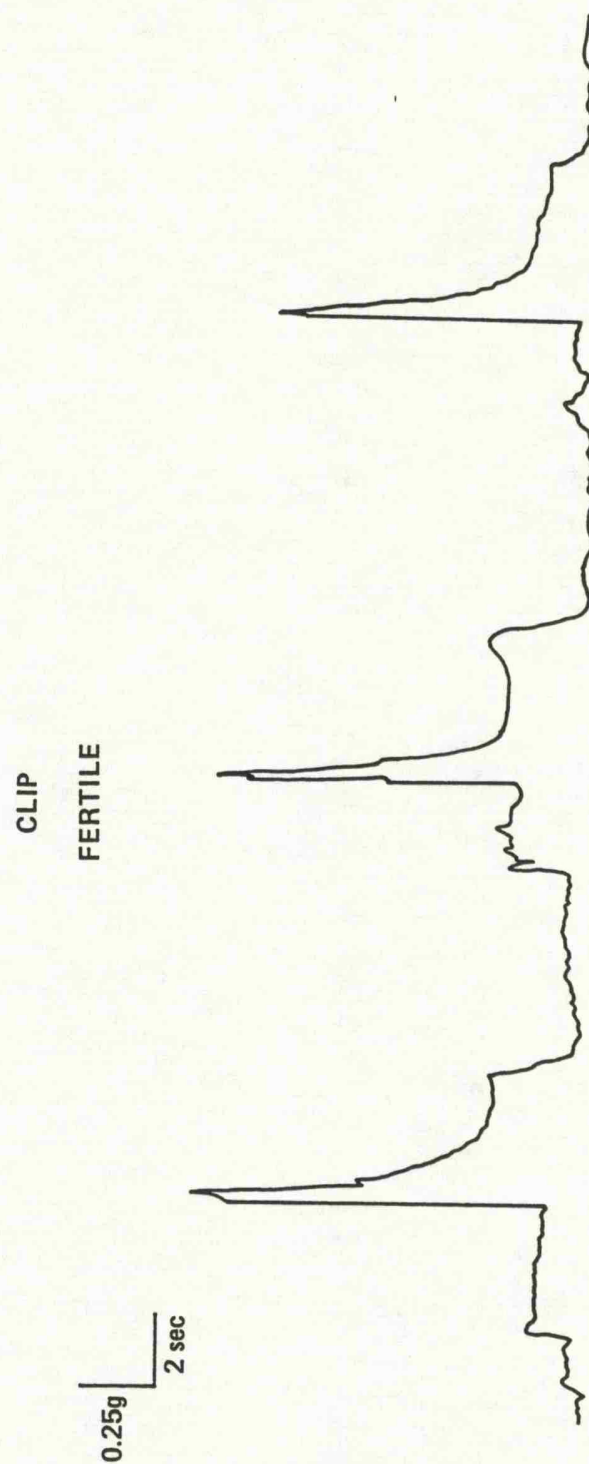


Fig 17.8 Crush injury to the vas frequently resolves and the animal is fertile. The contractions are powerful but note the scale here is twice as that of the control vas

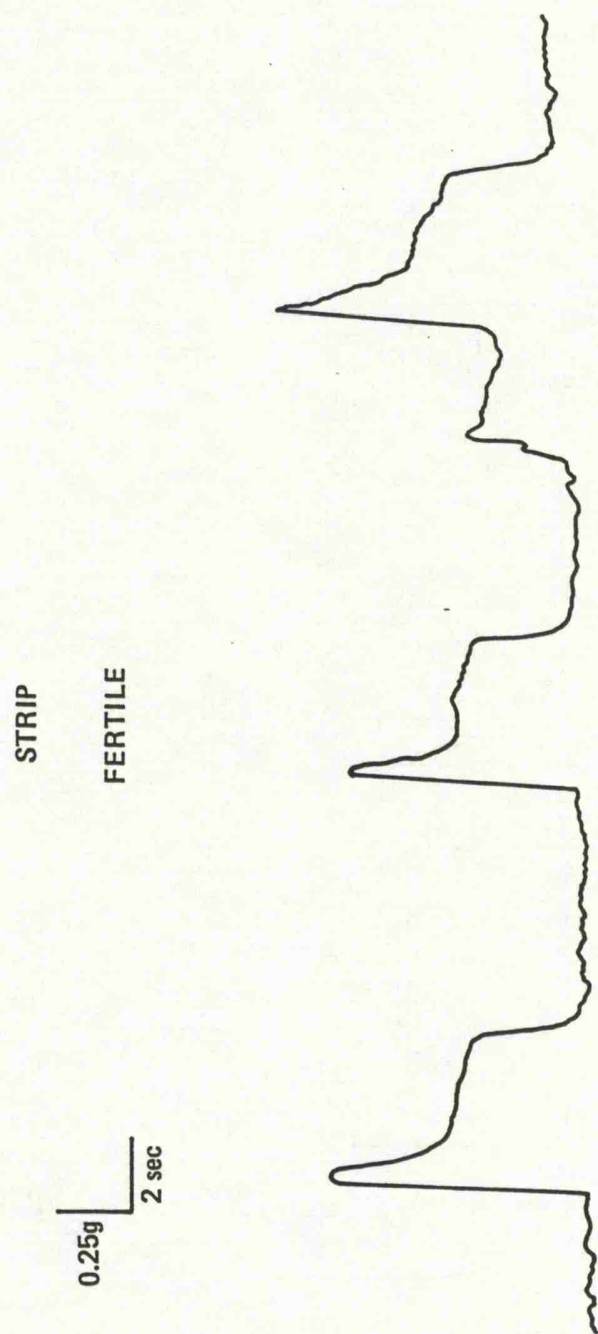
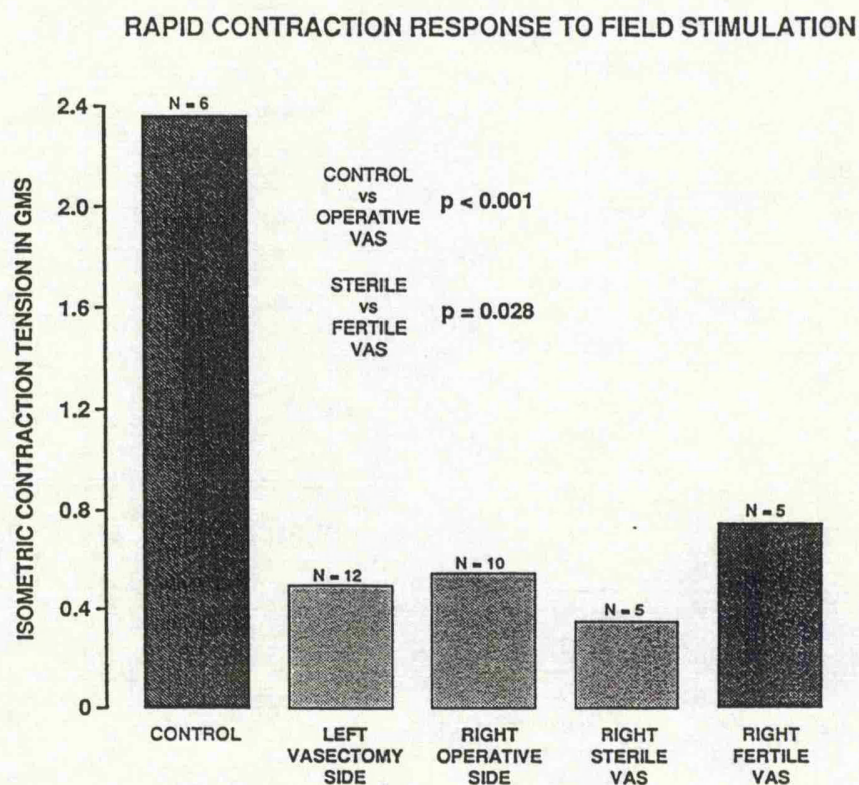
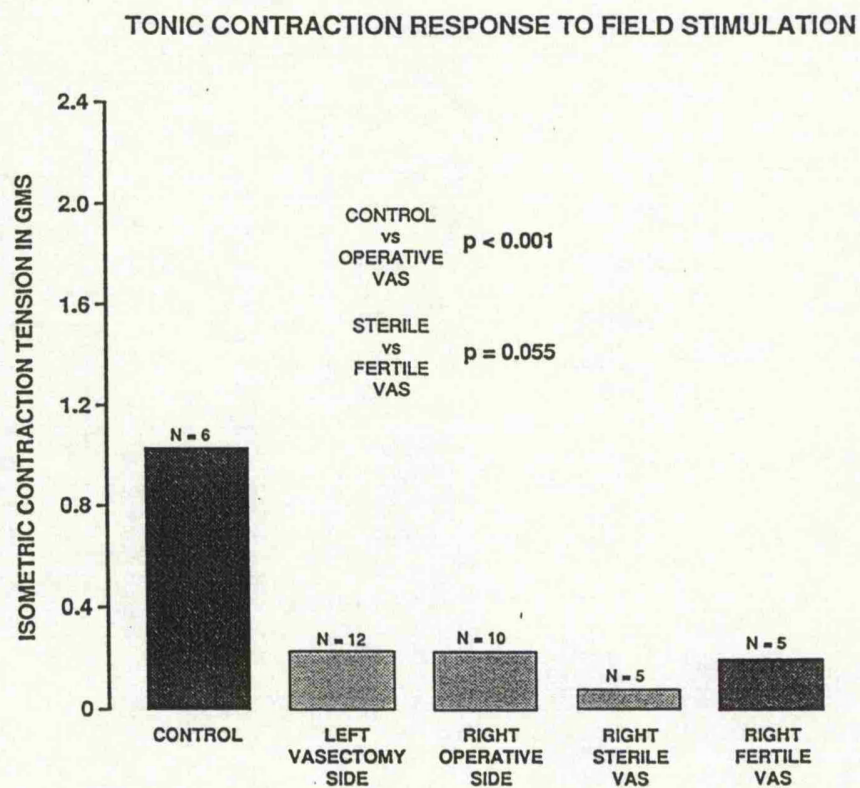


Fig 17.9 A fertile vas that has been stripped appears to contract more powerfully than a sterile vas





**Fig 17.10** Results of the peak contraction response of the vas in the control and operative groups. The control vas have powerful contractions in comparison to the vasectomy and operative groups. There is a significant difference between the sterile and fertile vas.



**Fig 17.11** The tonic contractions mirror the peak contractions (Fig 17.10). There is no difference between the vasectomy and the operative groups though the fertile vas contracts better than the sterile vas

## **Section 3**

## Chapter 18

### Clinical Cases

This thesis, developed as a consequence of clinical cases which are typified in the following group of four patients, which confirm the vulnerability of the vas deferens during inguinal surgery, and hi-light azoospermia as a late complication.

#### Case Reports

##### Patient 1

A 39 year old man was referred with azoospermia. He underwent right herniotomy at the age of 5 and required recurrent hernia repair 3 years later. His subsequent fertility status was normal as his wife became pregnant on 4 occasions but unfortunately 3 of these resulted in a miscarriage. An elective left herniorrhaphy was performed at the age of 34 and since then he has remained azoospermic. Testes were of good volume and both vasa palpable. Scrototomy revealed healthy testes with empty epididymis. The onset of his azoospermia appears to be critically related to his left herniorrhaphy. The left vas deferens was surrounded with scar tissue but appeared intact. Vasography demonstrated no obstruction and left testis biopsy was normal with active spermatogenesis. No immobilising antibodies and only weakly positive agglutinating antibodies were detected.

##### Patient 2

A 33 year old man presented with an 8 year history of azoospermia. He had undergone left inguinal hernia repair at the age of 19 years, and an emergency right strangulated hernia repair 6 years later. Bilateral

exploration and vasography revealed both vasa to be obstructed in the inguinal canal. More seriously a long segment of the left vas deferens was missing. The stricture on the right side was repaired by side to side anastomosis. Testis biopsy showed normal spermatogenesis.

#### **Patient 3**

Referral in this 30 year old man was due to a 3 year history of infertility. He was azoospermic with bilateral inguinal scars from neonatal herniotomy. Exploration and vasography demonstrated the left vas deferens to be obstructed in the superficial ring however no vas deferens could be identified in the right inguinal canal. A left vasovasostomy was undertaken. Testis histology shows normal spermatogenesis on the left side with germinal aplasia on the right. To date 9 years later the patient remains azoospermic.

#### **Patient 4**

Azoospermia in this 30 year old man was from a congenital hypoplastic left testis with an obstructed right vas deferens from childhood herniotomy. Exploration confirmed vasal block to be at the site of previous surgery. Right testis biopsy demonstrated normal spermatogenesis. He underwent right vasovasostomy.

#### **Discussion**

In the fertility clinic the prognosis for men with azoospermia is very poor (Lilford & Dalton, 1987). Often the only treatment possible is artificial insemination by donor. The majority of patients with azoospermia do not have a specific aetiology, but occasionally there is a history of inguinal surgery. This is usually unilateral. Any vas damage therefore may be masked by a normal contralateral testis and vas deferens. In 3 of the

patients described there was obvious damage of the vas at surgical exploration. For case 1 however vasogram and testicular biopsies were normal, and yet he was azoospermic. This observation has previously been reported by Jequeir (1985) in 3 patients who were azoospermic after previous herniotomy or trauma. It is possible that an intratesticular block may have developed or there may be more subtle changes to vas deferens function after surgical exploration than direct injury. Certainly previous animal experiments have demonstrated the vulnerability of the immature vas deferens to over zealous techniques (Shandling & Janik, 1981; Janik & Shandling, 1982; Sandhu et al., 1989; Sandhu & Osborn, 1991). Damage to the specialized pseudocilia, muscle and its autonomic and peptidergic innervation have been previously described (Sandhu et al., 1990). The role of antisperm antibodies in fertility has been recently highlighted by Hendry and his colleagues (1990). There is still some debate however about the importance of antisperm antibodies. In men with autoimmunity to sperm, spontaneous pregnancy rates can approach those expected for couples with idiopathic infertility (Ayvaliotis et al., 1985). Others have stated that vasectomy reversal with associated antisperm antibodies lead to a delay in conception, but not to a significant reduction in conception rates (Fuchs, 1990). Furthermore the potential role of antibodies after inguinal surgery is uncertain (Phadke & Padukone, 1964; Linnet, 1983; Parkhouse & Hendry, 1991).

These clinical cases combined with the animal experiments highlight the care needed during inguinal surgery. This is particularly so in patients undergoing bilateral procedures. Clearly for unilateral operations any vas deferens damage may be masked by the contralateral side, assuming that there is a normally functioning testis and vas unit. In addition, although the vas deferens may be intact following surgery; difficulties with sperm

transport leading to obstructive azoospermia and male subfertility may be a long term post operative complication.

## Chapter 19

### General Discussion

In infertility clinics the male is the significant factor for 25% of couples. The prognosis for men with idiopathic oligozoospermia and azoospermia is poor. Previous surgery, infection, trauma, and even amyloidosis have all been shown to disrupt the propulsive action of the vas deferens leading to defective sperm transport, retrograde flow, oligozoospermia and infertility (Janik and Shandling, 1982). Inadvertent transection of the vas deferens has an obvious effect. However as azoospermia may occur after hernia repair despite normal testicular biopsy and vasogram, (Jequier, 1985), more subtle manipulations of the vas deferens may affect contractility and subsequent fertility.

Attention has previously been focused in animal studies on histological changes in the vas deferens (Janik and Shandling, 1982; Sandhu et al, 1989; 1990; 1991), and in clinical context on obstructive azoospermia secondary to surgery, especially childhood herniotomy (Young, 1951; Hanley, 1955). Sparkman (1962) recorded an incidence of 1.6% for the inadvertent removal of a segment of the vas deferens with the hernia sac. Friberg and Fritjofsson (1979) on investigating 76 men with sperm-agglutinating antibodies found that 12 had undergone herniorrhaphy and were sterile. Ten were explored and five had vasal obstruction consistently in the area of previous surgery. Jequier (1985) described 10 out of 102 patients with obstructive azoospermia with a prior history of surgery or trauma. Five of these patients had a unilateral herniotomy. Only 2 of these patients had definite vasal obstruction on exploration. The other 3 cases had a patent vas deferens, with a normal testis and yet were azoospermic. A similar incidence of azoospermia (13%) following inguinal herniotomy was



reported by Petrovsky et al (1985) . The result of vas deferens damage and subsequent azoospermia will be obvious on semen analysis. The incidence of vas damage in unilateral herniotomy and inguinal surgery will be difficult to establish; due to population movement, as majority of the surgery is performed during childhood and masking by the contralateral side.

Vas damage can occur by either direct trauma, vascular damage leading to necrosis and luminal damage, autonomic nerve damage affecting contractility and vas secretion, and possibly rising titres of antisperm antibodies. As regards herniotomy, damage to the cord is more likely when there is a negative exploration, or it is unclear whether the sac is patent or not. The difficulty with the small filiform processus vaginalis tearing with dissection is common, and great care must be taken in these cases. At times exploration is correctly undertaken on the basis of a sound history from the parents or the patient's general practitioner. The sac may however close off in the intervening period prior to surgery necessitating a difficult dissection. Certain practices are already stressed in sound paediatric training. The opposite side is no longer routinely explored and there is no need to be obsessive to dissect the distal portion of the sac. In this study the effect on fertility has been correlated with histological evidence, especially as there is a suggestion that obstructive lesions may initially be incomplete, and present with oligozoospermia and infertility and subsequently develop azoospermia and sterility (Jequier 1983).

Vasectomy reversal in adults has a moderately high success rate (Linnet,1983) and this may reflect the increased vulnerability of the immature vas deferens. Certainly in adult Wistar rats stripping of the vas appears to be less damaging (Chapter 15).

In both fertility trials of the immature and mature vas deferens as expected the control, sham and mobilisation of the cord groups, all rats were fertile. Overall the immature vasa fared worse with a true sterility rate of 65% when only the operative groups are considered. This compares significantly with a true sterility rate of 37% with the mature vas deferens experiments excluding the controls and bilateral vasectomy group which have an obvious aetiology. Although the experimental design was slightly changed with the mature animals, still some interesting patterns emerge.

When the vas is crushed with an arterial clip it is totally destroyed over that segment; yet in 5 out of 7 rats in the immature group and 2 out of 5 in the mature group the vas had recanalized and the animals were fertile. Presumably this is due to the ability of the vasa to repair itself over short segments. The anatomical structure of a powerfully contractile spiral tube is likely to help overcome segmental blocks though we have no direct proof of this. The single most destructive feature overall was stripping the vas deferens by means of sharp and blunt dissection: 71% and 40% sterility rates of the immature and mature rats respectively. This is likely to cause vas damage over longer segments as seen on the histological studies. Tight ring reconstruction is very destructive to the testis blood supply and all immature animals were sterile. A looser repair over a 4 mm diameter pin in the mature animals still resulted in a 10% infertility rate. The combination of ring reconstruction and a crush injury or specially stripping of the vasa resulted in a high incidence of infertility (see Tables 14.2 & 15.2 ). In both studies there are examples of animals being sterile despite normal vasa and testis on vasography and histology (Tables 14.3&15.3). These relate to 2 animals with tight ring and another with crush injury + loose repair in the immature group, and, 2 rats from the mature group who underwent strip, and strip + loose repair respectively.

There is no data on semen analysis on these rats as artificial vagina ejaculation is very difficult in small animals and electroejaculation often results in death of these animals. Technically it is possible that these animals may have developed intratesticular blocks, equally the surgical manipulation may have resulted in subtle changes of vas function and sperm transport. This mirrors the clinical problem of azoospermia after hernia repair despite normal testis biopsy and vasogram as discussed in Chapter 18. The studies on the autonomic and peptidergic innervation suggest decreased density of Dopamine- $\beta$ -hydroxylase and NPY in the muscle compared with controls (Figs.16.1&16.5). The numbers are too small to be statistically valid and our method of visualising the immunofluorescent staining on a counting graticule is open to experimental error. Nevertheless there is a suggestion by this data that damage to the vas may result in not only damage to the muscle but also to its autonomic and peptidergic innervation. The decreased density of vasoactive intestinal polypeptide in the subepithelial plexus may have a detrimental effect in the repair process of the vas. This is ofcourse only an observation and we have no direct evidence for this. The main function of the vas is sperm transport and vas deferens contractility is of prime importance. The isometric contraction of the vas deferens maybe a sensitive method to assess this parameter of vas function. The control vasa had a mean rapid contraction tension of 2.38g compared to 0.55g tension in the operative group,  $p<0.001$ . The vasectomy group had similar loss of contraction ability with a response of 0.50g tension (Table 17.4). The reason for this as discussed in Chapter 17 is that vasectomy and operative manipulation groups are comparable in terms of dissection and trauma induced. The difference in rapid contraction between the operative fertile rats 0.75g and sterile rats 0.35g was highly significant at  $p=0.028$ . These

---

results are mirrored in the data from tonic contractions (Figs 17.10 & 17.11).

#### Testis

The incidence of testicular atrophy following herniotomy (without ring reconstruction) in children has been reported between 1% - 2.7% (Fischer and Mumenthaler 1957). It can be as high as 30% following surgery for cryptorchidism and 15% for operations on hydroceles (Fahlstrom et al. 1963). This is an important cause to exclude as a direct cause of infertility in assessing vas damage.

Maldescent of the testis is another important group which requires extensive mobilisation of the cord. The incidence of cryptorchidism is approximately 3% in male neonates, 0.8% in adults (Mostofi 1977) and is associated with a significant incidence of impaired spermatogenesis and sterility when the process is bilateral. The incidence appears to have doubled in the last 20 years (Jackson et al. 1987). The finding that the testis require mobilisation of the testicular vessels before they can be placed in the dartos pouch, contradicts the view that some retractile and not truly undescended testes are being operated on.

It is recognised that one form of congenital problem may give rise to other congenital anomalies. Abnormalities of the epididymis associated with an undescended testicle have been reported in several series. Scorer (1964) described an incidence of 46%, Marshall and Shermeta (1979) 35.7%, Heath et al (1984) 31.8%, Jackson et al. (1987) 14.7%. Jackson et al. also describe vas abnormalities in approximately 6% of patients with an undescended testicle. Several studies have described the progressive decrease in germ cells, and Sertoli and Leydig cell hyperplasia with

basement membrane thickening in cryptorchid patients (DePalma et al. 1988). The histological immaturity of the epididymis and vas deferens in these patients would seem to indicate a limitation of the capability of these structures to perform their function efficiently, and any further trauma or ischaemic damage will further adversely effect the potential for fertility.

In the series of immature Wistar rats (Ch.14),(Groups 4 - 8) the incidence of testes infarction, (n=8) was 24%, but half of these (Table 14.3) were associated with an abnormal vas. Hence in 4 cases (12%) testicular infarction was the sole cause of infertility and these were all related to Group 6 with tight reconstruction of the ring. This appears to be related to the experimental design as a 2 mm pin is too tight for inguinal ring reconstruction. In the immature animals the mean left testis weight/100g body weight 0.48 (S. D.0.09) (Table 14.2) was significantly higher compared with the right (operative manipulation) side 0.42 (S.D.0.17); ( $p=0.027$ ). Comparing the fertile right testis with the sterile right testis, the mean weight of the right testis was less in the sterile group 0.35g ( S.D. 0.24 ) compared with the fertile group 0.47g ( S.D. 0.06 ) and this was statistically significant at  $p<0.01$ . With the mature animals the looser inguinal ring reconstruction led to a lower infarction rate (Table 15.3) of 19% in the 16 sterile rats. There was no significant difference between the weight of the left testis/100g body weight, 0.32g and the weight of the right testis/100g body weight, 0.325g.

In inguinal surgery it is wrong to assume that the contralateral side is normal. There is a higher incidence of male subfertility in post testicular torsion patients. As sympathetic orchioepathia is likely to be self-limiting, a developmentally abnormal contralateral testis would produce an abnormal seminal profile, irrespective of whether torsion had occurred or not (Lewis-Jones 1987). Hence in any inguinal surgery, especially in the

young, one may be dealing with an organ and a conducting system which potentially may be abnormal with impaired spermatogenesis, and there is a possibility that the contralateral side may subsequently become affected.

Antisperm antibodies following unilateral vasectomy alone may be relevant in inbred DBA/1J mice (Kessler et al.,1985), which are known to be high antibody formers. In the present experiments on the immature and mature rats, vasa that underwent skin crease incision or mobilisation of the cord with unilateral vasectomy were all fertile, therefore antisperm antibodies would not appear to be a significant problem in this study.

In summary in the Wistar rat animal model, the vas deferens and the testis are vulnerable to operative handling especially inguinal ring reconstruction and stripping of the cord. These results indicate the great care needed in handling the vas deferens during inguinal operations. In addition, although the vas deferens may be intact following surgery (even in unilateral cases); difficulties with sperm transport leading to obstructive azoospermia and male subfertility may be a long term post operative complication.

#### Statistical Analysis

Throughout this thesis comparisons within a rat group were made by means of the paired t- test, and those between rat groups using the two sample t-test.

## Chapter 20

### Conclusion

This experimental study has developed a successful Wistar rat model to study the effect of inadvertent vas damage from inguinal surgery. We have directly looked at the effect on fertility, vas deferens contractility and its autonomic and peptidergic innervation. The main conclusions from the study are as follows:

1. The vas deferens of the Wistar rat is a highly specialised organ with a special epithelial spiral for sperm transport.
2. A variety of inguinal surgical techniques may significantly affect fertility. The immature vas deferens appears to be much more vulnerable with an infertility rate of 65% compared to 29% from the mature Wistar rats. Tight ring reconstruction and extensive mobilization by stripping of the vas is particularly destructive. Accidental crush trauma over a short segment of the vas frequently resolved completely, but extensive anatomical vas mobilisation as commonly practised to obtain extra length for an undescended testicle is physiologically destructive.
3. Tight ring reconstruction has a high incidence of testicular infarction and can obstruct the vas directly at the inguinal ring.
4. Three immature and 2 adult rats were sterile despite normal vasa deferentia and testes. These animal experiments correlate with the clinical problem of azoospermia after hernia repair despite normal testicular biopsy and vasogram.
5. The tests of functional contractility showed the classical biphasic response to isometric field stimulation. There was a significant difference in the contraction response of control vas deferens

compared with the operative side;  $p < 0.001$ . The vasa deferentia that underwent vasectomy responded poorly to field stimulation and there was no difference between operative side and vasectomy group. In the operative group there was a significant difference between sterile and fertile vas deferens at  $p = 0.028$ . These results were mirrored by tonic contraction responses for the respective groups.

6. In control rats the distribution of Neuropeptide Y and Dopamine- $\beta$ -Hydroxylase containing nerves appeared identical within the muscle coat, as did the location of Vasoactive Intestinal Polypeptide and Acetylcholinesterase - positive nerves beneath the epithelium. This suggests that these latter nerves are perhaps more important in the secretory aspect of the vas deferens while the adrenergic innervation together with Neuropeptide Y modulation are primarily for contractility and relaxation. The density of the autonomic and peptidergic nerves in comparison to control vasa had decreased in all operative groups. This present study also supports previous evidence of Co-storage of VIP and acetylcholine and NPY and noradrenaline as witnessed by granules on electron microscopy.

Although the difficulties of extrapolating animal studies to men are acknowledged, in this study we have shown the vulnerability of the vas deferens to inadvertent damage. Direct damage to the vas muscle and its epithelium can cause luminal obstruction. Further damage can occur if the blood supply is compromised, together with any trauma to its autonomic and peptidergic nerve supply which will affect contractility and sperm transport. These results indicate the need to be cautious in the way the vas deferens is handled during inguinal operations. In addition,



although the vas may be intact following surgery (even in unilateral cases) difficulties with sperm transport leading to obstructive azoospermia and male sub-fertility, may be a long term post operative complication.

## **Section 4**

## **Chapter 21**

## **Appendix**

Rat no	Initial body Wt	Final body Wt	Wt gain	Fertile or sterile	Preg rate	Vaginal plugs	Litter size	Mean litter size	Wt Rt testis	Wt Rt testis\100g body wt	Wt Lt testis	Wt Lt testis\100g body wt	Total testes wt	Total testes wt\100g body wt	Prostate weight
A1	90g	360g	270g	fertile	80%	5	50	13	1.62g	0.45g	1.66g	0.46g	3.28g	0.91g	1.05g
A2	96g	330g	234g	fertile	80%	7	51	13	1.52g	0.46g	1.68g	0.51g	3.20g	0.96g	0.95g
A3	102g	390g	288g	fertile	100%	7	70	14	1.67g	0.43g	1.82g	0.47g	3.49g	0.89g	1.46g

Appendix 14.1 Group 1 Unoperated controls

Rat no	Initial body Wt	Final body Wt	Wt gain	Fertile or sterile	Preg rate	Vaginal plugs	Litter size	Mean litter size	Wt Rt testis	Wt Rt testis\100g body wt	Wt Lt testis	Wt Lt testis\100g body wt	Total testes wt	Total testes wt\100g body wt
B1	94g	340g	246g	Fertile	60%	7	39	13	1.81g	0.53g	1.78g	0.52g	3.59g	1.05g
B2	88g	295g	207g	Fertile	60%	5	32	11	1.49g	0.50g	1.30g	0.44g	2.79g	0.94g
B3	74g	280g	206g	Fertile	100%	2	58	12	1.50g	0.53g	1.60g	0.57g	3.10g	1.10g
B4	92g	320g	228g	Fertile	80%	7	57	14	1.50g	0.46g	1.53g	0.47g	3.03g	0.94g
B5	86g	350g	264g	Fertile	80%	2	49	12	1.64g	0.46g	1.03g	0.29g	2.67g	0.76g
B6	94g	345g	251g	Fertile	80%	4	40	10	1.60g	0.46g	1.77g	0.51g	3.37g	0.97g
B7	84g	315g	231g	Fertile	100%	7	52	10	1.60g	0.50g	1.60g	0.50g	3.20g	1.01g
B8	88g	340g	252g	Fertile	100%	4	60	12	1.65g	0.48g	1.70g	0.50g	3.35g	0.98g

Appendix 14.2 Group 2 Skin incision only

Rat no	Initial body Wt	Final body Wt	Wt gain	Fertile or sterile	Preg rate	Vaginal plugs	Litter size	Mean litter size	Wt Rt testis	Wt Rt testis\100g body wt	Wt Lt testis	Wt Lt testis\100g body wt	Total testes wt	Total testes wt\100g body wt
C2	88g	305g	217g	fertile	60%	5	35	12	1.42g	0.46g	0.66g	0.22g	2.08g	0.68g
C3	85g	355g	270g	fertile	60%	7	39	13	1.56g	0.44g	1.75g	0.49g	3.31g	0.93g
C4	80g	330g	250g	fertile	60%	7	41	14	1.64g	0.50g	1.50g	0.45g	3.14g	0.95g
C5	92g	345g	253g	fertile	100%	4	52	10	1.73g	0.50g	1.60g	0.46g	3.33g	0.96g
C6	94g	350g	256g	fertile	80%	4	62	16	1.71g	0.49g	1.71g	0.49g	3.42g	0.98g
C7	86g	325g	239g	fertile	100%	7	68	14	1.65g	0.51g	1.81g	0.56g	3.46g	1.06g
C8	100g	350g	250g	fertile	80%	3	50	13	1.79g	0.51g	2.00g	0.57g	3.79g	1.08g

Appendix 14.3 Group 3 Mobilization of cord only

Rat No	Initial body wt	Final body wt	Wt gain	Fertile or Sterile	Preg rate	Vaginal plugs	Litter size	Mean litter size	Wt Rt testis	Wt Rt testis\100g body wt	Wt Lt testis	Wt Lt testis\100g body wt	Total testes wt	Total testes wt\100g body wt	Prostate weight
D1	90g	330g	240g	fertile	80%	7	40	10	1.35g	0.41g	1.56g	0.47g	2.91g	0.88g	0.83g
D3	96g	370g	274g	sterile	-	1	-	-	1.72g	0.46g	1.78g	0.48g	3.50g	0.94g	1.00g
D5	74g	330g	256g	sterile	-	4	-	-	1.92g	0.58g	1.35g	0.41g	3.27g	0.99g	0.90g
D6	98g	295g	197g	sterile	-	1	-	-	2.64g	0.89g	1.44g	0.49g	4.08g	1.38g	0.66g
D7	96g	360g	264g	sterile	-	7	-	-	0.91g	0.25g	1.77g	0.49g	2.68g	0.74g	1.09g
D8	88g	355g	267g	sterile	-	5	-	-	1.05g	0.30g	1.63g	0.46g	2.68g	0.75g	0.79g
D9	115g	335g	220g	fertile	40%	3	23	12	1.68g	0.50g	1.58g	0.47g	3.26g	0.97g	0.91g

Appendix 14.4 Group 4 Stripping of right vas deferens

Rat no	Initial body Wt	Final body Wt	Wt gain	Fertile or sterile	Preg rate	Vaginal plugs	Litter size	Mean litter size	Wt Rt testis	Wt Rt testis\100g body wt	Wt Lt testis	Wt Lt testis\100g body wt	Total testes wt	Total testes wt\100g body wt	Prostate weight
E1	88g	360g	272g	fertile	60%	3	36	12	1.52g	0.42g	1.60g	0.44g	3.10g	0.86g	0.64g
E2	94g	355g	261g	fertile	100%	2	57	11	1.85g	0.52g	1.80g	0.50g	3.65g	1.02g	0.62g
E3	94g	335g	241g	fertile	60%	7	30	10	1.44g	0.43g	1.60g	0.48g	3.04g	0.90g	0.66g
E4	98g	350g	252g	sterile	-	4	-	-	1.48g	0.42g	1.85g	0.53g	3.33g	0.95g	0.93g
E5	98g	330g	232g	fertile	100%	0	65	13	1.49g	0.45g	1.54g	0.47g	3.03g	0.91g	1.0g
E6	90g	345g	255g	sterile	-	9	-	-	1.64g	0.48g	1.64g	0.48g	3.28g	0.95g	0.72g
E7	100g	365g	265g	fertile	60%	5	33	11	1.50g	0.41g	1.62g	0.44g	3.12g	0.85g	0.78g

Appendix 14.5 Group 5 Crush injury right vas deferens



Rat no	Initial body Wt	Final body Wt	Wt gain	Fertile or sterile	Preg rate	Vaginal plugs	Litter size	Mean litter size	Wt Rt testis	Wt Rt testis \100g body wt	Wt Lt testis	Wt Lt testis \100g body wt	Total testes wt	Total testes wt \100g body wt	Prostate weight
F1	90g	355g	265g	sterile	-	5	-	-	0.49g	0.14g	1.78g	0.50g	2.27g	0.63g	1.03g
F2	86g	340g	254g	sterile	-	2	-	-	0.05g	0.01g	1.51g	0.44g	1.56g	0.45g	0.60g
F3	82g	330g	248g	sterile	-	3	-	-	1.45g	0.44g	1.91g	0.58g	3.36g	1.01g	0.58g
F4	74g	340g	266g	sterile	-	3	-	-	0.81g	0.24g	1.86g	0.55g	2.67g	0.78g	0.72g
F6	96g	345g	249g	sterile	-	8	-	-	0.96g	0.28g	1.41g	0.41g	2.37g	0.68g	0.95g
F7	92g	335g	243g	sterile	-	4	-	-	0.70g	0.21g	0.33g	0.10g	1.03g	0.30g	0.84g

Appendix 14.6

Group 6 Tight repair right inguinal ring - 2mm

Rat no	Initial body Wt	Final body Wt	Wt gain	Fertile or sterile	Preg rate	Vaginal plugs	Litter size	Mean litter size	Wt Rt testis	Wt Rt testis\100g body wt	Wt Lt testis	Wt Lt testis\100g body wt	Total testes wt	Total testes wt\100g body wt	Prostate weight
G1	92g	340g	248g	sterile	-	5	-	-	0.98g	0.29g	1.06g	0.31g	2.04g	0.60g	0.74g
G2	98g	340g	242g	sterile	-	3	-	-	3.20g	0.94g	1.90g	0.56g	5.10g	1.5g	0.95g
G3	94g	385g	291g	sterile	-	3	-	-	1.33g	0.35g	1.76g	0.46g	3.09g	0.80g	0.80g
G4	96g	350g	254g	fertile	80%	2	57	14	2.02g	0.58g	1.77g	0.51g	3.79g	1.08g	1.11g
G5	100g	355g	255g	sterile	-	4	-	-	0.14g	0.04g	1.93g	0.54g	2.07g	0.58g	0.72g
G6	90g	350g	260g	sterile	-	5	-	-	0.44g	0.13g	2.05g	0.59g	2.49g	0.71g	0.80g
G7	102g	295g	193g	sterile	-	1	-	-	0.75g	0.25g	1.44g	0.49g	2.19g	0.74g	0.82g

Appendix 14.7 Group 7 Strip plus loose repair right inguinal ring - 4mm

Rat no	Initial body Wt	Final body Wt	Wt gain	Fertile or sterile	Preg rate	Vaginal plugs	Litter size	Mean litter size	Wt Rt testis	Wt Rt testis\100g body wt	Wt Lt testis	Wt Lt testis\100g body wt	Total testes wt	Total testes wt\100g body wt	Prostate weight
H1	84g	300g	216g	fertile	100%	4	58	12	1.70g	0.57g	1.78g	0.59g	3.48g	1.16g	1.04g
H2	92g	350g	258g	sterile	-	3	-	-	0.80g	0.23g	2.22g	0.63g	3.02g	0.86g	0.97g
H3	88g	330g	242g	sterile	-	5	-	-	1.88g	0.56g	1.95g	0.59g	3.83g	1.16g	0.82g
H4	110g	360g	250g	sterile	-	4	-	-	0.71g	0.20g	1.95g	0.54g	2.66g	0.73g	0.78g
H5	102g	365g	263g	fertile	100%	5	38	8	0.98g	0.27g	1.55g	0.42g	2.53g	0.69g	1.04g
H6	104g	380g	276g	fertile	80%	6	55	14	1.67g	0.44g	1.75g	0.46g	3.42g	0.90g	1.07g
H7	96g	375g	279g	fertile	80%	1	50	13	1.90g	0.51g	1.81g	0.48g	3.71g	0.98g	0.90g

Appendix 14.8 Group 8 Crush injury right vas plus loose repair inguinal ring - 4mm

Rat No	Initial body wt	Final body wt	Weight gain	Fertile or Sterile	Preg. rate	Litter size	Mean litter size	Right testis weight	Left testis weight	Total testes weight	Wt Rt testis/100g body wt	Wt Lt testis/100g body wt	Total testes wt/100g body wt	Vasography
A1	290g	615g	325g	fertile	80%	49	12	2.03g	2.03g	4.06g	0.33g	0.33g	0.66g	patent
A2	295g	545g	250g	fertile	80%	54	14	1.90g	1.80g	3.70g	0.34g	0.33g	0.67g	patent

Appendix 15.1 Results from Group1 - Unoperated controls

Rat No	Initial body wt	Final body wt	Weight gain	Fertile or Sterile	Preg. rate	Litter size	Mean litter size	Right testis weight	Left testis weight	Total testes weight	Wt Rt testis/100g body wt	Wt Lt testis/100g body wt	Total testes wt/100g body wt	Vasography
B1	285g	510g	225g	fertile	80%	45	11	1.67g	1.67g	3.34g	0.32g	0.32g	0.65g	patent
B2	285g	534g	249g	fertile	80%	48	12	1.45g	1.50g	2.95g	0.27g	0.28g	0.55g	patent
B3	290g	615g	325g	fertile	80%	39	10	1.86g	1.56g	3.42g	0.30g	0.25g	0.56g	patent
B4	295g	560g	265g	fertile	100%	54	11	1.76g	1.70g	3.46g	0.31g	0.30g	0.62g	patent
B5	310g	550g	240g	fertile	100%	61	12	1.84g	1.89g	3.73g	0.33g	0.34g	0.68g	patent
mean values	293g	554g	261g	100%	88%	49	11	1.72g	1.66g	3.38g	0.30g	0.30g	0.61g	100%

Appendix 15.2 Results for Group 2 - skin incision only

Rat No	Initial body wt	Final body wt	Weight gain	Fertile or Sterile	Preg- rate	Litter size	Mean litter size	Right testis weight	Left testis weight	Total testes weight	Wt Rt testis/100g body wt	Wt Lt testis/100g body wt	Total testes wt/100g body wt	Vasography
C1	297g	570g	273g	sterile	-	-	-	1.7g	1.68g	3.38g	0.30g	0.30g	0.60g	N/A
C2	325g	575g	250g	sterile	-	-	-	3.3g	4.5g	7.8g	0.57g	0.78g	1.36g	N/A
C3	305g	615g	310g	sterile	-	-	-	1.77g	1.82g	3.59g	0.29g	0.30g	0.58g	N/A
C4	325g	605g	280g	sterile	-	-	-	1.96g	2.44g	4.40g	0.32g	0.40g	0.73g	N/A
C5	295g	545g	250g	sterile	-	-	-	1.78g	1.80g	3.58g	0.32g	0.33g	0.66g	N/A
mean values	309g	582g	273g	100%	-	-	-	2.10g	2.45g	4.55g	0.36g	0.42g	0.79g	N/A

Appendix 15.3 Results for Group 3 - Bilateral Vasectomy

Rat No	Initial body wt	Final body wt	Weight gain	Fertile or Sterile	Preg. rate	Litter size	Mean litter size	Right testis weight	Left testis weight	Total testes weight	Wt Rt testis/100g body wt	Wt Lt testis/100g body wt	Total testes wt/100g body wt	Vasography
D1	305g	675g	370g	sterile	-	-	-	2.35g	2.40g	4.75g	0.35g	0.36g	0.71g	not patent
D2	310g	530g	220g	fertile	80%	49	12	2.00g	1.91g	3.91g	0.38g	0.36g	0.74g	patent
D3	305g			culled	due	to	testis	ab	scs	7 wks	post	op.		
D4	275g	430g	155g	sterile	-	-	-	1.55g	1.56g	3.11g	0.36g	0.36g	0.72g	not patent
D5	295g	596g	301g	fertile	100%	55	11	1.8g	1.5g	3.30g	0.30g	0.25g	0.55g	patent
mean values	296g	558g	262g	50%	90%	52	12	1.93g	1.84g	3.77g	0.35g	0.33g	0.68g	

Appendix 15.4 Group 4 Crush injury right vas

Rat No	Initial body wt	Final body wt	Weight gain	Fertile or Sterile	Preg. rate	Litter size	Mean litter size	Right testis weight	Left testis weight	Total testes weight	Wt Rt testis/100g body wt	Wt Lt testis/100g body wt	Total testes wt/100g body wt	Vasography
E1	305g	550g	245g	fertile	80%	52	13	1.7g	1.9g	3.6g	0.31g	0.35g	0.66g	patent
E2	290g	595g	305g	sterile	-	-	-	1.85g	1.97g	3.82g	0.31g	0.33g	0.64g	not patent
E3	310g	560g	250g	sterile	-	-	-	2.0g	1.77g	3.77g	0.36g	0.32g	0.68g	patent
E4	300g	535g	235g	fertile	100%	53+2†	11	1.80g	1.84g	3.64g	0.34g	0.34g	0.68g	patent
E5	305g	560g	255g	fertile	60%	39	13	1.84g	1.80g	3.64g	0.33g	0.32g	0.65g	patent
mean values	302g	560g	258g	40%	80%	48	12	1.84g	1.86g	3.70g	0.33g	0.33g	0.66g	

Appendix 15.5 Group 5 Strip right vas



Rat No	Initial body wt	Final body wt	Weight gain	Fertile or Sterile	Preg. rate	Litter size	Mean litter size	Right testis weight	Left testis weight	Total testes weight	Wt Rt testis/100g body wt	Wt Lt testis/100g body wt	Total testes wt/100g body wt	Vasography
F1	255g	480g	225g	fertile	40%	19	10	1.47g	1.66g	3.13g	0.31g	0.35g	0.66g	patent
F2	300g	595g	295g	fertile	100%	68	14	1.78g	1.86g	3.64g	0.30g	0.31g	0.61g	patent
F3	285g	520g	235g	fertile	40%	25	13	1.75g	1.82g	3.57g	0.34g	0.35g	0.69g	patent
F4	300g	545g	245g	fertile	100%	60%	12	2.0g	2.13g	4.13g	0.37g	0.39g	0.76g	patent
F5	300g	580g	280g	sterile	-	-	-	0.60g	2.40g	3.0g	0.10g	0.41g	0.51g	partial obst
F6	295g	560g	265g	fertile	80%	48	12	1.85g	2.10g	3.95g	0.33g	0.38g	0.71g	patent
F7	290g	605g	315g	fertile	100%	63	12	1.82g	2.0g	3.82g	0.30g	0.33g	0.63g	patent
F8	325g	555g	230g	fertile	100%	53	11	1.78g	1.90g	3.68g	0.32g	0.34g	0.66g	patent
F9	305g	605g	300g	fertile	60%	36	12	1.72g	1.08g	2.80g	0.28g	0.18g	0.46g	patent
F10	310g	540g	230g	fertile	60%	31	10	1.72g	1.70g	3.42g	0.32g	0.31g	0.63g	patent
mean values	297g	559g	262g	10%	76%	45	12	1.65g	1.87g	3.52g	0.30g	0.34g	0.64g	

Appendix 15.6 Group 6 Tight Repair Inguinal Ring

Rat No	Initial body wt	Final body wt	Weight gain	Fertile or Sterile	Preg. rate	Litter size	Mean litter size	Right testis weight	Left testis weight	Total testes weight	Wt Rt testis/100g body wt	Wt Lt testis/100g body wt	Total testes wt/100g body wt	Vasography
G1	300g	650g	350g	fertile	60%	45	15	1.90g	1.81g	3.71g	0.29g	0.28g	0.57g	patent
G2	270g	540g	270g	fertile	100%	67	13	1.76g	2.07g	3.83g	0.33g	0.38g	0.71g	patent
G3	280g	510g	230g	fertile	100%	63	13	1.95g	1.80g	3.75g	0.38g	0.35g	0.73g	patent
G4	305g	550g	245g	fertile	60%	41	10	1.83g	1.76g	3.59g	0.33g	0.32g	0.65g	patent
G5	295g	590g	195g	fertile	60%	30	10	1.90g	1.90g	3.80g	0.32g	0.32g	0.64g	patent
G6	295g	590g	195g	fertile	60%	39	13	1.64g	1.63g	3.27g	0.28g	0.28g	0.56g	patent
G7	265g	480g	215g	fertile	40%	28	14	1.71g	1.93g	3.64g	0.36g	0.40g	0.76g	patent
G8	310g	515g	205g	sterile	-	-	-	0.50g	1.76g	2.26g	0.10g	0.34g	0.44g	not patent
G9	320g	588g	268g	fertile	80%	41	10	1.45g	1.50g	2.95g	0.28g	0.29g	0.57g	patent
G10	320g	588g	268g	fertile	60%	30	10	2.10g	2.10g	4.20g	0.36g	0.36g	0.72g	patent
mean values	296g	553g	257g	10%	71%	43	12	1.67g	1.83g	3.5g	0.30g	0.33g	0.63g	

Appendix 15.7 Group 7 Loose Repair Inguinal Ring

Rat No	Initial body wt	Final body wt	Weight gain	Fertile or Sterile	Preg. rate	Litter size	Mean litter size	Right testis weight	Left testis weight	Total testes weight	Wt Rt testis/100g body wt	Wt Lt testis/100g body wt	Total testes wt/100g body wt	Vasography
H1	300g	688g	388g	fertile	60%	44	15	1.67g	1.70g	3.37g	0.24g	0.25g	0.49g	patent
H2	280g	535g	265g	fertile	40%	25	13	1.76g	1.71g	3.47g	0.33g	0.32g	0.65g	patent
H3	315g	656g	341g	sterile	-	-	-	1.40g	2.0g	3.40g	0.21g	0.30g	0.51g	not patent
H4	295g	515g	320g	sterile	-	-	-	1.0g	1.51g	2.51g	0.19g	0.29g	0.48g	not patent
H5	275g	540g	265g	sterile	-	-	-	1.35g	1.72g	3.07g	0.25g	0.32g	0.57g	not patent
mean values	293g	587g	294g	60%	50%	35	14	1.44g	1.73g	3.17g	0.24g	0.30g	0.54g	

Appendix 15.8 Group 8 Strip and Tight Repair Right Inguinal Ring

Rat No	Initial body wt	Final body wt	Weight gain	Fertile or Sterile	Preg- rate	Litter size	Mean litter size	Right testis weight	Left testis weight	Total testes weight	Wt Rt testis/100g body wt	Wt Lt testis/100g body wt	Total testes wt/100g body wt	Vasography
I1	290g	585g	295g	fertile	60%	30	10	1.76g	1.82g	3.58g	0.30g	0.31g	0.61g	patent
I2	310g	588g	278g	sterile	-	-	-	1.89g	1.87g	3.76g	0.32g	0.32g	0.64g	patent
I3	315g			culled	due	to	scrotal	ab	scss	2	weeks	post	op.	
I4	300g	590g	290g	sterile	-	-	-	2.13g	1.81g	3.94g	0.36g	0.31g	0.67g	not patent
I5	305g	615g	310g	fertile	60%	30	13	1.72g	1.73g	3.45g	0.28g	0.28g	0.56g	patent
mean values	301g	595g	294g	50%	60%	35	12	1.88g	1.81g	3.69g	0.32g	0.31g	0.63g	

Appendix 15.9 Group 9 Strip plus loose repair right inguinal ring

Rat No	Initial body wt	Final body wt	Weight gain	Fertile or Sterile	Preg. rate	Litter size	Mean litter size	Right testis weight	Left testis weight	Total testes weight	Wt Rt testis/100g body wt	Wt Lt testis/100g body wt	Total testes wt/100g body wt
I 1	124g	520g	396g	sterile	-	-	-	1.0g	1.95g	2.95g	0.19g	0.38g	0.57g
I 2	106g	550g	444g	sterile	-	-	-	1.65g	1.92g	3.57g	0.30g	0.35g	0.65g
I 3	90g	540g	450g	fertile	60%	29	10	1.65g	1.64g	3.29g	0.31g	0.30g	0.61g
I 4	96g	500g	404g	fertile	40%	2	11	1.88g	1.10g	2.98g	0.38g	0.22g	0.60g
I 5	94g	470g	376g	fertile	60%	37	12	1.70g	1.71g	3.41g	0.36g	0.36g	0.72g
I 6	116g	555g	439g	sterile	-	-	-	0.90g	2.20g	3.10g	0.16g	0.40g	0.56g
I 7	106g	520g	414g	fertile	60%	42	14	1.87g	1.88g	3.75g	0.36g	0.36g	0.72g
I 8	108g	600g	492g	sterile	-	-	-	1.75g	1.80g	3.55g	0.29g	0.30g	0.59g
I 9	104g	500g	396g	sterile	-	-	-	1.92g	1.86g	3.78g	0.38g	0.37g	0.75g
I 10	106g	530g	424g	fertile	60%	25	8	1.78g	1.72g	3.50g	0.34g	0.32g	0.66g
mean values	105g	529g	424g	50%	56%	31	11	1.71g	1.77g	3.48g	0.31g	0.30g	0.61g

Appendix 15.10 Fertility data on stripping the immature vas deferens - repeat study

Rat No	Initial body wt	Final body wt	Weight gain	Fertile or Sterile	Preg. rate	Litter size	Mean litter size	Right testis weight	Left testis weight	Total testes weight	Wt Rt testis/100g body wt	Wt Lt testis/100g body wt	Total testes wt/100g body wt
Control	290g	615g	325g	fertile	80%	39	10	1.86g	1.56g	3.42g	0.30g	0.25g	0.56g
Control	295g	566g	265g	fertile	100%	54	11	1.76g	1.76g	3.46g	0.31g	0.30g	0.62g
Control	310g	530g	220g	fertile	100%	61	12	1.8g	1.89g	3.73g	0.33g	0.34g	0.68g
Crush	275g	430g	155g	sterile	80%	49	12	2.00g	1.91g	3.91g	0.38g	0.36g	0.77g
Strip	290g	595g	305g	sterile	-	-	-	1.55g	1.56g	3.11g	0.36g	0.36g	0.72g
Strip	300g	535g	235g	sterile	-	53+2+	11	1.85g	1.97g	3.82g	0.31g	0.33g	0.64g
Strip	305g	566g	265g	fertile	100%	39	13	1.80g	1.84g	3.64g	0.34g	0.34g	0.68g
Strip	106g	556g	444g	sterile	60%	-	-	1.84g	1.80g	3.64g	0.33g	0.32g	0.65g
Strip	94g	470g	376g	sterile	60%	37	12	1.65g	1.92g	3.57g	0.30g	0.35g	0.65g
Strip	108g	600g	492g	sterile	-	-	-	1.76g	1.71g	3.41g	0.36g	0.36g	0.72g
Tgt rep	300g	580g	280g	sterile	-	-	-	1.75g	1.80g	3.55g	0.29g	0.30g	0.59g
Tgt rep	305g	603g	300g	fertile	60%	36	12	0.6g	2.40g	3.0g	0.10g	0.41g	0.51g
Tgt rep	310g	540g	230g	fertile	60%	31	10	1.72g	1.08g	2.80g	0.28g	0.18g	0.46g
Tgt rep	280g	510g	230g	fertile	100%	63	13	1.95g	1.70g	3.42g	0.32g	0.31g	0.63g
Loo rep	310g	515g	205g	sterile	-	41	10	1.98g	1.80g	3.75g	0.38g	0.35g	0.73g
Loo rep	320g	515g	195g	fertile	80%	-	-	0.50g	1.76g	2.26g	0.10g	0.34g	0.44g
Strip +	295g	515g	320g	sterile	-	-	-	1.45g	1.56g	2.95g	0.28g	0.29g	0.57g
Tgt rep	275g	540g	265g	sterile	-	-	-	1.0g	1.51g	2.51g	0.19g	0.29g	0.48g
Strip +	290g	585g	295g	fertile	60%	30	10	1.35g	1.72g	3.07g	0.25g	0.32g	0.57g
Strip +	300g	590g	290g	sterile	-	-	-	1.76g	1.82g	3.58g	0.30g	0.31g	0.61g
Strip +	305g	615g	310g	fertile	60%	39	13	2.13g	1.81g	3.94g	0.36g	0.31g	0.67g
Loo rep	305g	615g	310g	fertile	60%	39	13	1.72g	1.73g	3.45g	0.28g	0.28g	0.56g

Appendix 16.1 Fertility data on animals used in autonomic and peptidergic study

Category	No. of vasa	Rapid contraction amplitude in mm.	Rapid cont. total in mm.	Mean rapid cont. in mm.	Tonic contraction in mm.	Total tonic cont. in mm.	Mean tonic cont. in mm.
Control vasa	6	69,121,40,95, 115,80.	570	95	35,49,32,48, 54,28.	286	41
Vasectomy	12	21,14,18,25,14, 19,27,27,14,25, 15,17.	236	20	8,4,5,5,5,6,8, 3,4,4,5.	62	5
Right operat. manipulation	10	13,45,30,15,19, 11,25,12,13,36.	219	22	3,9,11,4,2,3, 3,2,4,13.	54	5
Sterile operat. vasa	5	13,19,11,12,13.	68	14	3,2,3,2,4.	14	3
Fertile operat. vasa	5	45,30,15,25,36.	151	30	9,11,4,3,13.	40	8

Appendix 17.1 Amplitude of rapid and tonic contractions

## **Section 5**



## Chapter 22

### References

1. Ahlquist R P (1948). A study of the adrenotropic receptors. *Amer J Physiol*; 153: 89-137.
2. Alberts P, Bartfai T, Stjarne L (1981). Site(s) and ionic basis of alpha-autoinhibition and facilitation of (3H)noradrenaline secretion in guinea-pig vas deferens. *J Physiol*; 312: 297-334.  
Alm P (1982). On the autonomic innervation of the human vas deferens. *Brain Res Bull*; 9: 673-677.
3. Alm P, Alumets J, Hakanson R, Owman O, Sjöberg N O, Sundler F, Walles B (1980). Origin and distribution of VIP (vasoactive intestinal polypeptide)- nerves in the genito - urinary tract. *Cell Tissue Res*; 205: 337-347.
4. Alexander N J (1973). Autoimmune hypospermatogenesis in vasectomised guinea pigs. *Contraception*; 8: 147-164.
5. Alexander N J (1976). Vasectomy: Morphological and immunological effects. In: Hafez E S E (ed). *Human semen and fertility regulation in men*. Mosby, Saint Louis, p 308-317.
6. Alexander N J (1977b). Sperm antibodies and infertility. In Cockett A T K, Urry R L (eds). *Male Infertility*. Grune & Stratton, New York, San Francisco, London p 123

7. Alexander N J, Anderson D J (1979). Vasectomy: consequences of autoimmunity to sperm antigens.  
Fertil Steril; 32: 253-260.
8. Alexander N J, Clarkson T B (1978). Vasectomy increases the severity of diet - induced atherosclerosis in *Macaca fascicularis*.  
Science; 201: 538-541.
9. Alexander N J, Free M J, Paulsen C A, Buschbom R, Fulgham D L (1980). A comparison of blood chemistry, reproductive hormones and the development of antisperm antibodies after vasectomy in men. J Androl; 1: 40-50.
10. Alexander N J, Wilson B J, Patterson G D (1974). Vasectomy: immunologic effects in rhesus monkeys and men.  
Fertil Steril; 25: 149-156.
11. Amann R P, Hokason J F, Almquist J O (1963). Cannulation of bovine ductus deferens for quantitative recovery of epididymal spermatozoa. J Reprod Fertil; 6: 65-69.
12. Ambache N, Zar M A (1970). Non-cholinergic transmission by post ganglionic motor neurones in the mammalian bladder  
J Physiol (Lond); 210: 761-763.
13. Amobi, N I B, Smith I C H (1987a). Effects of alpha,beta-methylene-ATP on biphasic responses of rat vas deferens.  
Eur J Pharmac; 133: 75-82.

14. Amobi N I B, Smith I C H (1987b). Adrenergic and 'non-adrenergic' contributions to the two- component tetanus in the rat vas deferens. *Eur J Pharmacol*; 135: 173-182.
15. Anderson D J, Alexander N J (1979). Consequences of autoimmunity to sperm antigens in vasectomized men. *Clin Obst Gynaec*; 6: 425-442.
16. Ansbacher R (1973). Vasectomy: sperm antibodies. *Fertil Steril*; 24: 788-792.
17. Anstey M D, Birmingham A T (1980). The isolated circular muscle layer of the vas deferens of the guinea-pig. *Brit J Pharmacol*; 69: 233-239.
18. Anton P G, Duncan M E, McGrath J C (1977). An analysis of the anatomical basis for the mechanical response to motor nerve stimulation of the rat vas deferens. *J Physiol*; 273: 23-43.
19. Anton P G, McGrath J C (1977). Further evidence for adrenergic transmission in the human vas deferens. *J Physiol*; 273: 45-55.
20. Ashoori F, Tomita T. (1983). Mechanical response to noradrenaline in calcium-free solution in rat vas deferens. *J Physiol*; 338: 165-178.

21. Averbach P, Wright D G D (1979). Seminiferous tubular hypercurvature: a newly recognised common syndrome of human male infertility. *Lancet*; 1: 181-183.
22. Axelrod J (1972). Dopamine-beta-hydroxylase: regulation of its synthesis and release from nerve terminals. *Pharmacol Rev*; 24: 233-243.
23. Ayvaliotis B, Bronson R, Rosenfield D, Cooper G (1985). Conception rates in couples where autoimmunity to sperm is detected. *Fertil Steril*; 43: 739-742.
24. Bacq, Z M (1934). La pharmacologie du systeme nerveux autonome et particulierment du sympathique d'apres la theorie neurohumorale. *Ann de Physiol*; 10: 467-553.
25. Ball R Y, Naylor C P E, Mitchinson M J (1982). Spermatozoa in an abdominal lymph node after vasectomy in a man. *J Reprod Fert*; 66: 715-716.
26. Ball R Y, Setchell B P (1983). The passage of spermatozoa to regional lymph nodes in testicular lymph following vasectomy in rams and boars. *J Reprod Fert*; 68: 145-153.
27. Bandivdekar A H, Vijayalak-Shmi S, Moodbidri S S, Sheth A R (1982). Low molecular weight Inhibin from sheep, human rat and chicken testes. *J Androl*; 3: 140-143.

28. Barger G, Dale H H (1910). Chemical structure and sympathomimetic action of amines.  
J Physiol (Lond);11: 19-59.
29. Bartsch G, Frank St, Merberger M, Mikuz G (1980). Testicular torsion. Later results with special regard to fertility and endocrine function. J Urol; 124: 375-378.
30. Batra S K (1974). Sperm transport through vas deferens: review of hypotheses and suggestions for a quantitative model.  
Fertil Steril; 25: 186-202.
31. Baumgarten H G, Holstein A F, Rosengren E (1971). Arrangement, ultrastructure, and adrenergic innervation of smooth musculature of the ductuli efferentes, ductus epididymis and ductus deferens of man.  
Z. Zellforsch. Mikrosk Anat; 120: 37-79.
32. Beckeringh J J, Thoolen M J M C, De Jonge A, Wilffert B, Timmermans P B M W M, Van Zwieten P A (1984). Differential effects of the calcium entry blocker D600 on contractions of rat and guinea-pig aortas, elicited by various alpha-1-adrenoceptor agonists.  
J Pharmac Exp Ther; 229: 515-521.
33. Bedford J M (1976). Adaptions of the male reproductive tract and the fate of spermatozoa following vasectomy in the rabbit, rhesus monkey, hamster and rat.  
Biol Reprod; 14: 118-142.

34. Benham C D, Hess P, Tsien R W (1987). Two types of calcium channels in single smooth muscle cells from rabbit ear artery studied with whole- cell and single channel recordings. *Circ Res*;61:110-116.
35. Berridge M J (1984). Inositol trisphosphate and diacylglycerol as second messengers. *Biochem J*; 220: 345-360.
36. Berridge M J, Irvine R F (1984). Inositol trisphosphate, a novel second messenger in cellular signal transduction. *Nature*; 312: 315-321.
37. Bigazzi P E, Kosuda L L, Harnick L L (1977). Sperm autoantibodies in vasectomized rats of different inbred strains. *Science*; 197: 1282-1283.
38. Birmingham A T, Freeman M A (1976). The relation between the stimulus frequency and the relative size of the components of the biphasic response of the vas deferens to electrical stimulation at different temperatures. *J Physiol*; 256: 747-759.
39. Blakeley A G H, Brown D A, Cunnane T C, French A M, McGrath J C, Scott N C (1981). Effects of nifedipine on electrical and mechanical response of rat and guinea pig vas deferens. *Nature*; 294: 759-761.
40. Blakeley A G H, Cunnane T C (1979). The packeted release of transmitter from the sympathetic nerves of the guinea-pig vas deferens: an electrophysiological study. *J Physiol*; 296: 85-96.

41. Blakeley A G N, Cunnane T C (1982). An electrophysiological analysis of the effects of cooling on autonomic neuromuscular transmission in the guinea-pig vas deferens. *Quarterly J Exp Physiol*; 67: 617-628.
42. Blakeley A G H, Cunnane T C, Maskell T, Mathie A, Petersen S A (1984). Alpha-adrenoceptors and facilitation at a sympathetic neuroeffector junction. *J Auton Pharmac*; 4: 53-58.
43. Blakeley A G H, Dearnaley D P, Harrison V (1970). The noradrenaline content of the vas deferens of the guinea-pig. *Proc Roy Soc Lond* ; 174: 491-502.
44. Blakeley A G H, Dunn P M, Petersen S A (1988). A study of the actions of P1-purinoceptor agonists and antagonists in the mouse vas deferens in vitro. *Br J Pharmacol*; 94: 37-46.
45. Blakeley A G H, Mathie A, Petersen S A (1986). Interactions between the effects of yohimbine, clonidine and (Ca)<sup>2+</sup> on the electrical response of the mouse vas deferens. *Br J Pharmacol*; 88: 807-814.
46. Blandau R J, Gaddum R P (1974). Mechanism of sperm transport in pig oviducts. *Fertil Steril*; 25: 61-67.
47. Boeminghaus H (1957). Transport des spermas in vas deferens. *Verh Ber Dtsch Ges Urol Sonderbd Z Urol*; 138: 140-143.

48. Brading A, Bulbring E, Tomita T (1969). The effect of sodium and calcium on the action potential of the smooth muscle of the guinea pig taenia coli. *J Physiol*; **200**: 637-654.
49. Brandt H, Acott T S, Johnson D J, Hoskins D D (1978). Evidence for an epididymal origin of bovine sperm forward motility protein. *Biol Reprod*; **19**: 830-835.
50. Bronson R A, Cooper G W, Rosenfield D L (1982A). Correlation between regional specificity of antisperm antibodies to the spermatozoan surface and complement- mediated sperm immobilization. *Am J Reprod Immunol*; **2**: 222-224.
51. Bronson R A, Cooper G W, Rosenfield D L (1982B). Sperm specific isoantibodies and autoantibodies inhibit the binding of human sperm to the human zona pellucida. *Fertil Steril*; **38**: 724-729
52. Bronson R A, Cooper G W, Rosenfield D L (1983). Complement-mediated effects of sperm head-directed human antibodies on the ability of human spermatozoa to penetrate zona- free hamster eggs. *Fertil Steril*; **40**: 91-95.
53. Brown R D, Barger K D, Taylor P (1984). Alpha-1-adrenergic receptor activation mobilises cellular calcium in a muscle cell line. *J Biol Chem*; **259**: 7554-7562.



54. Brown D A, Docherty J R, French A M, MacDonald A, McGrath J C, Scott N C (1983). Separation of adrenergic and non-adrenergic contractions to field stimulation in the rat vas deferens. *Br J Pharmacol*; 79: 379-393.
55. Brown G L, Gillespie J S (1957). The output of sympathetic transmitter from the spleen of the cat. *J Physiol*; 138: 81-102.
56. Brown P C, Glynn L E (1969). The early lesion of experimental allergic orchitis in guinea pigs: an immunological correlation. *J Pathol*; 98: 277-282.
57. Bryant M G, Bloom S R, Albuquerque R H et al,(1976b). Proceedings: Dual role for vasoactive intestinal peptide- peripheral hormone and neurotransmitter. *Gut*;17: 394.
58. Bryant M G, Polak M M, Modlin I et al.(1976a). Possible dual role for vasoactive intestinal polypeptide as gastrointestinal hormone and neurotransmitter substance. *Lancet*;1: 991-993.
59. Buckner C K, Bohuski K, Ryan C F (1975). Influence of temperature and cocaine on responses of the isolated mouse vas deferens to adrenergic amines. *Arch Int Pharmacodyn Ther*; 216: 19-27.
60. Bulbring E, Tomita T (1987). Catecholamine action on smooth muscle. *Pharmacol Rev*; 39: 49-96.

61. Bulloch J M, McGrath J C (1988). Blockage of vasopressor and vas deferens responses by alpha,beta-methylene ATP in the pithed rat. *Br J Pharmacol*; 94: 103-108.
62. Burgess G M, Godfrey P P, McKinney J S, Berridge M J, Irvine I R, Putney J W (1984). The second messenger linking receptor activation to internal calcium release in liver. *Nature*; 309: 63-66.
63. Burns J, Parkes T (1967). Peristaltic motion. *J Fluid Mech*; 29: 731-743.
64. Burnstock G (1970). Structure of smooth muscle and Its innervation in 'smooth' muscle. Bulbring E, Brading A F, Jones A W, Tomita T, eds. Edward Arnold Pub Co, London; 1-69.
65. Burnstock G (1979). Autonomic innervation and transmission. *Br Med Bulletin*; 35: 255-267.
66. Burnstock G (1986a). The changing face of autonomic neurotransmission. *Acta Physiol Scand*; 126: 67-91.
67. Burnstock G (1986b). Purines as cotransmitters in adrenergic and cholinergic neurones. *Progress in Brain Research*; 68: 193-203.
68. Burnstock G, Costa M (1975). Adrenergic neurons - their organisation, function & development: In the Peripheral Nervous System. Chapman & Hall (London).

69. Burnstock G, Holman M E (1966). Junction potentials at adrenergic synapses. *Pharmacol Rev*; 18: 481-493.
70. Burnstock G, Kennedy C (1985). Is there a basis for distinguishing two types of P2- purinoceptor? *Gen Pharmac*; 16: 433-440.
71. Busatto P A, Jurkiewicz A, 1985. Simultaneous measurement of contractile effects in the circular & longitudinal smooth muscle of the rat vas deferens by drugs perfused externally or via the lumen. *Br J Pharmacol*; 85: 737-746.
72. Byrne N G, Large W A (1985). Evidence for two mechanisms of depolarisation associated with alpha-1-adrenoceptor activation in the rat anococcygeus muscle. *Br J Pharmacol*; 86: 711-721.
73. Byrne N G, Large W A (1986). The effects of alpha, beta-methylene-ATP on the depolarisation evoked by noradrenaline (gamma-adrenoceptor response) and ATP in the immature rat basilar artery. *Br J Pharmacol*; 88: 6-8.
74. Byrne N G, Large W A (1987). Action of noradrenaline on single smooth muscle cells freshly dispersed from the rat anococcygeus muscle. *J Physiol*; 389: 513-525.
75. Campbell G (1970). Autonomic nervous system to effector tissues In 'Smooth Muscle'.(Bulbring E, Brading A F, Jones A W, Tomita T, eds). Edward Arnold Publ Co London; 451-494.

76. Canessa de Scarnati O, Lapetina E G (1974).  
Adrenergic stimulation of phosphatidylinositol labelling in rat vas deferens. *Biochem Biophys Acta*; 360: 298-313.
  
77. Cannon W B, Bacq Z M (1931). Sur le passage dans le sang d'une substance active au cours de la stimulation sympathique des muscles lesses. *Ann de Physiol*;7: 173-175.
  
78. Chakraborty J, Jhunjhunwala J (1982). Experimental unilateral torsion of the spermatic cord in guinea pigs. *J Androl*; 3: 117-123.
  
79. Clanachan A S, Johns A, Paton D M (1977).  
Presynaptic inhibitory actions of adenine nucleotides & adenosine on neurotransmission in the rat vas deferens. *Neuroscience*; 2: 597-602.
  
80. Coates J, Jahn U, Weetman D F (1982). The existence of a new subtype of alpha-adrenoceptor on the rat anococcygeus is revealed by SGD101/75 and phenoxybenzamine. *Br J Pharmacol*; 75: 549-552.
  
81. Collazo E F, Thierer E, Mancini R E (1972). Immunologic and testicular responses in guinea pigs after unilateral thermal orchitis. *J Allergy Clin Immunology*; 49: 167-173.
  
82. Dawson A P, Irvine R F (1984). Inositol trisphosphate-promoted calcium release from microsomal fractions of rat liver. *Biochem Biophys Res Comm*; 120: 858-864.

83. De Kretsner D M, Burger H G, Fortune D, Hudson B, Long A R, Paulsen C A, Taft H P (1972).  
J Clin Endocrinol Metab; 35: 392-401.
84. Del Castillo J, Katz B (1954). Quantal components of the end-plate potential. J Physiol; 124: 560-573.
85. De Palma L, Carter D, Weiss R (1988).  
Epididymal and vas deferens immaturity in cryptorchidism.  
J Urol; 140: 1194-1196.
86. Dixon J S, Gosling J A (1972). The distribution of autonomic neurons in the musculature of the rat vas deferens. A light & electron microscope investigation.  
J Comp Neurol; 146: 175-188.
87. Docherty J R (1984). An investigation of presynaptic alpha-adrenoceptor subtypes in the pithed rat heart & in the rat isolated vas deferens. Br J Pharmacol; 66: 55-63.
88. Docherty J R (1987). A premature proposal?  
Trends in Pharmacol Sci; 8: 123.
89. Drew G M (1985). What do antagonists tell us about alpha-adrenoceptors. Clinical Sciences; 68 [Suppl 10]: 15s-19s.
90. Dubin L, Amelar R D (1971). Etiologic factors in 1294 consecutive cases of male infertility.  
Fertil Steril; 22: 469-474.

91. Dubocovich R K, Langer S Z (1974). Negative feedback regulation of noradrenaline release by nerve stimulation in the perfused cat's spleen: Differences in potency of phenoxybenzamine in blocking pre- and post-synaptic adrenergic receptors. *J Physiol*; 237: 505-519.
92. Dubocovich R K, Langer S Z (1975). Evidence against a physiological role of prostaglandins in the regulation of noradrenaline release in the cat spleen. *J Physiol*; 251: 737-762.
93. Dunn P M, Blakeley A G H (1988). Suramin: a P2-purinoceptor antagonist in the mouse vas deferens. *Br J Pharmacol*; 93: 243-245.
94. Ekblad E, Edvinsson L, Wahlestedt C, Uddman R, Hakanson R, Sundler F (1984). Neuropeptide Y co-exists and co-operates with noradrenaline in perivascular nerve fibres. *Regul Pept*; 8: 225-235.
95. Eliasson R (1959). Studies on prostaglandin occurrence, formation and biological action. *Acta Physiol Scand*; 46 (suppl 158): 1-73.
96. Eliasson R (1971). Standards for the investigation of human semen. *Andrologia*; 3: 49-64.
97. Eliasson R, Lindholmer C (1971). Zinc in human seminal plasma. *Andrologia*; 3: 147-153.
98. Elliott T R (1904). On the action of adrenaline. *J Physiol*; 31: 20-21.

99. Enero M A, Langer S Z, Rothlin R P, Stefano F J E (1972).  
The role of the alpha adrenoceptor in regulating noradrenaline  
overflow by nerve stimulation. *Br J Pharmacol*; 44: 672-688.
100. Enero M A, Large W A (1973). Influence of reserpine-induced  
depletion of noradrenaline on the negative feedback mechanism for  
transmitter release during nerve stimulation.  
*Br J Pharmacol*; 49: 214-225.
101. Fahlstrom G, Holmberg L, Johansson H (1963). Atrophy of the testis  
following operations upon the inguinal region in infants and  
children. *Acta Chir Scand*; 126: 221-232.
102. Fedan J S, Hogaboom G K, O'Donnell J P, Colby J, Westfall D P  
(1981). Contribution by purines to the neurogenic response of the  
vas deferens of the guinea pig. *Eur J Pharmacol*; 69: 41-53.
103. Fedan J S, Hogaboom G K, O'Donnell J P (1986).  
Further comparison of contractions of the smooth muscle of the  
guinea-pig isolated vas deferens induced by ATP and related  
analogues. *Eur J Pharmacol*; 129: 279-291.
104. Fedan J S, Hogaboom G K, Westfall D P, O'Donnell J P (1982).  
Comparison of contractions of the smooth muscle of the guinea-  
pig vas deferens induced by ATP and related analogues.  
*Eur J Pharmacol*; 81: 193-204.
105. Ferry C B (1967). The innervation of the vas deferens of the guinea  
pig. *J Physiol [London]*; 192: 463-478.

- 
106. Fillinger E J, Langer S Z, Peree C J, Stefano F J E (1978). Location of alpha-adrenoceptors which regulate noradrenaline release in the rat submaxillary gland.  
Naunyn-Schmeidesberg's Arch Pharmacol; 304: 21-26.
- 106a. Fischer R, and Mumenthaler A (1957). Ist bilaterale herniotomie bei sauglingen und kleinkindern mit einseitiger leisten-hernie angezeigt? Helvet. Chir. Acta; 24: 346-349.
107. Fjallbrant B (1968). Sperm antibodies and sterility in man.  
Acta Obstet Gynecol Scand; [Suppl 4] 47: 5-38.
108. Flavahan N A, Vanhoutte P M (1986). Alpha-1-adrenoceptor subclassification in vascular smooth muscle.  
Trends in Pharmacol Sci; 7: 347-349.
109. Flavahan N A, Vanhoutte P M (1987). Flavahan & Vanhoutte reply.  
Trends in Pharmacol Sci; 8: 124-125.
110. Ford W C L (1982). The mode of action of 6-chloro-6-deoxysugars as antifertility agents in the male. IN: Jeffcoate S L, Sandler M (ed.). Progress towards a male contraceptive.  
Chichester: Wiley: 159-184.
111. Fortes P A G, Ellory J C, Lew V L (1973). Suramin - A potent ATPase inhibitor which acts on the inside surface of the sodium pump.  
Biochem et Biophys Acta; 318: 262-272.
112. Fox A W, Abel P W, Minneman K P (1985). Activation of alpha-1-adrenoceptors increases (3H) inositol metabolism in rat vas deferens and caudal artery. Eur J Pharmacol; 116: 145-152.



113. Franchimont P, Chari S, Hagelstein M-T, Duraiswami S (1975).  
Existence of a follicle stimulating hormone inhibitory factor  
'Inhibin' in bull seminal plasma.  
Nature (London); 257: 402-404.
114. Franchimont P, Millet D, Vendrely E, Letawe J, Legros J, Netter A  
(1972). The relationship between spermatogenesis and serum  
gonadotrophin levels in azoospermia and oligospermia.  
J Clin Endocrinol Metab; 34: 1003-1008.
115. Fredholm B B, Hedqvist P (1976). Effects of adenosine on adrenergic  
neurotransmission; prejunctional inhibition and postjunctional  
enhancement.  
Naunyn-Schmeldeberg's Arch Pharmacol; 293: 217-223.
116. French A M, Scott N C (1981). A comparison of the effects of  
nifedipine and verapamil on rat vas deferens.  
Br J Pharmacol; 73: 321-323.
117. Freund M, Davis J E (1969). Disappearance rate of spermatozoa  
from the ejaculate following vasectomy. Fertil Steril; 20: 163-170.
118. Friberg J (1974). Clinical and immunological studies on sperm-  
agglutinating antibodies in serum and seminal fluid.  
Acta Obstet Gynecol Scand; [Suppl] 36: 1-19.
119. Friberg J, Fritjofsson A (1979). Inguinal herniorrhaphy and  
sperm-agglutinating antibodies in infertile men.  
Arch Androl; 2: 317-322.

120. Friberg J, Kjessler B (1975). Sperm agglutinating antibodies and testicular morphology in fifty-nine men with azoospermia or cryptozoospermia.  
Am J Obstet Gynecol; 121: 987-990.
121. Fried G (1980). Small noradrenergic storage vesicles isolated from rat vas deferens - biochemical and morphological characterisation.  
Acta Physiol Scand Suppl; 493: 1-28.
122. Fuchs E F (1990). The significance of antisperm antibody after vasovasostomy: An update. J Urol; 143: 344A.
123. Furchgott (1959). Receptors for epinephrine and norepinephrine.  
Pharmacol Rev; 11: 429-441.
124. Furness J B, Burnstock G (1969). A comparative study of spike potentials in response to nerve stimulation in the vas deferens of the mouse, rat and guinea-pig.  
Comp Biochem Physiol; 31:337-345.
125. Furness J B, Iwayama T (1972). The arrangement and identification of axons innervating the vas deferens of the guinea pig.  
J Anat; 113: 179-196.
126. Furness J B, McLean J R, Burnstock G (1970). Distribution of adrenergic nerves and changes in neuromuscular transmission in the mouse vas deferens during postnatal development.  
Dev Biol; 21: 491-505.

127. Gershon M D (1975). The identification of neurotransmitters to smooth muscle: In 'Smooth Muscle' (Bulbring E, Brading A F, Jones A W, Tomita T, eds). Edward Arnold Publ Co London: 496-524.
128. Gilula N B, Fawcett D W, Aoki A (1976). The sertoli cell occluding junctions and gap junctions in maturing and developing mammalian testis. *Dev Biol*; 50: 142-168.
129. Ginsborg B L, Hirst G D S (1972). The effect of adenosine on the release of the transmitter from the phrenic nerve of the rat. *J Physiol*; 224: 629-645.
130. Golenhofen K (1970). Slow rhythms in smooth muscle (minute-rhythm). In 'Smooth Muscle' (Bulbring E, Brading A F, Jones A W, Tomita T, eds). Edward Arnold Publ Co London: 316-342.
131. Gomori G (1952). *Microscopic Histochemistry: Principles and Practice*. University of Chicago Press. Chicago.
132. Gotterer G, Ginsberg D, Shulman T, Banks J, Williams-Ashman H G (1955). Enzymatic coagulation of semen. *Nature*; 176: 1209-1211.
133. Gu J, Polak J M, Probert L, Islam K N, Marangos P J, Mina S, Adrian T E, McGregor G P, O'Shaughnessy D J, Bloom S R (1983). Peptidergic innervation of the human male genital tract. *J Urol*; 130: 386-391.

134. Guerin J-F, Czyba J-C, Perrin P, Rollet J (1981). Les obstruction congenitales ou acquises de l' epididyme humain: etude de la mobilite des spermatozoides en amont de l'obstruction. Bulletin de l' Association des Anatomistes; 65: 297-306.
135. Gupta I, Dhawan S, Goel G D, Saha K (1975). Low fertility rate in vasovasostomized males and its possible immunologic mechanism. Int J Fertil; 20: 183-191.
136. Halim A, Antoniou D (1973). Autoantibodies to spermatozoa in relation to male infertility and vasectomy. Br J Urol; 45: 559-562.
137. Hamilton D W, Cooper T G (1978). Gross and histological variations along the length of the rat vas deferens. Anat Rec;190: 795-809.
138. Han C, Abel P W, Minneman K P (1987). Alpha-1-adrenoceptor subtypes linked to different mechanisms for increasing intracellular Ca<sup>2+</sup> in smooth muscle. Nature; 329: 333-335.
139. Hanley H G (1955). The surgery of male subfertility. Ann R Coll Surg Engl;17: 159-183.
140. Hansson V, Trygstad O, French F S, Tindall D J, Weddington S, Petrusz P, Nayfeh S N, Ritzen E M (1974). Androgen transport and receptor mechanisms in testis and epididymis. Nature; 250: 387-389.

141. Hargreave T B (1983). Male Infertility. Hargreave T B (ed)  
Springer-Verlag, Berlin pg 1-8.
142. Hargreave T B, Busuttill A, Elton R A, Harvey J, Chan A, Chisholm  
G D (1982). Studies of testicular and epididymal damage in relation  
to the occurrence of antisperm antibodies. *Br J Urol*; 54: 769-773.
143. Harrison R G, Lewis-Jones D I, Morano De Marval M J, Connoly R C  
(1981). mechanism of damage to the contralateral testis in rats with  
an ischaemic testis. *Lancet*; ii: 723-725.
144. Hay D W P, Wadsworth R M (1983a). The effects of calcium channel  
inhibitors on twitches and noradrenaline contractions of the rat  
bisected vas deferens. *Eur J Pharmacol*; 87: 367-378.
145. Hay D W P, Wadsworth R M (1983b). The effects of calcium channel  
inhibitors and other procedures affecting calcium translocation on  
drug- induced rhythmic contractions in the vas deferens.  
*Br J Pharmacol*; 79: 347-362.
146. Heath A L, Man D K W, Eccstein H B (1984). Epididymal  
abnormalities associated with maldescent of the testis.  
*J Pediatr Surg*; 19: 47-49.
147. Hedqvist P (1974a). Prostaglandin action on noradrenaline release  
and mechanical responses in the stimulated guinea-pig vas  
deferens. *Acta Physiol Scand*; 90: 86-93.

148. Hedqvist P (1974b). Role of the alpha-receptor in the control of noradrenaline release from sympathetic nerves.  
Acta Physiol Scand; 90: 158-165.
149. Hedqvist P, Fredholm B B (1976). Effects of adenosine on adrenergic neurotransmission; prejunctional inhibition and postjunctional enhancement.  
Naunyn Schmiedebergs Arch Pharmacol; 293: 217-223.
150. Hekman A, Rumke P (1974). Antigens of semen and autoimmunity against spermatozoa in infertile men. In: Mancini R E, Martin L (eds). Male Fertility and Sterility. Academic Press, London, New York, San Francisco, p 249.
151. Hellema H W J, Rumke P (1978). Sperm autoantibodies as a consequence of vasectomy. j. Within 1 year post operation.  
Clin Exp Immunol; 31: 18-29.
152. Hendry W F (1986). Clinical significance of unilateral testicular obstruction in subfertile males.  
Br J Urol; 58: 709-714.
153. Hendry W F (1988). Role of urological surgery. In Advances in clinical andrology. Barratt C L R, Cooke I D (eds).  
M T P Press Ltd; 31-47.

154. Hendry W F, Knight R K, Whitfield H N, Stansfeld A G, Pryse-Davies J, Ryder T A, Pavia D, Bateman J R, Clarke S W (1978). Obstructive azoospermia: respiratory function tests, electron microscopy and results of surgery. *Br J Urol*; 50: 598-604.
155. Hendry W F, Levison D A, Parkinson M C, Parslow J M, Royle M G (1990). Testicular obstruction: clinicopathological studies. *Ann R Coll Surg Engl*; 72: 396-407.
156. Hendry W F, Parslow J M, Stedronska J (1983). Exploratory scrototomy in 168 azoospermic males. *Br J Urol*; 55: 785-791.
157. Hendry W F, Parslow J M, Stedronska J, Wallace D M A (1982). The diagnosis of unilateral testicular obstruction in subfertile males. *Br J Urol*; 54: 774-779.
158. Hieble J P, DeMarinis R M, Matthew W D (1986). Evidence for and against heterogeneity of alpha-1-adrenoceptors. *Life Sciences*; 38: 339-350.
159. Higuchi H, Uchida S, Murata M, Yoshida H (1985). Discrepancy between alpha1 adrenoceptor mediated contraction and the occupation theory in rat vas deferens- possible existence of a silent receptor. *Eur J Pharmacol*; 113: 37-42.
160. Hillarp N A (1959). The construction and functional organisation of the autonomic apparatus. *Acta Physiol Scand*; [suppl 46]; 175: 1-38.

161. Hinton B T, Hernandez H, Howards S S (1983). The male antifertility agents Alpha Chlorohydrin, 5- Thio-D-Glucose, and 6-Chloro-6-Deoxy-D- Glucose interfere with sugar transport across the epithelium of the rete caput epididymis. *J Androl*; 4: 216-221.
162. Hirst G D S, Neild T O (1980). Evidence for two populations of excitatory receptors for noradrenaline on arteriolar smooth muscle. *Nature*; 382: 767-768.
163. Hirst G D S, Neild T O (1981). Localisation of specialised noradrenaline receptors at neuromuscular junctions on arterioles of the guinea pig. *J Physiol*; 313: 343-350.
164. Hirst G D S, Neild T O, Silverberg G D (1982). Noradrenaline receptors on the rat basilar artery. *J Physiol*; 328: 351-360.
165. Holck M I, Jones C H M, Haeusler G (1983). Differential interactions of clonidine and methoxamine with the postsynaptic alpha-adrenoceptor of rabbit pulmonary artery. *J Cardiovasc Pharmacol*; 5: 240-248.
166. Holck M I, Marks B H (1978). Purine nucleoside and nucleotide interactions on normal and subsensitive alpha-adrenoceptor responsiveness in guinea-pig vas deferens. *J Pharm Exp Ther*; 205: 104-117.



167. Holman M E, Taylor G S, Tomita T (1977). Some properties of the smooth muscle of mouse vas deferens. *J Physiol*; 266: 751-764.
168. Holsclaw D S (1969). Cystic fibrosis and infertility. *Br Med J*; 3: 356.
169. Holsclaw D S, Perlmutter A D, Joskin H, Shwachman H (1971). Genital abnormalities in male patients with cystic fibrosis. *J Urol*; 106: 568-574.
170. Holstein A F (1969). Morphologisch studien am nebenhoden des menschlichen. In *Zwanglose Abh und Lungen ans dem Gebiet der normalen und Pathologischen Anatomie. Helft 20, Stuttgart, Georg Thieme Verlag.*
171. Howards S S, Jessee S, Johnson A (1975a). Micropuncture and microanalytical studies of the effect of vasectomy on the rat testis and epididymis. *Fertil Steril*; 26: 20-27.
172. Hukovic S (1961). Responses of the isolated sympathetic nerve ductus deferens preparation of the guinea pig. *Br J Pharmac Chemother*; 16: 188-194.
173. Hurwitz L (1986). Pharmacology of calcium channels and smooth muscle. *Ann Rev Pharmacol Toxicol*; 26: 225-258.
174. Igboeli G, Rakha A M (1970). Bull testicular and epididymal functions after long-term vasectomy. *J Anim Sci*; 31: 72-75.

175. Iversen L (1967). The uptake and storage of noradrenaline. Cambridge Printing Press.
176. Jackson M B, Gough M H, Dudley NE (1987). Anatomical findings at orchiopexy. *Br J Urol*; 59: 568-571.
177. Janik J S and Shandling B (1982). The vulnerability of the vas deferens (11): The case against routine bilateral inguinal exploration. *J Pediatr Surg*; 17: 585-588.
178. Jennings P B, McCarthy M K, Plymate S R, Wettauer J N (1975). Prevalence of circulating H L-A lymphocytotoxic antibodies in man after vasectomy. *Fertil Steril*; 26: 53-56.
179. Jensen A E (1963). Myth and culture among primitive peoples. University of Chicago Press, London.
180. Jequier A M (1985). Obstructive azoospermia: A study of 102 patients. *Clin Reprod Fertil*; 3: 21-36.
181. Jequier A M (1986). Infertility in the male. Singer A & Jordon J (eds). Churchill Livingstone.
182. Jequier A M, Crich J P, Holmes S C (1983). Incomplete obstruction of the male genital tract: a cause of oligozoospermia. *Br J Urol*; 55: 545-546.

183. Jim K F, Marinis R M, Matthew W D (1985). Measurement of calcium uptake and contractile response after activation of post-synaptic alpha-adrenoceptors in the isolated canine saphenous vein. Effects of calcium entry blockade. *Eur J Pharmacol*; 107: 199-208.
184. Jones W R (1982). Immunization against spermatozoal antigens. In: *Immunological Fertility Regulation*. Oxford: Blackwell Scientific Publications, p 121.
185. Kalsner S, Quillan M (1984). A hypothesis to explain the presynaptic effects of adrenoceptor antagonists. *Br J Pharmacol*; 82: 515-522.
186. Kaplan K A, Heuther C A (1975). A clinical study of vasectomy failure and recanalization. *J Urol*; 113: 71-74.
187. Karaki H, Weiss G B (1988). Calcium release in smooth muscle. *Life Sciences*; 42: 111-122.
188. Karup T (1978). The testis after torsion. *Br J Urol*; 50: 43-46.
189. Kaya M, Harrison R G (1975). An analysis of the effect of ischaemia on testicular ultrastructure. *J Pathol*; 117: 105-117.
190. Kenakin T P (1984). The relative contribution of affinity and efficacy to agonist activity: organ selectivity of noradrenaline and oxymetazoline with reference to the classification of drug receptors.? *Br J Pharmacol*; 81: 131-141.

191. Kennedy C, Saville V L, Burnstock G (1986). The contribution of noradrenaline and ATP to the response of the rabbit central ear artery to sympathetic nerve stimulation depend on the parameters of stimulation. *Eur J Pharmacol*; 122: 291-300.
192. Kessler D L, Smith W D, Hamilton M S, Berger R E (1985). Infertility in mice after unilateral vasectomy. *Fertil Steril*; 43: 308-312.
193. Kirkpatrick K, Burnstock G (1987). Sympathetic nerve-mediated release of ATP from the guinea pig vas deferens is unaffected by reserpine. *Eur J Pharmacol*; 138: 207-215.
194. Kirpekar S M, Puig M (1971). Effect of flow-stop on noradrenaline release from normal spleens treated with cocaine, phentolamine or phenoxybenzamine. *Br J Pharmacol*; 43: 359-369.
195. Klein R L, Lagercrantz H (1981). Noradrenergic vesicles: composition and function. In *Chemical Neurotransmission 75 Years*. (Stjarne L, Hedqvist P, Lagercrantz H, Wennmalm A, eds). Academic Press: 69-84.
196. Kobrinsky N L, Winter J S D, Reyes F I, Faiman C (1976). Endocrine effects of vasectomy in man. *Fertil Steril*; 27: 152-156.

197. Kremer J, Jager S (1980). Characteristics of anti-spermatozoal antibodies responsible for the shaking phenomenon with special regard to immunoglobulin class and antigen-reactive sites. *Int J Androl*; 3: 143-152.
198. Krepchin I P, Lau C W, Batra S K, Shack W J, Lardner T J (1974). Mechanical properties of the mammalian vas deferens in the passive phase. *Adv Biomech*; 3: 1-7.
199. Kumar D, Bremner D N, Brown P W (1989). Fertility after orchiopexy for cryptorchidism: a new approach to assessment. *Br J Urol*; 64: 516-520.
200. Kuno M, Gardner P (1987). Ion channels activated by inositol 1,4,5-trisphosphate in plasma membrane of human T-lymphocytes. *Nature*; 326: 301-304.
201. Langer S Z (1974). Presynaptic regulation of catecholamine release. *Biochem Pharmacol*; 23: 1793-1800.
202. Langer S Z (1977). Presynaptic receptors and their role in the regulation of transmitter release. *Br J Pharmacol*; 60: 481-497.
203. Langer S Z, Dubocovich M L (1981). Cocaine and amphetamine antagonise the decrease of noradrenergic neurotransmission elicited by oxymetazoline but potentiate the inhibition by alpha-methylnorepinephrine in the perfused cat spleen. *J Pharmacol Exp Ther*; 216: 162-171.

- 
204. Langley J N, Anderson H K (1895). Part IV. The internal generative organs. *J Physiol London*; **19**: 122-130.
205. Langley J N, Anderson H K (1895). Part V. Position of the nerve cells on the course of the efferent nerve fibres. *J Physiol London*; **19**: 131-139.
206. Langton P D, Huddart H (1987). The involvement of fast calcium channel activity in the selective activation of phasic contractions by partial depolarisation in rat vas deferens smooth muscle. *Gen Pharmac*; **18**: 47-55.
207. Larsson L I, Fahrenkrug J, Schaffalitzky De Muckadell O B (1976a). Localization of vasoactive intestinal polypeptide (VIP) to central and peripheral neurons. *Proc Natl Acad Sci USA*; **73**: 3197-3200
208. Lau C W, Krepchin I P, Batra S K, Shack W J, Lardner T J (1974). Mechanical behaviour of the mammalian vas deferens in the active phase. *Adv Biomech*; **3**: 17-21.
209. Leader A J, Axelrad S D, Frankowski R, Mumford S D (1974). Complications of 2,711 vasectomies. *J Urol*; **111**: 365-369.
210. Lewis-Jones D I, Morano De Marval M J, Harrison R G (1982). Impairment of rat spermatogenesis following unilateral experimental ischaemia. *Fertil Steril*; **38**: 482-490.

211. Lewis-Jones D I, Richards R C, Lynch R V, Joughin E C (1987). Immunocytochemical localisation of the antibody which breaches the blood - testis barrier in sympathetic orchio-pathia. *Br J Urol*; 59: 452-457.
212. Lilford R J, Dalton M E (1987). Effectiveness of treatment for infertility. *Br Med J*;295: 155-156.
213. Linnet L (1983). Clinical immunology of vasectomy and vasovasostomy. *Urology*; 22: 101-113.
214. London S N, Haney A F, Weinberg J B (1985). Macrophages and infertility: enhancement of human macrophage-mediated sperm killing by antisperm antibodies. *Fertil Steril*; 43: 274-278.
215. Long C J, Stone T W (1986). The effects of adenosine on receptor sensitivity in the rat vas deferens. *Eur J Pharmacol*; 132: 11-19.
216. Lotti V J, Chang R S L, Kling P (1980). Beta-2-selective adrenergic responses in the field-stimulated rat vas deferens. *Eur J Pharmacol*; 68: 385-386.
217. Lukash L, Zwiren G, Andrews G H (1975). Significance of absent vas at hernia repair in infants and children. *J Pediatr Surg*; 10: 765-769.

218. Lundberg J M, Terenius L, Hokfelt T, Goldstein M (1983). High levels of neuropeptide Y in peripheral noradnergic neurons in various mammals including man. *Neurosci Lett*; 42: 167-172.
219. Lundquist F (1949). Aspects of biochemistry of human semen. *Acta Physiol Scand*; 19 (suppl 66): 7-105.
220. MacDonald A, McGrath J C (1980). The distribution of adrenoceptors and other drug receptors between the two ends of the rat vas deferens as revealed by selective agonists and antagonists. *Br J Pharmacol*; 71: 445-458.
221. Machaly M, Dalziel H H, Sneddon P (1988). Evidence for ATP as a cotransmitter in dog mesenteric artery. *Eur J Pharmacol*; 147: 83-91.
222. Mancini R E (1976). Immunologic aspects of testicular function. Springer, Berlin, Heidelberg New York.
223. Mancini R E, Andrada J A, Saraceni D, Bachmann A E, Lavieri J C, Nemirovsky M (1965). Immunological and testicular response in man sensitized with human testicular homogenate. *J Clin Endocrinol Metab*; 25: 859-875.
224. Mandelbraum S L, Diamond M P, de Cherney A H (1987). Relationship of antisperm antibodies to oocyte fertilization and cleavage in in vitro fertilisation. *Fertil Steril*; 47: 644-651.



225. Mann T (1956). Male sex hormone and its role in reproduction. *Recent Prog Horm Res*; 12: 353-358.
226. Marshall F F, Shermeta D W (1979). Epididymal abnormalities associated with undescended testis. *J Urol*;121: 341-343.
227. Marwood R P, Beral V (1979). Disappearance of spermatozoa from ejaculate after vasectomy. *Br Med J*; 1: 87.
228. Mason K E, Shaver S L (1952). Some functions of the caput epididymis. *Ann N Y Acad Sci*; 55: 585-593.
229. Mastrogiacomo I, Zanchetta R, Graziotti P, Betterle C, Scrufari P, Lembo A (1982). Immunological and clinical study of patients after spermatic cord torsion. *Andrologia*; 14: 25-30.
230. McGrath J C (1978). Adrenergic and 'non-adrenergic' components in the contractile response of the vas deferens to a single indirect stimulus. *J Physiol*; 283: 23-39.
231. McGrath J C (1982). Evidence for more than one type of postjunctional alpha-adrenoceptor. *Biochem Pharmacol*; 31: 467-484.
232. McGrath J C (1983). Calcium-free and calcium requiring alpha responses in rat anococcygeus have differing agonist potency series. *Br J Pharmacol*; 79: 227P.

233. McGrath J C (1985). Alpha-adrenoceptor agonists and the  $\text{Ca}^{2+}$  - dependence of smooth muscle contraction: evidence for subtypes of receptors or for agonist-dependent differences in the agonist-receptor interaction? *Clinical Sciences*; 68 suppl; 10: 55-63.
234. McNeal J E (1983). The prostate gland: morphology and pathology. *Monographs in Urology*; 4: 3-33.
235. Meldrum L A, Burnstock G, (1983). Evidence that ATP acts as a cotransmitter with noradrenaline in sympathetic nerves supplying the guinea- pig vas deferens. *Eur J Pharmacol*; 92: 161-163.
236. Merimsky E, Rock M, Katz S (1982). Assessment of fertility after testicular torsion - an experimental study. *Urol Res*; 10: 51-54.
237. Merrillees N C R (1968). The nervous environment of individual smooth muscle cells in the guinea pig vas deferens. *J Cell Biol*; 37: 794-817.
238. Merrillees N C R, Burnstock G, Holman M E (1963). Correlation of fine structure and physiology of the innervation of smooth muscle in the guinea pig vas deferens. *J Cell Biol*; 19: 529-550.
239. Michell R H (1975). Inositol phospholipids and cell surface receptor function. *Biochem et Biophys Acta*; 415: 81-147.

240. Michell R H (1985). Inositol lipid breakdown as a step in alpha-adrenergic stimulus response coupling. Clinical Sciences; 68, suppl 10: 43-46.
241. Michelson L (1949). Congenital anomalies of the ductus deferens and epididymis. J Urol; 61: 384-390.
242. Minneman K P, Abel P W (1984). Relationship between alpha-1-adrenoceptor density and functional response of the rat vas deferens. Naunyn-Schmeidesberg's Arch Pharmacol; 327: 238-246.
243. Minneman K P, Mumford G K, Abel P W (1988). High efficiency coupling of alpha-1-adrenergic receptors to inositol phospholipid metabolism revealed by denervation of rat vas deferens. J Pharm Exp Ther; 224: 226-230.
244. Mitsuya H, Asai J, Suyama K, Ushida T, Hosoe K (1960). Application of X-ray cinematography in urology: Mechanism of ejaculation. J Urol; 83 : 86-92.
245. Moody C J, Meghij P, Burnstock G (1984). Stimulation of P1-purinoceptors by ATP depends partly on its conversion to AMP and adenosine and partly on direct action. Eur J Pharmacol; 97: 47-54.
246. Mostofi F K (1977). Testes scrotum and penis. In: Pathology 7th ed. Edited by Anderson W A D and Kissane J M. St Louis. The CV Mosby Co; 2:1013-1037.

247. Mutt V, Said S I (1974). Structure of the porcine vasoactive intestinal octacosapeptide. The amino acid sequence. Use of kallikrein in its determination. *Eur J Biochem*; 42: 581-589.
  
248. Naik V K, Joshi U M, Sheth A R (1980). Long-term effects of vasectomy on prostatic function in men. *J Reprod Fertil*; 58: 289-293.
  
249. Neaves W B (1975a). Biological aspects of vasectomy. In: Greep R O, Astwood E B (eds) *Handbook of physiology, Sect&*; *Endocrinology*, vol 5. American Physiological Society, Washington DC, p383.
  
250. Neaves W B (1978b). The effect of vasectomy on the testes of inbred Lewis rats. *J Reprod Fertil*; 54: 405-411.
  
251. Neumann E (1955). *The elementary character in the great mother*. Routledge and Kegan Paul. London; 89-146.
  
252. Niemi M (1965). The fine structure and histochemistry of the epithelial cells of the rat vas deferens. *Acta Anat (Basel)*; 60: 207-219.
  
253. Nikolowski W (1962). Die zeugungsfähigkeit des mannes und ihre storungen. In Grotton H A, Schonfeld W (eds). *Dermatologie und Venerologie*. Stuttgart, Georg Thieme Verlag.
  
254. Ochsner M G, Brannan W, Goddie J (1972). Absent vas deferens associated with renal agenesis. *JAMA*; 222: 1055-1056.

255. Oettle A G (1954). Morphological changes in normal human semen after ejaculation. *Fertil Steril*; 5: 227-240.
256. Pabst R (1969). Untersuchungen über bau und funktion des menschlichen samenleiters.  
*Z Anat Entwicklungsgesch*; 129: 154-176.
257. Papka R E, Cotton J P, Taurig H H (1985). Comparative distribution of neuropeptide tyrosine, vasoactive intestinal polypeptide, substance P immunoreactive, acetylcholinesterase - positive and noradrenergic nerves in the reproductive tract of the female rat.  
*Cell Tissue Res*; 242: 475-490.
258. Parkhouse H, Hendry W F (1991). Vasal injuries during childhood and their effect on subsequent fertility.  
*Br J Urol*; 67: 91-95.
259. Paton D M (1981). Presynaptic neuromodulation mediated by purinergic receptors. Chapter 6 in *Purinergic Receptors* (Ed G Burnstock). Chapman & Hall: 201-219.
260. Patrizio P, Balmaceda J, Moretti-Rojas I, Silber S, Ord T, Asch R H (1989). Low incidence of sperm antibodies in men with congenital absence of the vas deferens.  
*Fertil Steril*; 52: 1018-1021.
261. Pavia D, Agnew J E, Bateman J R M, Sheahan N F, Knight R K, Hendry W F, Clarke S W (1981). Lung microciliary clearance in patients with Youngs syndrome. *Chest*; 80: 892-895.

262. Payne A H, Dowing J R, Wong K-L (1980). Luteinising hormone receptors and testosterone synthesis in two distinct populations of Leydig cells. *Endocrinology*; **106**: 1424-1429.
263. Pepperell R J, McBain J C (1985). Unexplained infertility: a review. *Br J Obst Gynaec*; **92**: 569-580.
264. Petrovsky B V, Krylov V S and Borovikov A M (1985). Herniotomy as the cause of male sterility. *Khirurgiia (Mosk)*; **9**: 3-5.
265. Phadke A M, Padukone K (1964). Presence and significance of autoantibodies against spermatozoa in the blood of men with obstructed vas deferens. *J Reprod Fertil*; **7**: 163-170.
266. Polak J M, Pearse A G, Adams C et al. (1974). Immunohistochemical and ultrastructural studies on the endocrine polypeptide (APUD) cells of the avian gastrointestinal tract. *Experientia*; **30**: 564-567.
267. Polak J M, Pearse A G E, Garaud J C, Bloom S R (1974). Cellular localization of a vasoactive intestinal peptide in the mammalian and avian gastrointestinal tract. *Gut*; **15**: 720-724.
268. Potts I F (1957). The mechanisms of ejaculation. *Med J Aust*; **1**: 495-497.
269. Prader A (1966). Testicular size: assessment and clinical importance. *Triangle*; **7**: 240-243.

270. Price R J, Roberts T K, Green D, Boettcher B (1984).  
Anticomplementary activity in human semen and its possible  
importance in reproduction.  
Amer J Reprod Immunol; 6: 92-98.
271. Pryor J P (1983). Azoospermia. In Male Infertility. Hargreave T B (ed)  
Springer-Verlag, Berlin pg 212-226.
272. Pryor J P, Cameron K M, Collins W P, Hirsh A V, Mahony J D H,  
Pugh R C B, Fitzpatrick J (1978 c). Indications for testicular biopsy  
or exploration in azoospermia. Br J Urol; 50: 591-594.
273. Pryor J P, Pugh R C B, Cameron K N, Newton J R, Collins W P  
(1976). Plasma gonadotrophic hormones, testicular biopsy  
and seminal analysis in the men of infertile marriages.  
Br J Urol; 48: 709-717.
274. Purvis K, Saksena S K, Cekan Z, Diczfalusy E, Giner J (1976a).  
Endocrine effects of vasectomy. Clin Endocrinol (Oxf); 5: 263-272.
275. Quinlivan W L G, Sullivan H, Olsher N (1975). Circulating  
anti-spermatozoa immunoglobulin G in men after  
vasectomy. Fertil Steril; 26: 224-227.
276. Reilly W M, Saville V L, Burnstock G (1987). An assessment of the  
antagonistic activity of reactive blue 2 at P1- and P2-purinoceptors;  
supporting evidence for purinergic innervation of the rabbit portal  
vein. Eur J Pharmacol; 140: 47-53.

277. Ribeiro J A, Sebastiao A M (1986). Adenosine receptors and calcium: basis for proposing a third A3 - adenosine receptor. *Prog In Neurobiol*; 26: 179-209.
278. Richardson K C (1962). The fine structure of autonomic nerve endings in smooth muscle of the Rat vas deferens. *J Anat*; 96: 427-442.
279. Rose N R, Lucas P L (1979). Immunological consequences of vasectomy: ii. Two year summary of a prospective study, in Lepow I H, Crozier R (eds) : *Vasectomy: Immunologic and pathophysiologic effects in animals and man*. New York Academic Press.
280. Ruffolo R R (1984). Interactions of agonists with peripheral alpha-adrenergic receptors. *Fed Proc*; 43: 2910-2916.
281. Rumke P (1965). Auto-spermagglutinins. A cause of infertility in men. *Ann N Y Acad Sci*; 124: 696-701.
282. Rumke P (1972). Autoantibody formation against spermatozoa caused by extravasation of spermatozoa into the interstitium of the epididymis of aged men. *Int J Fertil*; 17: 86-88.
283. Rumke P H (1981). Can oligozoospermia be induced by autoimmunity? In *Oligozoospermia: Recent Progress in*



Andrology. Frajese G, Hafez E S E, Conti C, Fabbrini A (eds).  
New York, Raven Press p 185-197.

284. Rumke P, Hellings G (1959). Autoantibodies against spermatozoa in sterile men. *Amer J Clin Path*; 32: 357-363.
285. Rumke P, Titus M (1970). Spermagglutination in male rats by subcutaneous injected syngenic epididymal spermatozoa and by vasoligation or vasectomy. *J Reprod Fertil*; 21: 69-79.
286. Rumke P, van Amstel N, Messer E N, Bezemer P D (1974). Prognosis of fertility of men with sperm agglutins in the serum. *Fertil Steril*; 25: 393-398.
287. Rutland J, Cole P J (1980). Non-invasive sampling of nasal cilia for measurement of beat frequency and study of ultrastructure. *Lancet*; 2: 564-565.
288. Rutledge S O, Weiner N (1967). The effect of reserpine upon the synthesis of norepinephrine in the isolated rabbit heart. *J Pharmacol Exp Therap*; 157: 290-302.
289. Sackler A M, Weltman A S, Pandhi V, Schwartz R (1973). Gonadal effects of vasectomy and vasoligation. *Science*; 179: 293-295.
290. Sandhu D P S, Dixon J S, Osborn D E, George N J R (1990). Effect of surgical technique for testicular maldescent. *J Urol*; 143: 383A.

291. Sandhu D P S, Osborn D E (1991). Surgical technique for inguinal surgery may adversely affect subsequent testicular and vas function in a Wistar rat model. *Br J Urol*;68: 513-517.
292. Sandhu D P S, Osborn D E, George N J R (1989). Effect of surgical technique for testicular maldescent. *J Urol*;141: 339A.
293. Said S I, Mutt V (1970a). Potent peripheral and splanchnic vasodilator peptide from normal gut. *Nature (London)*; 225: 863-864.
294. Said S I, Mutt V (1970b). Polypeptide with broad biological activity: isolation from small intestine. *Science* 169: 1217-1218.
295. Said S I, Mutt V (1972). Isolation from porcine intestinal wall of a vasoactive octacosapeptide related to secretin and to glucagon. *Eur J Biochem*; 42: 581-589.
296. Schofield C N, Steel L (1988). Presynaptic K - channel blockade counteracts the depressant effect of adenosine in olfactory cortex. *Neuroscience*; 24: 81-91.
297. Shandling B and Janik J S (1981). The vulnerability of the vas deferens (1). *J Pediatr Surg*; 16: 461-464.
298. Shapiro A H, Jaffrin M Y, Weinberg S L (1969). Peristaltic pumping with long wave lengths at low Reynolds number. *J Fluid Mech*; 37: 799-825.

299. Shulman S, Zappi E, Ahmed U, Davis J E (1972). Immunologic consequences of vasectomy. *Contraception*; 5: 269-273.
300. Silber S J (1986). Diagnosis and treatment of obstructive azoospermia. In *Male Reproduction Dysfunction*. Santen R J, Swerdloff R S (eds). New York, Marcel Dekker. p 479-517.
301. Silber M D, Balmace D A J, Borrero C, Ord T, Asch R (1988). Pregnancy with sperm aspiration from the proximal head of the epididymis: a new treatment for congenital absence of the vas deferens. *Fertil Steril*; 50: 525-528.
302. Sjostrand N O (1965). The adrenergic innervation of the vas deferens and the accessory male genital glands. *Acta Physiol Scand*; 65[suppl 257]: 1-82.
303. Skegg D C G, Matthews J D, Guilleband J, Vessey M P, Biswas S, Ferguson K M, Kitchin Y, Mansfield M D, Sommerville I F (1976). Hormonal assessment before and after vasectomy. *Br Med J*; 1: 621-622.
304. Smith K D, Tcholakian R K, Chowdhury M, Steinberger E (1976). An investigation of plasma hormone levels before and after vasectomy. *Fertil Steril*; 27: 144-151.
305. Sneddon P, Burnstock G (1984). Inhibition of excitatory junction potentials in guinea pig vas deferens by alpha, beta-methylene-ATP: further evidence for ATP and noradrenaline as cotransmitters. *Eur J Pharmacol*; 100: 85-90.

306. Sneddon P, Westfall D P (1984). Pharmacological evidence that adenosine triphosphate and noradrenaline are cotransmitters in the guinea pig vas deferens. *J Physiol*; 347: 561-580.
307. Sneddon P, Westfall D P, Fedan J S (1982). Cotransmitters in the motor nerves of the guinea pig vas deferens: electrophysiological evidence. *Science*; 218: 693-695.
308. Sparkman R S (1962). Bilateral exploration in inguinal hernia in juvenile patients. *Surgery*; 51: 393-406.
309. Starke K (1987). Presynaptic alpha-autoreceptors. *Rev Physiol Biochem Pharmacol*; 107: 73-145.
310. Starke K, Borowski E, Endo T (1975). Preferential blockade of presynaptic alpha - adrenoceptors by yohimine. *Eur J Pharmacol*; 34: 385-388.
311. Steinach E (1920). Verjungung durch experimentelle Neubelebung der alternden Pubertatsdruse. *Arch Entwicklungsmech*; 46: 557-619.
312. Steinberger A, Steinberger E (1976). Secretion of an FSH-inhibiting factor by cultured sertoli cells. *Endocrinology*; 99: 918-921.
314. Stjarne L (1986). New paradigm: sympathetic transmission by multiple messengers and lateral interaction between monoquantal release sites. *Trends in Neurosciences*; 8: 547-548.

315. Stjarne L, Astrand P (1984). Discrete events measure single quanta of adenosine 5'-triphosphate secreted from sympathetic nerves of guinea pig and mouse vas deferens. *Neuroscience*; 13: 21-28.
316. Stjarne L, Astrand P (1985). Relative pre- and post-junctional roles of noradrenaline and adenosine 5 - triphosphate as neurotransmitters of the sympathetic nerves of guinea pig and mouse vas deferens. *Neuroscience*; 14: 929-946.
317. Stjarne L, Lundberg J M (1986). On the possible roles of noradrenaline, adenosine 5'-triphosphate and neuropeptide Y as sympathetic cotransmitters in the mouse vas deferens. *Progress in Brain Research*; 68: 263-278.
318. Stone T W (1981). Differential blockade of ATP, noradrenaline and electrically evoked contractions of the rat vas deferens by nifedipine. *Eur J Pharmacol*; 74: 373-376.
319. Sundler F, Alumets J, Fahrenkrug J, Hakanson R, Schaffalitzky de Mackadell O B (1979). Cellular localization and ontogeny of immunoreactive vasoactive intestinal polypeptide (VIP) in the chicken gut. *Cell Tissue Res*; 196: 193-201.
320. Sundler F, Alumets J, Hakanson R, Fahrenkrug J, Schaffalitzky de Mackadell O B (1978). Peptidergic (VIP) nerves in the pancreas. *Histochemistry*; 55: 173-176.
321. Sundler F, Alumets J, Hakanson R et al. (1977). VIP innervation of the gallbladder. *Gastroenterology*; 72: 1375-1377.

322. Sundler F, Moghimzadch E, Hakanson R, Ekelund M, Emson P(1983). Nerve fibres in the gut and pancreas of the rat displaying Neuropeptide - Y reactivity. Intrinsic and extrinsic origin. *Cell Tissue Res*; 230: 487-493.
323. Suzuki H (1985). Electrical responses of smooth muscle cells of the rabbit ear to adenosine triphosphate. *J Physiol (Lond)*; 359:401-415.
324. Swedin A (1971). Studies on neurotransmission mechanisms in the rat and guinea pig vas deferens. *Acta Physiol Scand*; suppl 369.
325. Takenawa T, Masaki T, Goto K (1983). Increase in norepinephrine-induced formation of phosphatidic acid in rat vas deferens after denervation. *J Biochem (Tokyo)*;93: 303-306.
326. Tauber P F, Zaneveld L J D (1976). Coagulation and liquifaction of human semen. Hafez E S E (ed) In: *Human semen and fertility regulation in men*. C. V. Mosby Company; 153-166.
327. Templeton A A, Penney G C (1982). The incidence, characteristics, and prognosis of patients whose infertility is unexplained. *Fertil Steril*; 37: 175-182.
328. Thakur A N, Sheth A R, Rao S S (1972). Biochemical studies on rat testes and sex accessory organs after vasoligation operation. *Fertil Steril*; 23: 834-837.

329. Thoenen H, Hurlimann A, Haefely W (1964). The effect of sympathetic nerve stimulation on volume, vascular resistance and norepinephrine output in the isolated perfused spleen of the cat and its modification by cocaine.  
J Pharmacol Exp Ther; 143: 57-63.
330. Thomas W E G, Cooper M J, Smith J H F, Lee G, Williamson R C N (1984). Sympathetic orchioptia following acute testicular torsion. Br J Surg; 71: 380.
331. Tischner M (1971a). Transport of unejaculated spermatozoa through the pelvic part of the urogenital tract in the ram.  
J Reprod Fertil 24: 271-274.
332. Tischner M (1971b). Effect of vasa deferentia occlusion in the ram.  
Bull Acad Pol Sci (Biol); 19: 425-429.
333. Trubatch J, Van Harrevald A (1981). Anatomical correlates of synaptic transmission. In Chemical Neurotransmission 75 Years. (Stjarne L, Hedqvist P, Lagercrantz H, Wennmalm A, eds). Academic Press; 139-152.
334. Tsien R W (1983). Calcium channels in excitable membranes.  
Ann Rev Physiol; 45: 341-358.
335. Tung K S K (1978). Allergic orchitis lesions are adoptively transferred from vasoligated guinea pigs to syngeneic recipients. Science; 201: 833-835.

336. Turner T T (1979a). On the epididymis and its function.  
Invest Urol; 16: 311-321.
337. Turner T T, D' Addario D A, Howards S S (1979a). Effects of  
vasectomy on the blood-testis barrier of the hamster.  
J Reprod Fertil; 55: 323-328.
338. Uddman R, Alumets J, Dersert O, Hakanson R, Sundler F (1978).  
Occurrence and distribution of VIP nerves in the nasal mucosa and  
tracheobronchial wall. Acta Otolaryngol (Stockh);86: 443-448.
339. Van Calker D, Muller M, Hamprecht B (1979). Adenosine regulates  
via two different types of receptors - the accumulation of cyclic AMP  
in cultured brain cells. J Neuroscience; 33: 999-1005.
340. Vanwelkenhuyzen P (1966). La motilite du canal deferent.  
Acta Urol Belg; 34: 385-466.
341. Vare A M, Bansal P C (1973). Changes in the canine testes after  
bilateral vasectomy - an experimental study. Fertil Steril; 24: 793-797.
342. Varma M M, Varma R R, Johanson A J, Kowarski A, Migeon C J  
(1975). Long-term effects of vasectomy on pituitary- gonadal  
function in men. J Clin Endocrinol Metab; 40: 868-871.



343. Ventura W P, Freund M, Davis J (1973). Influence of norepinephrine on the motility of human vas deferens: a new hypothesis of sperm transport by the vas deferens. *Fertil Steril*; 24: 68-77.
344. Von Euler U S (1946). A specific sympathomimetic ergone in adrenergic nerve fibres (sympathin) and its relations to adrenaline and noradrenaline. *Acta Physiol Scand*; 12: 73-97.
345. Von Euler U S (1981). Historical perspective: growth and impact of the concept of chemical neurotransmission. In *Chemical Neurotransmission 75 Years*. (Stjarne L, Hedqvist P, Lagercrantz H, Wennhalm A, eds). Academic Press; 3-12.
346. Waksman B H (1959). A histologic study of the autoallergic testis lesion in the guinea pig. *J Expt Med*; 109: 311-324.
347. Walker G (1910). A special function discovered in a glandular structure hitherto supposed to form part of the prostate gland in rats and guinea pigs. *John Hopkins Medical Journal*; 21: 182-185.
348. Wallace D M A, Gunter P A, Landon G V, Pugh R C B, Hendry W F (1982). Sympathetic Orchioptasia- An experimental and clinical study. *Br J Urol*; 54: 765-768.
349. Warkany J (1966). Acrodynia - post mortem of a disease. *Am J Dis Child*; 112: 147-156.

350. Weiner N (1970). Regulation of norepinephrine biosynthesis. *Annual Rev Pharmacol*;10: 273-290.
351. Welford L A, Cusack N J, Hourani S M (1987). The structure activity relationships of ectonucleotidases and of excitatory P2 purinoceptors: evidence that dephosphorylation of ATP analogues reduces pharmacological potency. *Eur J Pharmacol*;141: 123-130.
352. Westfall D P, Stitzel R E, Rowe J N (1978). The post junctional effects and neural release of purine compounds in guinea- pig vas deferens. *Eur J Pharmacol*; 50: 27-28.
353. Whitby R M, Gordon R D, Blair B R (1979). The endocrine effects of vasectomy : a prospective five-year study. *Fertil Steril*; 31: 518-520.
354. Yamauchi A, Burnstock G (1969). Post-natal development of the innervation of the mouse vas deferens. A fine structural study. *J Anat*; 104: 17-32.
355. Young D (1951). Surgical treatment of male infertility: *Proc Soc Study Fertility*; 3: 40.
356. Young D (1970b). Surgical treatment of male infertility. *J Reprod Fertil*; 23: 541-542.

## **Section 6**

## Chapter 23

### List of publications and presentations based on this study

#### PAPERS & ABSTRACTS PUBLISHED

1. Effect of Surgical Technique for Testicular Maldescent  
D P S Sandhu, D E Osborn, N J R George  
Journal of Urology 1989; 141: 339 A
2. Effect of Surgical Technique on Innervation and Contractile  
Properties of Vas deferens  
D P S Sandhu, J S Dixon, D E Osborn, S Petersen, N J R George  
Journal of Urology 1990; 143: 383A
3. Surgical Technique for Inguinal Surgery May Adversely Affect  
Subsequent Testicular and Vas Function in a Wistar Rat Model  
D P S Sandhu, D E Osborn  
British Journal of Urology 1991; 68: 513-517.
4. Relationship of azoospermia to inguinal surgery.  
D P S Sandhu, D E Osborn, K W Munson  
International Journal of Andrology 1992; 15: 504 - 506.

#### PRESENTATIONS AT INTERNATIONAL MEETINGS

1. Effect of Surgical Technique For Testicular Maldescent  
D P S Sandhu, D E Osborn, N J R George  
American Urological Association 1989 Annual Meeting  
Dallas, Texas 5th - 10th May 1989
  
2. Effect of Surgical Technique on Innervation and Contractile  
Properties of Vas deferens  
D P S Sandhu, J S Dixon, D E Osborn, S Petersen, N J R George  
American Urological Association 1990 Annual Meeting,  
New Orleans 13 - 17 May 1990
  
3. Long Term Complications of Childhood Herniotomy and  
Testicular Maldescent  
D P S Sandhu, D E Osborn  
British Association of Paediatric Surgeons 37th Annual  
International Congress, Glasgow, Scotland 25 - 27 July 1990
  
4. The Importance of Vas Contractility, Autonomic and  
Peptidergic Innervation for Sperm Transport  
D P S Sandhu, J S Dixon, S Petersen, D E Osborn  
European Association of Urology 10th Congress  
Genoa, Italy 22 - 25 July 1992

#### PRESENTATIONS AT NATIONAL MEETINGS

1. Vas Manipulation During Hernia Repair and Infertility using a Rat Model  
D P S Sandhu, D E Osborn  
British Andrology Society Annual Meeting, St. Mary's Hospital,  
Manchester 11th - 12th November 1988
2. Effect of Surgical Technique on Sperm Transport  
D P S Sandhu, J S Dixon, S Petersen, D E Osborn  
Guy's National Research Meeting, London 12 January 1990
3. The Effects of Inguinal Surgery on Vas Deferens and Testicular Function  
D P S Sandhu  
British Association of Urological Surgeons, Nottingham 5 - 6 October 1990
4. Effect of Surgical Technique on Vas contractility, Neurohistochemistry and Sperm Transport  
D P S Sandhu, J S Dixon, S Petersen, D E Osborn  
British Fertility Society, Cambridge 16th - 17th May 1991


5. Effect of Surgical Technique on Vas contractility,  
Neurohistochemistry and Sperm Transport  
D P S Sandhu, J S Dixon, S Petersen, D E Osborn  
British & Scandanavian Andrology Society Joint meeting at the  
Royal Society of medicine, London 6th - 7th December 1991

#### PRESENTATIONS TO LEARNED SOCIETIES

1. Childhood Herniotomy, Inguinal Herniorrhaphy and  
Infertility  
D P S Sandhu, D E Osborn  
Trent Regional Paediatric Society Meeting  
Chesterfield and North Derbyshire Royal Hospital, Calow,  
Chesterfield 19th May 1988
2. Effect of Surgical Technique for Herniotomy, Inguinal  
Herniorrhaphy and Testicular Maldescent  
D P S Sandhu  
Leicester Post Graduate Clinical Research Prize  
Leicester Royal Infirmary 2nd February 1989
3. Vas Damage and Operative Manipulation - an experimental  
study. D P S Sandhu  
Trent Region Urology Meeting, Leicester 18th October 1989

4. Effect of Surgical Technique On Contractile Properties Of The  
Vas Deferens  
D P S Sandhu  
North West Urology Meeting.
  
5. The Pathophysiology of the Vas Deferens  
D P S Sandhu  
Punch Club, Leicester 8 - 9 November 1990





Reading maketh a full man  
Conference a ready man and  
Writing an exact man

**Francis Bacon Essays**

**1561 - 1626**

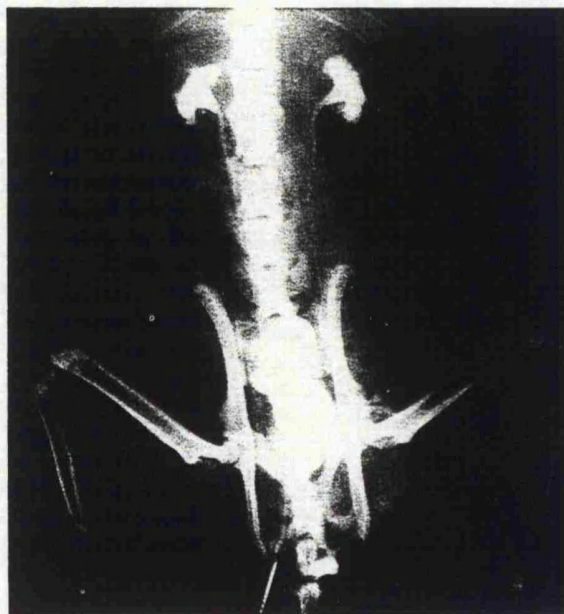
## Surgical Technique for Inguinal Surgery and its Effect on Fertility in the Wistar Rat Model

D. P. S. SANDHU and D. E. OSBORN

Department of Urology, Leicester General Hospital, Leicester

**Summary**—This study has explored the relatively neglected effects of operative manipulation of the vas deferens on fertility. Following unilateral vasectomy the contralateral vasa of 52 4-week-old Wistar rats were subjected to 7 different manipulations. After 7 weeks a fertility trial was conducted. All sham operated rats ( $n = 18$ ) were fertile. Of the remaining 34 rats, 22 (65%) were sterile. All of those with tight ring reconstruction ( $n = 6$ ) were sterile, due initially to venous obstruction. Nine of 14 rats with acute clip trauma (65%) remained fertile but 11 of 14 (78%) with full mobilisation were sterile owing to extensive avascular fibrosis of the vas deferens. These results suggest that over-zealous cord handling and operative technique in the immature animal is counterproductive and leads to vasal occlusion. This may have important repercussions in paediatric inguinal surgery, with a subsequent higher incidence of azoospermia and male subfertility.

The male contribution is significant for 25% of couples attending infertility clinics (Hull *et al.*, 1985). The outlook for the severely oligozoospermic and the azoospermic male is very poor. One preventable cause of obstructive azoospermia and male subfertility may be surgical damage to the vas deferens from operative handling of the spermatic cord during such procedures as childhood herniotomy, orchiopexy, hydrocele repair and, in the younger man, inguinal herniorrhaphy. Even in unilateral surgery, suboptimal contralateral vasa and testicular function may be further exacerbated by inadvertent damage to the healthy vasa and testis. Previous studies (Janik and Shandling, 1982) have examined histological changes in the vas deferens induced by cord handling, but fertility trials in such cases have not been performed. A Wistar rat model has been developed (Fig. 1) in order to determine what effect, if any, handling of the spermatic cord and in particular the vas deferens has on subsequent fertility.



**Fig. 1** X-ray of Wistar rat model demonstrating right vasogram with a patent vas deferens, bladder full of contrast and incidental bilateral retrograde pyelograms.

Accepted for publication 1 February 1991



### Materials and Methods

A total of 52 sexually immature, random bred male Wistar rats aged 4 weeks (weight 74–115 g) were divided into 8 groups and underwent different operative manipulations (Table 1). Apart from Group 1 (the unoperated controls), all rats underwent a vasectomy on the left side and a different operative manipulation on the right side. Groups 2 (sham) and 3 (cord mobilisation) had minimal handling of the cord. In Group 4 the artery to the vas deferens was stripped by sharp and blunt dissection. In Group 5 the vas deferens was crushed by means of an arterial clip for 30 s. A tight herniorrhaphy repair was simulated by a constricting ring reconstruction over a 2-mm diameter pin in Group 6. A looser repair over a 4 mm pin was done in association with stripping the vas and crush injury in Groups 7 and 8 respectively. All operations were performed under full aseptic technique using intraperitoneal neuroleptanalgesia.

The male rats were then caged separately and allowed to mature for a further 7 weeks. At the age of 11 weeks each male rat was caged with 5 female Wistar rats. This fertility trial lasted for 3 weeks, during which the females had at least 3 oestrus cycles. The presence of vaginal plugs confirmed mating. At the completion of the fertility trial the rats were sacrificed. The presence of pregnancy, litter size and any fetal abnormality were recorded. The weight of each testis was recorded and histological assessment of the vasa and the testis

was performed without knowledge of experimental groups.

### Statistical analysis

Comparisons within a rat group were made by means of the paired *t* test, and those between rat groups using the 2-sample *t* test.

### Results

#### Fertility

The fertility data are summarised in Table 2, giving a total sterility rate of 42%. The 18 rats in Groups 1 to 3 (no operation, sham procedure, mobilising the cord respectively) had minimal handling of the cord and all were fertile. In the remaining 5 groups, 22 of 34 rats (65%) were sterile (Table 3). In Group 4, stripping of the vasa resulted in a sterility rate of 71% (*n*=5). Severe crush injury to the vas deferens in Group 5 produced a low sterility rate, with only 2 of 7 rats sterile. In Group 6 (tight repair) all 6 rats were sterile; testicular infarction occurred in 4 but the remaining 2 had histologically normal testes and vasa deferentia (Fig. 2A). In Group 7, stripping the vasa together with loose inguinal reconstruction was particularly destructive, with a sterility rate of 86% (*n*=6). In contrast, crush injury and loose inguinal reconstruction in Group 8 resulted in a sterility rate of only 43%, with 3 of 7 rats sterile.

In Groups 4 to 8 the incidence of testicular infarction (*n*=8) was 24%, but in 4 rats it was associated with an abnormal vas deferens. In the remaining 4 animals (12%), infarction was the sole cause of infertility and these were all related to Group 6, which underwent tight reconstruction of the ring (Table 3).

The histological pattern of damage to the vas deferens in this study (Figs 2A and B) appears uniformly over a long segment, which is the case seen with post-operative occlusion (unlike infection, which is likely to produce multiple vascular blocks).

#### Testis weight

The mean left testicular weight/100 g body weight (0.48 g; SD 0.09) (Table 2) was significantly higher than that of the right (operative manipulation) (0.42 g; SD 0.17) (*P*=0.027). Comparing the fertile right testis with the sterile right testis showed the mean weight of the right testis to be less in the sterile group (0.35 g; SD 0.24) than in the fertile group (0.47 g; SD 0.06) and this was statistically significant (*P*<0.01).

Table 1 Details of Operative Procedures

Group no.	No. of rats	Operative procedure on the right side
1	3	Nil
2	8	Sham operation
3	7	Mobilising the cord only
4	7	Strip blood vessel off the vas
5	7	Crush injury arterial clip 30 s
6	6	Tight repair inguinal ring over 2 mm diam. pin
7	7	Strip blood vessel + loose repair inguinal ring over 4 mm diam. pin
8	7	Crush injury arterial clip 30 s + loose repair inguinal ring over 4 mm diam. pin

Note: In Groups 2–8 vasectomy was performed on the left side.

Table 2 Summary of Fertility Data and Testicular Weights

Group no.	No. of rats	No. fertile	Sterility rate (%)	Mean weight right testis	Mean weight left testis
1 Control	3	3	0	0.45	0.48
2 Sham	8	8	0	0.49	0.48
3 Mobilise cord	7	7	0	0.48	0.46
4 Strip	7	2	71	0.48	0.46
5 Crush	7	5	28	0.45	0.48
6 Tight repair	6	0	100	0.22	0.43
7 Strip+loose repair	7	1	86	0.37	0.49
8 Crush+loose repair	7	4	43	0.40	0.53

Weights are expressed in g/100 g body weight.

Table 3 Reasons for Sterility in Groups 4-8

Group no.	No. of rats	No. of rats sterile	Abnormal vas	Infarcted testis
4 Strip	7	5	5	—
5 Crush	7	2	2	—
6 Tight ring	6	6†	—	4
7 Strip+loose repair	7	6	6	3*
8 Crush+loose repair	7	3†	2	1*

Operated rats (n=34). Infertile rats (n=22) (65%).

In 4 cases\* both the vasa and testis were damaged and responsible for sterility. However, 3 rats† from Groups 6 and 8 were sterile despite normal vasa and testes on histology. (See text for details).

## Discussion

Since 30 to 35% of paediatric surgical practice consists of operations on the inguinal region, it is important to know what effect inguinal surgery has on the structures of the spermatic cord, especially the vas deferens. The vas deferens is a dynamic

structure. Previous surgery, infection, trauma, and even amyloidosis have all been shown to disrupt the propulsive action of the vas deferens, leading to defective sperm transport, retrograde flow, oligozoospermia and infertility (Janik and Shandling, 1982). Inadvertent transection of the vas deferens has an obvious effect. Since azoospermia may occur

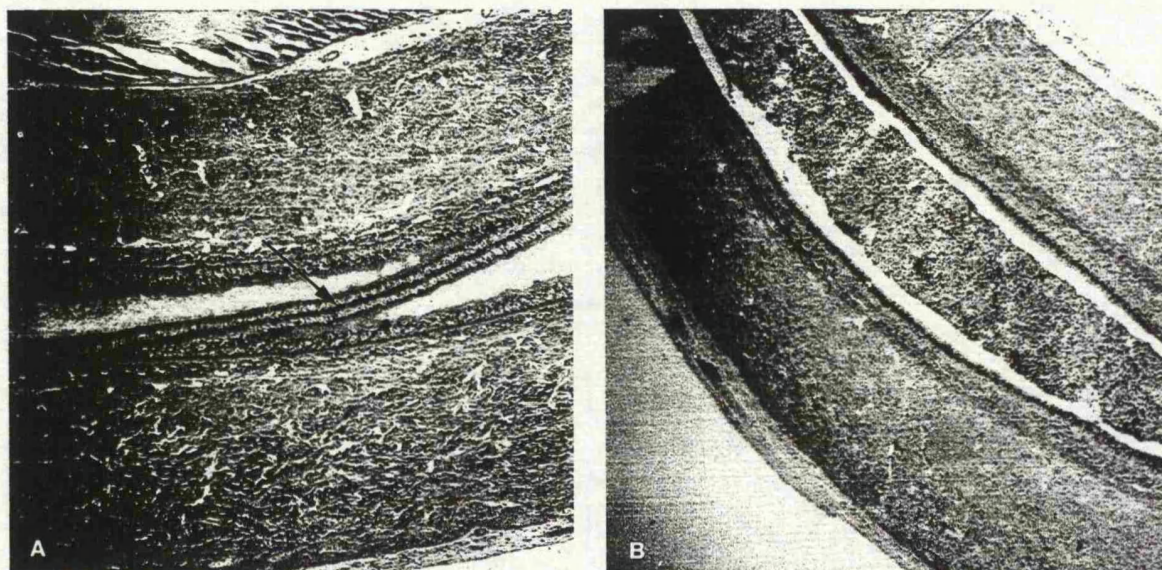


Fig. 2 (A) Normal rat vas deferens; epithelial spiral (arrow) with pseudocilia and sperm in lumen. (B) Abnormal rat vas deferens from inguinal region that had been stripped. There is loss of epithelial spiral, pseudocilia and absence of sperm with only cellular debris in the lumen.

after hernia repair despite normal testicular biopsy and vasography (Jequier, 1985), more subtle manipulations of the vas deferens may affect contractility and subsequent fertility.

Our results show that a variety of surgical techniques may significantly affect fertility. Tight ring construction and stripping the vasa are particularly destructive. Nine rats with acute clip trauma (65%) remained fertile but 11 (78%) with full mobilisation were sterile because of extensive fibrosis of the vas (Fig. 2B). Surprisingly, crush trauma over a short segment of the vas deferens did not always affect fertility.

Attention has previously been focused in animal studies on histological changes in the vas deferens (Janik and Shandling, 1982) and in the clinical context on obstructive azoospermia secondary to surgery, especially childhood herniotomy (Young, 1951; Hanley, 1955). Sparkman (1955) recorded an incidence of 1.6% following the inadvertent removal of a segment of the vas deferens with the hernia sac. Friberg and Fritjofsson (1979) investigated 76 men with sperm-agglutinating antibodies and found that 12 had undergone herniorrhaphy and were sterile. Ten were explored and 5 had vasal obstruction consistently in the area of previous surgery. Jequier (1985) described 9.8% of 102 patients with obstructive azoospermia following prior surgery or trauma. Five of these patients had

a unilateral herniotomy; only 2 of them had definite vasal obstruction on exploration; the other 3 had a patent vas deferens with a normal testis and yet were azoospermic. A similar incidence of azoospermia (13%) following inguinal herniotomy was reported by Petrovsky *et al.* (1985). The result of damage to the vas deferens and subsequent azoospermia will be obvious on semen analysis. The incidence of vas damage in unilateral herniotomy and inguinal surgery will be difficult to establish because of population movement, for the majority of the surgery is performed during childhood; masking by the contralateral side also creates problems.

Although the difficulties of extrapolating animal studies to man are acknowledged, in this study we have shown the vulnerability of the immature vas deferens. Vasectomy reversal in adults has a moderately high success rate (Linnet, 1983) and this may reflect the increased vulnerability of the immature vas deferens. Certainly in further adult Wistar rats we have found stripping of the vas to be less damaging (Sandhu and Osborn, in preparation).

Often with a unilateral lesion an assumption is made that the contralateral side is normal, but as testicular infarction or damage can occur, it is possible for an ischaemic testis to affect the contralateral side. Evidence from torsion experi-



ments in rats (Lewis-Jones *et al.*, 1987) suggests that sympathetic orchioepithia may lead to a rise in the naturally occurring serum cytotoxic antisperm antibody. It may cause a change in the specificity of this antibody, resulting in the production of an anti-testis antibody. This may be responsible for the contralateral impairment of sperm production in the absence of a cell mediated reaction (Wallace *et al.*, 1982). The present series supports on histological evidence the absence of allergic orchitis with a contralateral infarcted testis.

Antisperm antibodies following unilateral vasectomy alone may be relevant in inbred DBA/1J mice (Kessler *et al.*, 1985), which are known to be high antibody formers. Since the 15 Wistar rats (Groups 2 and 3) with unilateral vasectomy were all fertile, antisperm antibodies would not appear to be a significant problem in this study.

In summary, in the immature Wistar rat animal model the vas deferens and testis are vulnerable to operative handling, especially inguinal ring reconstruction and stripping of the cord. These results indicate the great care needed in handling the vas deferens during inguinal operations. In addition, although the vas deferens may be intact following surgery (even in unilateral cases), difficulties with sperm transport leading to obstructive azoospermia and male subfertility may be a long-term post-operative complication.

# Acknowledgements

We are grateful to Dr E. H. Mackay for his invaluable help with the histology data, and Professor D. B. Morton and Jenny Rees for technical advice and help with the fertility study. We also thank Mr D. E. Shaw for statistical analysis.

# References

- Friberg, J. and Fritjofsson, A. (1979). Inguinal herniorrhaphy and sperm-agglutinating antibodies in infertile men. *Arch. Androl.*, **2**, 317-322.
- Hanley, H. G. (1955). The surgery of male infertility. *Ann. R. Coll. Surg. Engl.*, **17**, 159.
- Hull, M. G. R., Glazener, C. M. A., Kelly, N. *et al.* (1985). Population study of causes, treatment, and outcome of infertility. *Br. Med. J.*, **291**, 1693-1697.
- Janik, J. S. and Shandling, B. (1982). The vulnerability of the vas deferens (11): the case against routine bilateral inguinal exploration. *J. Pediatr. Surg.*, **17**, 585-588.
- Jequier, A. M. (1985). Obstructive azoospermia: a study of 102 patients. *Clin. Reprod. Fertil.*, **3**, 21-36.
- Kessler, D. L., Smith, D. W., Hamilton, M. S. *et al.* (1985). Infertility in mice after unilateral vasectomy. *Fertil. Steril.*, **43**, 308-312.
- Lewis-Jones, D. I., Richards, R. C., Lynch, R. V. *et al.* (1987). Immunocytochemical localisation of the antibody which breaches the blood-testis barrier in sympathetic orchioepithia. *Br. J. Urol.*, **59**, 452-457.
- Linnet, L. (1983). Clinical immunology of vasectomy and vasovasostomy. *Urology*, **22**, 101-114.
- Petrovsky, B. V., Krylov, V. S. and Borovikov, A. M. (1985). Herniotomy as the cause of male sterility. *Khirurgia (Mosk)*, **9**, 3-5.
- Sparkman, R. S. (1955). Bilateral exploration in inguinal hernia in juvenile patients. *Surgery*, **51**, 393-406.
- Wallace, D. M. A., Gunter, P. A., Landon, G. V. *et al.* (1982). Sympathic orchioepithia—an experimental and clinical study. *Br. J. Urol.*, **54**, 765-768.
- Young, D. (1951). Surgical treatment of male infertility. *Proc. Soc. Study Fertility*, **3**, 40.

# The Authors

- D. P. S. Sandhu, FRCS, formerly Registrar, Leicester General Hospital. Now Senior Urological Registrar, City Hospital, Nottingham.
- D. E. Osborn, MS, FRCS, Consultant Urologist, Leicester General Hospital.

Requests for reprints to: D. P. S. Sandhu, Department of Urology, City Hospital, Nottingham, Hucknall Road, Nottingham NG5 1PB.

## Short Communication

### Relationship of azoospermia to inguinal surgery

D. P. S. SANDHU, D. E. OSBORN and K. W. MUNSON\*

*Departments of Urology, Leicester General Hospital and*

*\*Derbyshire Royal Infirmary*

#### Introduction

Nearly one-third of paediatric surgery consists of operations on the inguinal canal. A late complication of this is male sterility due to damage to the vas deferens. Correction of this preventable cause is problematical and there is poor outlook for the severely oligozoospermic and azoospermic male. The true incidence of unilateral damage to the vas deferens is unknown, as this can be masked by a normal reproductive tract on the contralateral side. However, occasionally more subtle changes other than direct transection and fibrosis of the vas deferens can prevent sperm transport. This may be related to damage to the vas pseudocilia, its autonomic and peptidergic innervation leading to defective contractility. This report presents four cases, which confirm the vulnerability of the vas deferens during inguinal surgery and highlight azoospermia as a late complication.

**Keywords:** azoospermia, herniotomy, vas deferens.

#### Case reports

##### *Patient 1*

A 39-year-old man was referred with azoospermia. He underwent right herniotomy at the age of 5 years and required recurrent hernia repair 3 years later. His subsequent fertility status was normal as his wife became pregnant on four occasions, but unfortunately three of these resulted in a miscarriage. A left herniorrhaphy at the age of 34 years resulted in azoospermia. Scrototomy revealed healthy testes with empty epididymis. The onset of his azoospermia appeared to be related critically to his left herniorrhaphy. The left vas deferens was surrounded with scar tissue but appeared intact. Vasography demonstrated no obstruction, and biopsy of the left testis was normal with active spermatogenesis. No immobilizing antibodies and only weakly positive agglutinating antibodies were detected.

##### *Patient 2*

A 33-year-old man with an 8-year history of azoospermia had undergone a left inguinal hernia repair at the age of 19 years, and an emergency right strangulated

Correspondence: Mr D. P. S. Sandhu, Leicester General Hospital, Gwendolen Road, Leicester LE5 4PW, U.K.

hernia repair 6 years later. Bilateral exploration and vasography revealed both vas deferens to be obstructed in the inguinal canal. More seriously, a long segment of the left vas deferens was missing. The right vas stricture was repaired. Testicular biopsy showed normal spermatogenesis.

*Patient 3*

Referral in this 30-year-old man was due to a 3-year history of infertility. He was azoospermic with bilateral inguinal scars from neonatal herniotomy. Exploration and vasography demonstrated the left vas deferens to be obstructed in the superficial ring, whereas no vas deferens could be identified in the right inguinal canal. A left vasovasostomy was undertaken. Testicular histology showed normal spermatogenesis on the left side with germ cell aplasia on the right.

*Patient 4*

Azoospermia in this 30-year-old man was the result of congenital hypoplasia of the left testis with an obstructed right vas deferens stemming from a childhood herniotomy. Exploration confirmed that blockage of the vas deferens was at the site of previous surgery. Biopsy of the right testis demonstrated normal spermatogenesis. He underwent right vasovasostomy.

**Discussion**

Thirty per cent of paediatric surgical practice relates to surgical procedures in the inguinal region (Janik & Shandling, 1982). This is usually unilateral. Any damage to the vas deferens may therefore be masked by a normal contralateral testis and vas deferens. In three of the patients described there was obvious damage to the vas deferens at surgical exploration. For Case 1, however, vasogram and testicular biopsies were normal, and yet he was azoospermic. This observation has been reported previously by Jequier (1985) in three patients who were azoospermic after previous herniotomy or trauma. There may therefore be more subtle changes to function of the vas deferens after surgical exploration than just direct injury. Certainly, previous animal experiments have demonstrated the vulnerability of the immature vas deferens to over-zealous techniques (Shandling & Janik, 1981; Janik & Shandling, 1982; Sandhu *et al.*, 1989; Sandhu & Osborn, 1991). Damage to the specialized pseudocilia, the muscle layer and its autonomic and peptidergic innervation have been described previously (Sandhu *et al.*, 1990). The role of antisperm antibodies in fertility has been highlighted recently by Hendry *et al.* (1990). There is still some debate, however, about the importance of antisperm antibodies. In men with autoimmunity to spermatozoa, spontaneous pregnancy rates can approach those expected for couples with idiopathic infertility (Ayvaliotis *et al.*, 1985). Others have stated that vasectomy reversal with associated anti-sperm antibodies leads to a delay in conception, but not to a significant reduction in conception rates (Fuchs, 1990). Furthermore, the potential role of antibodies after inguinal surgery is uncertain (Phadke & Padukone, 1964; Linnet, 1983; Parkhouse & Hendry, 1991).

These clinical cases, combined with the animal experiments, highlight the care needed during inguinal surgery. This is particularly so in patients undergoing